

CASE REPORT

Challenges of “Reverse” Aortic Arch Debranching for Repair of the Ascending Aorta by Thoracic Endovascular Aortic Repair

V. Kansal^a, A. Hadziomerovic^{b,d}, S. Nagpal^{c,d,*}

^a University of Ottawa, Faculty of Medicine, Canada

^b University of Ottawa, Division of Interventional Radiology, Canada

^c University of Ottawa, Division of Vascular Surgery, Canada

^d Ottawa Hospital Research Institute, Canada

Introduction: Ascending aortic pathology presents a unique challenge for treatment by thoracic endovascular aortic repair (TEVAR), because of lack of adequate endograft landing zones. This report describes a unique “reverse” extra-anatomical aortic arch debranching procedure performed to enable TEVAR of the ascending aorta.

Report: A 71-year-old male presented with a large ascending aortic pseudoaneurysm secondary to previous arch repair anastomosis. This pathology was treated by TEVAR of the ascending aorta. To create a sufficient landing zone for the endovascular stent graft, a “reverse” extra-anatomical aortic arch debranching procedure was performed. This involved a left subclavian artery to left carotid artery bypass, left to right carotid-to-carotid bypass, ligation of proximal left common carotid artery, and embolization of the innominate artery origin.

Discussion: TEVAR of the ascending aorta can be made feasible through a novel debranching procedure that creates sufficient landing zones for the endograft. This surgical approach may prove useful in patients who present with aortic arch pathology and comorbidities that prevent open surgical repair.

© 2016 The Authors. Published by Elsevier Ltd on behalf of European Society for Vascular Surgery. This is an open access article under the CC BY-NC-ND license (<http://creativecommons.org/licenses/by-nc-nd/4.0/>).

Article history: Received 11 May 2016, Revised 27 June 2016, Accepted 28 June 2016,

Keywords: Aortic arch aneurysm, Debranching procedure, Pseudoaneurysm, TEVAR, Thoracic endovascular aortic repair

INTRODUCTION

Thoracic endovascular aortic repair (TEVAR) has markedly impacted the treatment algorithm for patients presenting with vascular pathology of the thoracic aorta. The success of TEVAR is well demonstrated in the repair of pathologies of the descending aorta.¹ More recently, this endovascular repair has been employed in treatment of non-operative high-risk patients.²

TEVAR in the treatment of ascending aortic pathologies has not been well demonstrated; open repair remains the current standard of treatment. The ascending aorta presents unique anatomic challenges for existing endograft devices. The distance between the coronary ostia and the brachiocephalic artery is usually quite short, representing an insufficient landing zone for endograft deployment. The present case describes a novel “reverse” extra-anatomic debranching procedure comprising a left subclavian artery to left carotid artery bypass, left to right carotid-to-carotid

bypass, ligation of proximal left common carotid artery, and embolization of the innominate artery origin to create an adequate landing zone for TEVAR.

REPORT

A 71-year-old male presented with a complex past history revealing a Stanford Type A aortic dissection repair 20 years previously with an isolated ascending aortic arch graft. He also underwent an aortobifemoral bypass graft for aneurysmal disease of the abdominal aorta in the remote past. Both femoral anastomoses subsequently developed aneurysmal degeneration requiring interposition graft repair. Both iliac limbs developed fluid around the limbs, but because of significant cardiac issues it was decided to treat these conservatively with chronic antibiotic therapy.

He was subsequently admitted with chest pain, a CT scan revealed a large dilatation of the distal ascending aortic arch consistent with a pseudoaneurysm from a previous anastomosis (Fig. 1). The extra aortic component measured 5.6 cm in anteroposterior diameter and 6.4 cm in length. The pseudoaneurysm appeared to erode into the posterior wall of the sternum.

This patient was unlikely to survive redo open ascending arch repair because of his cardiac morbidity and severe chronic obstructive pulmonary disease (COPD). There were

* Corresponding author. The Ottawa Hospital Civic Campus, 1053 Carling Avenue, Room A280, Ottawa, ON, K1Y 4E9, Canada.

E-mail address: snagpal@toh.on.ca (S. Nagpal).

2405-6553/© 2016 The Authors. Published by Elsevier Ltd on behalf of European Society for Vascular Surgery. This is an open access article under the CC BY-NC-ND license (<http://creativecommons.org/licenses/by-nc-nd/4.0/>).

<http://dx.doi.org/10.1016/j.ejvssr.2016.06.002>

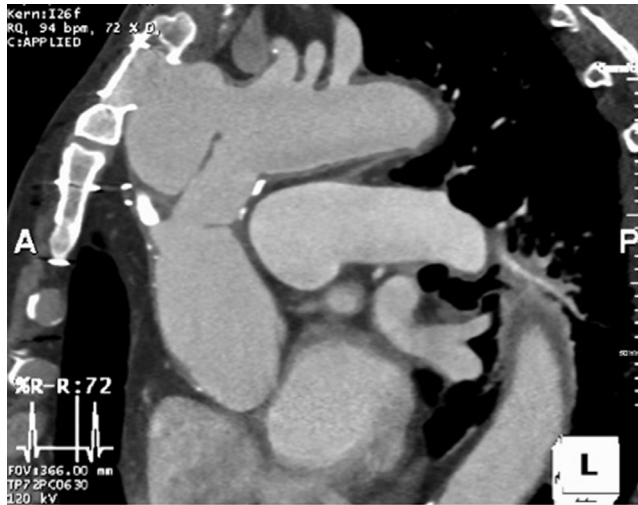

Figure 1. Pre-operative contrast-enhanced CT scan of the ascending aortic pseudoaneurysm.

multiple challenges to fix this by endovascular repair. The pseudoaneurysm started immediately proximal to the innominate artery, indicating that a sealing zone would require coverage of both the innominate artery and the left common carotid artery with its take off just 2 mm from the innominate artery. Furthermore, the thoracic stent would need to be short enough to lie distal to the coronary sinus and proximal to the left subclavian artery. This distance was measured to be 100 mm. The aorta above the aortic valve measured 36 mm while the distal landing zone at the left subclavian was only 25 mm in diameter, indicating that a tapered graft would be preferred. The relationship of the pseudoaneurysm to the great vessels and coronary ostia is illustrated in [Fig. 2](#).

A “reverse” arch debranching procedure was performed comprising: 1) left subclavian artery to left carotid artery bypass; 2) left to right carotid to carotid bypass; and 3) left common carotid artery ligation ([Fig. 3](#)). Bypasses were performed using 8 mm Gore propten graft material. There were no intra-operative complications. Recovery was delayed secondary to respiratory issues.

Two weeks later, TEVAR for the ascending aortic pseudoaneurysm was attempted using a Cook Zenith stent graft system (40 mm × 40 mm × 80 mm, catheter length 75 cm) (Cook Vascular Inc., Bloomington, IN, USA). The endograft was delivered via the proximal left superficial femoral artery.

Unfortunately, the TX2 Cook stent graft delivery system was not long enough to pass the graft to the desired landing zone in the proximal ascending aorta. Higher femoral cut-down either by groin incision or retroperitoneal incision was considered, however, there was concern about infection of the fluid collections surrounding the aortobifemoral graft ([Fig. 4](#)). As a consequence, this procedure was terminated.

Three days later, TEVAR was successfully reattempted using a Medtronic Valiant stent graft (40 mm × 40 mm × 100 mm, catheter length 85 cm) (Medtronic, Dublin, Ireland). This was

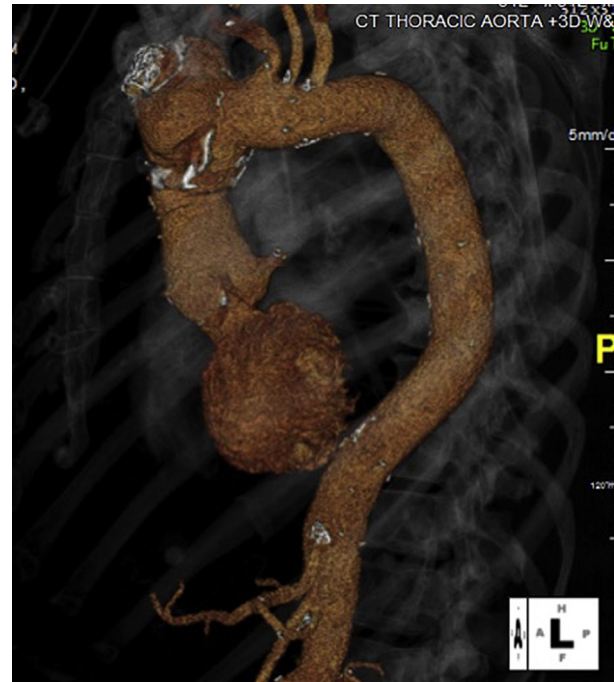

Figure 2. 3D reconstruction of contrast-enhanced CT illustrating the relationship of the ascending aortic aneurysm to the great vessels and coronary ostia.

delivered via the right limb of the patient’s aortobifemoral bypass graft underneath the inguinal ligament. The Medtronic delivery system reached the desired landing zone in the ascending aorta. The graft was deployed with the proximal

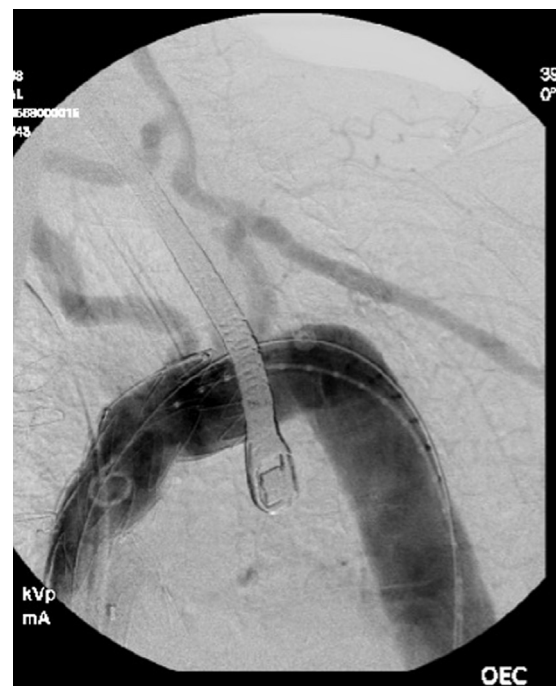


Figure 3. Angiogram demonstrating unique “reverse” debranching of the aortic arch with left subclavian artery to left carotid artery bypass, and left to right carotid to carotid bypass. There is retrograde flow in the innominate artery.

Download English Version:

<https://daneshyari.com/en/article/2911462>

Download Persian Version:

<https://daneshyari.com/article/2911462>

[Daneshyari.com](https://daneshyari.com)