

CASE REPORT

## Endovascular therapy with intravascular ultrasound guidance for popliteal artery occlusion due to blunt trauma

Makoto Utsunomiya <sup>a,\*</sup>, Yoshihiro Takami <sup>a</sup>, Koichi Kusunose <sup>a</sup>, Ken Hayashi <sup>a</sup>, Sachiyo Osawa <sup>a</sup>, Kumiko Chuman <sup>a</sup>, Ryohei Matsuo <sup>b</sup>, Masato Nakamura <sup>c</sup>

<sup>a</sup>Advanced Wound Healing Center, Tokyo Rosai Hospital, Japan

<sup>b</sup>Department of Orthopedic Surgery, Tokyo Rosai Hospital, Japan

<sup>c</sup>Division of Cardiovascular Medicine, Toho University Ohashi Medical Center, Japan

**Background:** Historically, popliteal artery occlusion due to blunt trauma has led to high amputation rate and been thought that indication for traditional open operative repair in almost all of cases.

**Case:** A healthy male in his 30s transferred to the advanced wound care center at our hospital because unhealed wound and popliteal artery occlusion due to blunt trauma after traffic accident. Surgical repair was planned, but was postponed due to wound contamination. Endovascular therapy was selected and balloon angioplasty was performed with intravascular ultrasound (IVUS) guidance successfully. Thereafter wound management, wounds were successfully cured at 3 months after admission.

**Conclusion:** Popliteal artery occlusion due to blunt trauma resulted in lower leg necrosis and successful lower leg preservation was achieved by EVT with using IVUS

© 2015 The Authors. Published by Elsevier Ltd on behalf of European Society for Vascular Surgery. This is an open access article under the CC BY-NC-ND license (<http://creativecommons.org/licenses/by-nc-nd/4.0/>).

Article history: Received 23 April 2015, Revised 7 May 2015, Accepted 8 May 2015,

**Keywords:** Endovascular therapy, Popliteal artery occlusion, Trauma

### INTRODUCTION

Blunt lower extremity injury including popliteal artery are emergent situation and associated with a high rate of limb loss.<sup>1,2</sup> Revascularizations are necessary for limb salvage, and almost all of such cases have been repaired through traditional surgical repair historically. There are only few case reports of endovascular therapy (EVT) for blunt popliteal artery injuries.<sup>3,4</sup> We present a case of popliteal artery occlusion due to blunt trauma; EVT was successfully performed with IVUS guidance and achieved limb salvage.

### CASE REPORT

A healthy male in his 30s was driving a flat-front 1-t truck and crashed the front into an obstacle. His left knee was tightly wedged between his seat and the dashboard, preventing him from being moved for at least 40 min. He was sent to an emergency room with compartment syndrome and an urgent fasciotomy had to be performed. A complex fracture was seen at the proximal end of the tibia with a diagnosis of complication of arterial injury. Urgent surgical

repair was planned, but was postponed due to wound contamination. Subsequent conservative treatment continued without revascularization; however the fasciotomy failed to heal the wound and new ulcers developed at the heel and the dorsum due to compression by casting. Casting was discontinued and several external fixation pins were placed to prevent foot drop. Major amputation was considered to be inevitable, but the patient wanted to avoid it and was therefore transferred to the advanced wound care center at our hospital (Fig. 1). Thirty days had elapsed since the accident.

At admission, the wound from the fasciotomy on the outer side of the lower right leg was open with a large amount of necrosed tissue and the bone and tendon were partially exposed. Sensory and motor neurons were damaged as well. Because the lower leg was infected, EVT was selected rather than surgical bypass.

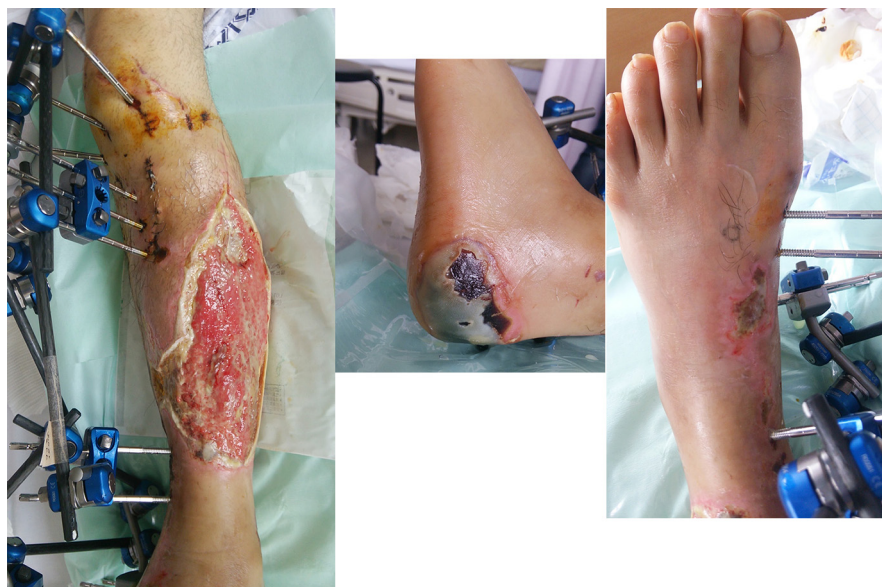A long 4.5 french sheath (Parent; Medikit Japan) were inserted to ipsi-lateral femoral artery antegradely, and control angiography revealed that distal popliteal artery was occluded and proximal site of antero-tibial artery, postero-tibial artery and peroneal artery were patent filled by collateral perfusion (Fig. 2). At first, we attempted antegrade wiring by using soft wire (Joker PV; Japan lifeline, Japan), however it could not cross the occlusion site because lesion were consisted of hard fibrous tissue. With adjunctive use of a 2.6 french microcatheter (CXI, Cook) for increased back up support and a exchange to more stiff

\* Corresponding author. Tokyo Rosai Hospital, Advanced Wound Healing Center, 4-13-21, Ohmori-Minami, Ohta-ku, Tokyo, 143-0013, Japan. Tel.: +81 3 3742 7301.

E-mail address: [m.utsu0705@gmail.com](mailto:m.utsu0705@gmail.com) (M. Utsunomiya).

2405-6553/© 2015 The Authors. Published by Elsevier Ltd on behalf of European Society for Vascular Surgery. This is an open access article under the CC BY-NC-ND license (<http://creativecommons.org/licenses/by-nc-nd/4.0/>).

<http://dx.doi.org/10.1016/j.ejvssr.2015.05.003>



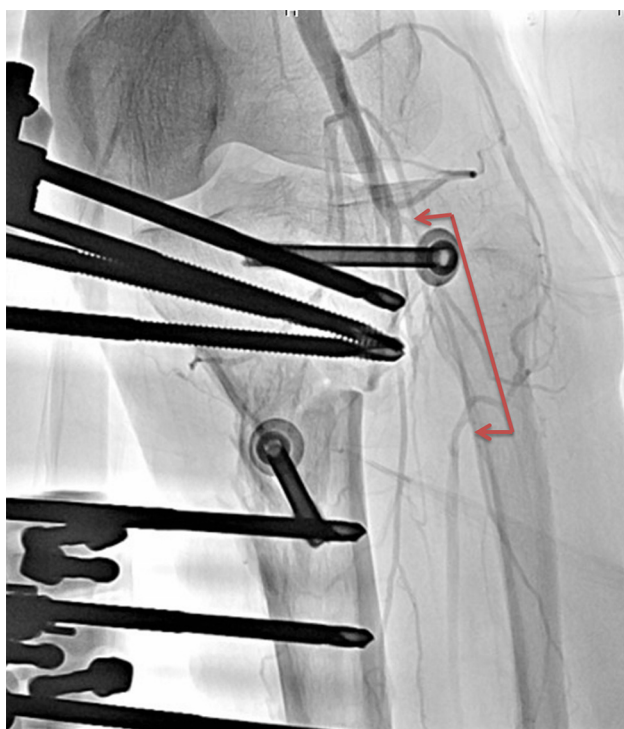
**Figure 1.** The wound of the right lower limb at admission. The wound caused by the fasciotomy on the outer side of the lower leg was open with a large amount of necrosed tissue and the bone and tendon were partially exposed. Ulcers also developed at the heel and the dorsum due to compression by casting and casting was discontinued and several external fixation pins were placed to prevent foot drop.

penetration wire (Wizard 3, Japan lifeline, Japan), the lesion was crossed. IVUS findings revealed proximal occlusion site of the peroneal artery with a smaller diameter and suggested negative remodeling. The vessel wall showed complete loss of triple-layer structure of vessels overlapping with the fractured area of the tibio-peroneal trunk (Fig. 3). Because the tissue was likely to be very fragile, angiography was performed with the IVUS catheter placement, which

revealed extravascular leakage of contrast medium as a result of IVUS catheter passage alone. This confirmed extreme fragility of the tissues at the affected site. Because balloon inflation had a very high risk of bleeding from the damaged vessel, we started with a small balloon, 1.5 mm in diameter (Coyote, Boston Scientific Japan), and gradually increased the diameter while confirming the absence of bleeding. Eventually, a 4-mm balloon (Coyote, Boston Scientific Japan) was used for inflation in the tibio-peroneal trunk and a 3-mm balloon (Ultraverse, Bard) was used for inflation in the peroneal artery as well as postero-tibial artery to achieve good revascularization in the leg (Fig. 4).

As a postoperative subjective symptom, the entire lower leg felt warm. Debridement was performed in the necrosed area, where bleeding and subsequent good granulation were obtained. On angiography performed 1 week post-EVT to confirm the opening of the treated sites, the inflated vessels were open without delayed blood flow and the distal vessels were larger in diameter than the pre-operative state, likely attributable to reduced vascular spasm due to tissue damage and proximal vessel blockage.

Thereafter, debridement, negative pressure wound therapy and epidermization were administered to all wounds and they were successfully cured at 3 months after the patient was transferred to our hospital (Fig. 5). Sensory abnormality was improved with a certain level of perception, however complete recovery was not obtained. Similarly motor impairment was improved. The affected leg was movable, except some toes, and the patient was discharged in ambulatory status with a walking stick.



**Figure 2.** Diagnostic angiogram showing occlusion of the popliteal artery.

## DISCUSSION

Popliteal artery occlusion due to blunt trauma is associated with a high risk of amputation. Amputation is said to be

Download English Version:

<https://daneshyari.com/en/article/2911480>

Download Persian Version:

<https://daneshyari.com/article/2911480>

[Daneshyari.com](https://daneshyari.com)