

'EVIDENCE DRIVEN' CLINICAL SCENARIO

Is Inferior Mesenteric Artery Embolization Indicated Prior to Endovascular Repair of Abdominal Aortic Aneurysm?

F. Biancari^{a,*}, J. Mäkelä^a, T. Juvonen^a, M. Venermo^b

^a Department of Surgery, Oulu University Hospital, Oulu, Finland

^b Department of Vascular Surgery, Helsinki University Hospital, Helsinki, Finland

CLINICAL VIGNETTE

A 67 year old man presents with a growing infrarenal abdominal aortic aneurysm. He has been a heavy smoker, has a history of myocardial infarction 2 years ago, and suffers from moderate renal impairment. The pre-operative CT angiogram reveals a favorable anatomy for EVAR but shows a relatively large and patent inferior mesenteric artery. Should I coil this artery during or before EVAR?

Type II endoleak is a common condition occurring after endovascular repair of abdominal aortic aneurysms (EVAR), and may result in aneurysm sac growth and/or rupture in a small number of patients. A prophylactic strategy of inferior mesenteric artery (IMA) embolization before EVAR has been advocated, however, the benefits of this strategy are controversial. A clinical vignette allows the authors to summarize the available data about this issue and discuss the possible benefits and risks of prophylactic IMA embolization before EVAR. The authors performed a meta-analysis of available data which showed that the pooled rate of type II endoleak after IMA embolization was 19.9% (95% CI 3.4–34.7%, I^2 93%) whereas it was 41.4% (95% CI 30.4–52.3%, I^2 76%) in patients without IMA embolization (5 studies including 596 patients: $p < .0001$, OR 0.369, 95% CI 0.22–0.61, I^2 27%). Since treatment for type II endoleaks is needed in less than 20% of cases and this complication can be treated successfully in 60–70% of cases resulting in an aneurysm rupture risk of 0.9%, these data indicate that embolization of patent IMA may be of no benefit in patients undergoing EVAR.

© 2015 European Society for Vascular Surgery. Published by Elsevier Ltd. All rights reserved.

Article history: Received 22 February 2015, Accepted 20 June 2015, Available online 28 August 2015

Keywords: Abdominal aortic aneurysm, Embolization, Endoleak, Endovascular, EVAR, Inferior mesenteric artery

Type II endoleak is a common condition occurring after endovascular repair of abdominal aortic aneurysms (EVAR). It is the result of retrograde blood flow into the aneurysm sac from patent aortic vessels such as the inferior mesenteric artery (IMA), the lumbar arteries, and the median sacral artery through collateral circulation.^{1–3} A patent IMA is considered a major source of type II endoleak.^{1,4} The number of additional patent aortic branches is also associated with an increased risk of such endoleaks.^{1,5}

Type II endoleak is considered the least severe type of endoleak occurring after EVAR. Still, in a small number of patients, type II endoleak may result in aneurysm sac

growth and/or rupture. Since the treatment of this endoleak is sometimes technically difficult with suboptimal results,^{6,7} a prophylactic strategy of IMA embolization before EVAR has been advocated.

The incidence of type II endoleak detected at computed tomography after EVAR ranges from 3% to 25%,^{8–10} and it is likely to be higher when magnetic resonance imaging is used.¹¹ Between 50% and 80%^{12,13} of such leaks resolve spontaneously within the first 6 months of the operation and no treatment is indicated. However, a minority of type II endoleaks persist or others may appear later on, and this may cause concern regarding their impact on the fate of the aneurysm sac.⁴

PROGNOSTIC IMPACT OF TYPE II ENDOLEAK

Studies regarding the significance of type II endoleak have shown contradictory results. Some studies have shown that type II endoleaks are associated with a benign course.^{14,15} However, most studies are in agreement that type II

* Corresponding author.

E-mail address: faustobiancari@yahoo.it (F. Biancari).

1078-5884/© 2015 European Society for Vascular Surgery. Published by Elsevier Ltd. All rights reserved.

<http://dx.doi.org/10.1016/j.ejvs.2015.06.116>

endoleak may result in persistently elevated intra-sac pressure and failure of aneurysm sac shrinkage.¹⁵ A few studies concluded that persistent type II endoleak is associated with adverse outcomes such as aneurysm sac growth and rupture and therefore requires re-intervention.^{4,12}

In a recent meta-analysis of 32 studies including 21,744 patients, type II endoleak after EVAR was detected in 10.2% of patients.⁸ About 35% of these endoleaks resolved spontaneously. Three hundred and ninety three (26%) interventions for type II endoleak were performed with a success rate of 71.5%. Fourteen patients (0.9%) with isolated type II endoleak had ruptured abdominal aortic aneurysm, six of them without any sign of aneurysm sac growth. Another meta-analysis¹⁶ was not able to define a threshold for treatment of type II endoleak as the aggressive treatment of type II endoleak not associated with sac expansion did not provide better results than a more conservative strategy (intervention only in cases of type II endoleak with sac expansion > 5 mm or persistent type II endoleak for > 12 months). No aneurysm rupture occurred in this pooled series. However, type II endoleak associated with an aneurysm sac growth ≥ 10 mm is considered an indication for endovascular, laparoscopic or open repair.¹⁷

IMPACT OF INFERIOR MESENTERIC EMBOLIZATION PRIOR TO EVAR IN PREVENTING TYPE II ENDOLEAK

Although EVAR has been performed for almost three decades, there are only five studies adequately comparing the outcome of IMA embolization with a conservative strategy.^{18–22} The results of these series have been pooled here using the random effects method. Statistical analysis was performed using Open meta-analysis statistical software (http://www.cebm.brown.edu/open_meta). These five studies reported on 246 patients who underwent IMA embolization with or without embolization of patent lumbar arteries and their outcome was compared with that of 350 patients with patent IMA and who did not undergo prophylactic embolization of the aortic branches. Two studies performed IMA embolization with Amplazer^{19,20} and the others by coiling.^{18,21,22} In a few cases, embolization of lumbar arteries was performed as well. The embolization procedure had a success rate of 98.4% (95% CI 96.3–100%). The rate of type II endoleak after IMA embolization was 19.9% (95% CI 3.4–34.7%, I^2 93%) whereas it was 41.4% (95% CI 30.4–52.3%, I^2 76%) in patients without IMA

embolization ($p < .0001$, OR 0.369, 95% CI 0.222–0.613, I^2 27%) (Fig. 1). Lumbar arteries were responsible for type II endoleak in a few patients.¹⁸ Four studies^{18–20,22} reported on the number of patients who required re-intervention for type II endoleak and this was significantly lower after IMA embolization (1.2% vs. 13.4%, $p < .0001$, OR 0.091, 95% CI 0.027–0.301, I^2 0%). However, the threshold for intervention varied significantly between studies. Two studies reported on aneurysm related mortality, which was nil in both.^{21,22} One patient developed mesenteric ischemia after IMA embolization and died.²² No homogeneous data were reported on the rate of growth of the aneurysm sac in these studies. In one study,²¹ the overall linearized aneurysm shrinkage rate was 1.4 ± 3.8 mm per year in the IMA embolization group and 1.7 ± 2.4 mm per year in the control group ($p < .72$).

DIAMETER OF THE INFERIOR MESENTERIC ARTERY AND OCCURRENCE OF TYPE II ENDOLEAK

The impact of the size of IMA on the occurrence of type II endoleak is a matter of intense debate. Fukuda et al.¹⁰ observed that the diameter of the proximal IMA was larger than 2.5 mm in 24% (26/106) of patients without type II endoleak, in 50% of those with transient endoleak (5/10), and 100% (5/5) in patients with persistent endoleak. In multivariate analysis, the absence of stenosis of the IMA at its orifice was more likely to be a significant factor of persistent type II endoleak ($p = .0003$), and thrombus at the orifice of the IMA was a negative predictor of persistent type II endoleak ($p = 0.043$).¹⁰ Otsu and colleagues⁵ confirmed these findings and showed that an IMA diameter > 2.5 mm along with each additional patent lumbar artery ≥ 1.9 mm were predictors of permanent type II endoleak. Similarly, Müller-Wille and colleagues²³ observed that patients without complex IMA and lumbar artery type II endoleak in whom the largest feeding and/or draining artery was larger than 3.8 mm, and patients with a complex IMA type II endoleak in whom the largest feeding and/or draining artery was larger than 2.2 mm were at high risk for aneurysm sac enlargement.

Another study showed the significant association between the diameter of the IMA and the occurrence of type II endoleak.²⁴ However, multivariate analysis showed that the number and diameter of patent lumbar arteries were the only predictors of permanent type II endoleak requiring

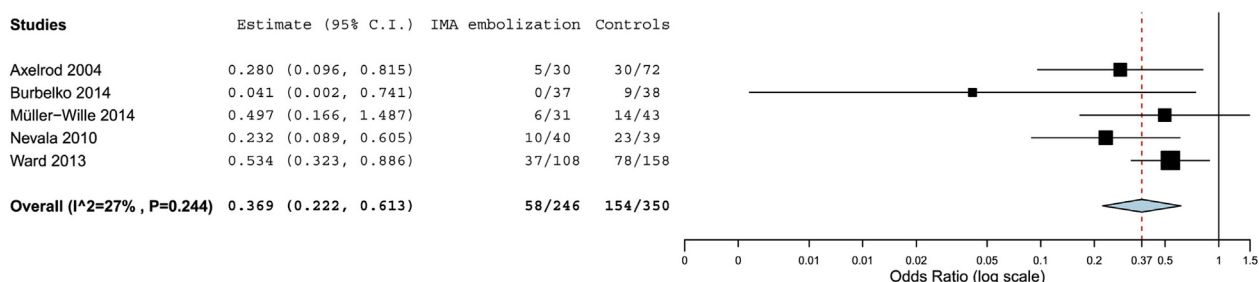


Figure 1. Forest plot showing the impact of pre-operative inferior mesenteric artery (IMA) embolization versus conservative treatment on the development of type II endoleak in patients with patent IMA undergoing endovascular repair of abdominal aortic aneurysm.

Download English Version:

<https://daneshyari.com/en/article/2911804>

Download Persian Version:

<https://daneshyari.com/article/2911804>

[Daneshyari.com](https://daneshyari.com)