

Anatomical Study of the Gastrocnemius Venous Network and Proposal for a Classification of the Veins

J.A. Aragão,¹ F.P. Reis,¹ G.B.B. Pitta,² F. Miranda Jr² and L.F. Poli de Figueiredo^{2*}

Departments of ¹Anatomy, Tiradentes University, Sergipe, and ²Surgery, Federal University of São Paulo, São Paulo, Brazil

Objectives. To present a detailed description of the gastrocnemius venous network.

Design. Anatomical study in cadavers.

Material and methods. Forty lower limbs from 20 adult male cadavers were studied. All gastrocnemius veins were dissected from the gastrocnemius muscle heads proximally toward their drainage site.

Results. Eighty heads of 40 gastrocnemius muscles showed 438 gastrocnemius veins. The number of veins per muscle head varied between 2 and 12. There were 221 gastrocnemius trunks distributed as 95 main gastrocnemius trunks, 81 axial and 45 collateral ones. From the 95 main gastrocnemius trunks, 83 (87%) drained into the popliteal vein. Direct observation of the gastrocnemius venous network allowed us to classify the anatomical distribution as four distinct types.

Conclusions. The majority of main gastrocnemius venous trunks drain into the popliteal vein. There is wide variability in the number of gastrocnemius veins. We propose a classification of four distinct types of anatomical pattern.

Keywords: Calf veins; Deep venous thrombosis; Gastrocnemius veins; Gastrocnemius muscle; Venous anatomy.

Introduction

Gastrocnemius veins may be the starting point of some episodes of deep vein thrombosis and incompetence of these veins may lead to chronic venous insufficiency. However, the anatomical arrangement of these veins has been largely ignored by both classical anatomical textbooks and contemporary vascular literature.^{1–8} A complete description of the gastrocnemius venous network is important to provide support for non-invasive investigations such as duplex scanning where it is desirable to have knowledge of the normal patterns of these vessels. No anatomical or radiological study has been published which describes in detail the distribution, number and drainage of the gastrocnemius veins. Our objective was to characterise the anatomical distribution of the gastrocnemius veins. We hope to provide a better understanding of the pathophysiology of deep venous thrombosis and an useful guide for clinicians performing duplex ultrasound examination as well as surgeons operating on

patients with recurrent varicose veins or chronic venous insufficiency.^{9–13}

Material and Methods

Our study was approved by the Ethics Committee of the Federal University of São Paulo. It was performed in 40 lower limbs from 20 adult male cadavers, with an estimated age between 40 and 60 years old, fixed and maintained in 10% formaldehyde solution. These cadavers showed no macroscopic evidence of disease of the lower extremity such as fractures, ulcers, ischaemic lesions, oedema or varicose veins.

Circumferential lines were drawn 10 cm above the patella and 10 cm below the tibial tuberosity. Then a posterior longitudinal line was drawn in the midline between the circumferential lines. Incisions were made over those lines and the skin flaps were made laterally and medially. Dissection was performed in layers, preserving the small saphenous vein. The popliteal fossa was carefully dissected, identifying the neural and vascular elements, the ischiatic nerve and its division into tibial and peroneal nerves. Ischiatic nerve branches were dissected and the heads of the gastrocnemius muscle were identified. All gastrocnemius veins were dissected from the gastrocnemius

*Corresponding author: Luiz F. Poli de Figueiredo, MD, Department of Surgery, Federal University of São Paulo, Rua Oscar Freire, 1546 Apt. 203, CEP 05409-010 São Paulo, SP, Brazil.
E-mail address: lpoli@uol.com.br

muscle heads toward their drainage site. The main gastrocnemius venous trunks were opened longitudinally to allow assessment of the presence and number of valves. We considered measurement of the diameter of these veins but consider that due to the likely post-mortem changes in the veins including those attributable to preservation of the cadavers in formalin solution, such data would have no direct correspondence with those made in life. We have, therefore, omitted mention of vein dimensions in this article.

Results

Eighty heads of 40 gastrocnemius muscles showed 438 gastrocnemius veins. The number of veins per muscle head varied between 2 and 12, with a mode of 4 and 5, a mean of 4.6. There were 221 gastrocnemius trunks distributed as 95 main gastrocnemius trunks (final drainage from the muscle), 81 axial and 45 collateral ones. The length of the trunks varied between 0.5 and 5.5 cm, with a mean length of 2.3, SD 1.24 cm and a mode of 1.7. From the 95 main gastrocnemius trunks, 83 (87%) drained into the popliteal vein and the remaining 12 (13%) drained into the posterior tibial vein, peroneal vein and tibio-peroneal truncal vein. Gastrocnemius veins draining into the small saphenous vein was observed in one leg, as shown in Fig. 2, type 4.

The direct observation of the gastrocnemius venous network allowed us to describe a characteristic anatomical distribution, which were classified in four distinct types as follows (Figs. 1 and 2):

- Type 1 Characterised by veins emerging from the lateral and medial heads of gastrocnemius muscle, converging to an axial venous trunk, which continued proximally toward the main gastrocnemius trunk.
- Type 2 Characterised by veins emerging from the lateral and medial heads of gastrocnemius muscle but draining into collateral trunks, converging to an axial venous trunk and then toward the main gastrocnemius trunk.
- Type 3 Characterised by veins emerging from the lateral and medial heads of gastrocnemius muscle, converging directly toward the main gastrocnemius trunk.
- Type 4 Characterised by veins emerging from the lateral and medial heads of gastrocnemius muscle with no conversion to any of the gastrocnemius trunks. The most common types were 1 and 2, as shown in Table 1.

We observed 65 valves in the main gastrocnemius trunks, 48 of them located in the proximal segment, 11

in the intermediate and six at the distal segment. Valves were detected in all muscle heads in venous network types 1, 2 and 3. Since, type 4 implies that there was no main gastrocnemius trunk, no valves were detected. The majority of main gastrocnemius trunks contained only one valve.

In type 1 networks, there were 44 main gastrocnemius venous trunks, 22 in the medial and 22 in the lateral muscle head, with 35 valves; in 14 trunks (32%) no valve was detected. In type 2, there were 37 main trunks, 21 in the medial and 16 in the lateral muscle head, with 37 valves; in 14 trunks (38%) there was no valve. In type 3, there were 14 main gastrocnemius trunks, eight in the medial and six in the lateral muscle head, with seven valves; in seven trunks (50%), no valve was detected.

Discussion

Our study shows that number of the gastrocnemius veins varies from 2 to 12 per muscle head. Our findings contrast with many reports in which the

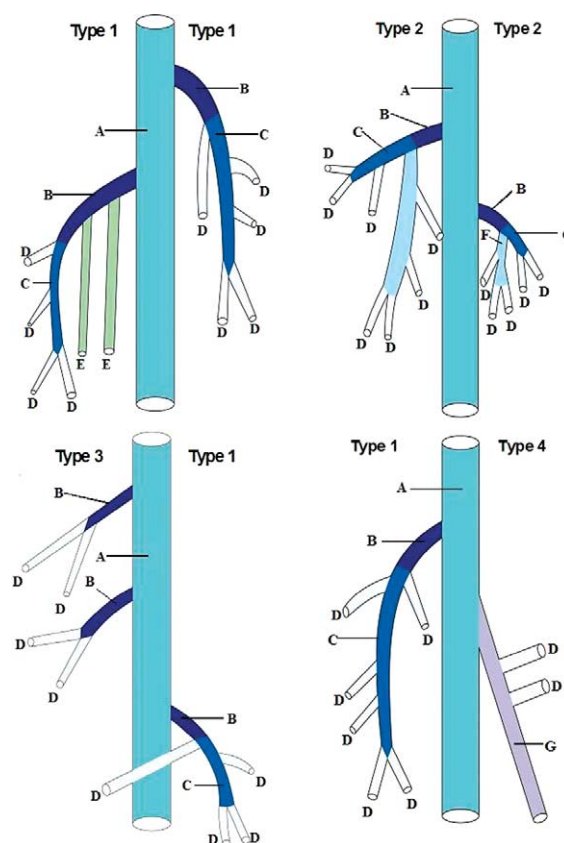


Fig. 1. Diagram showing the distribution of gastrocnemius venous network types 1, 2, 3 and 4. A, popliteal vein; B, main gastrocnemius venous trunk; C, axial gastrocnemius venous trunk; D, gastrocnemius veins; E, soleal veins; F, small saphenous vein; G, collateral gastrocnemius venous trunk.

Download English Version:

<https://daneshyari.com/en/article/2915135>

Download Persian Version:

<https://daneshyari.com/article/2915135>

[Daneshyari.com](https://daneshyari.com)