

# Treatment of ventricular fibrillation in a patient with prior diagnosis of long QT syndrome: Importance of precise electrophysiologic diagnosis to successfully ablate the trigger

Komandoor Srivathsan, MD,\* Apoor S. Gami, MD,<sup>†</sup> Michael J. Ackerman, MD, PhD,<sup>‡</sup> Samuel J. Asirvatham, MD<sup>†</sup>

From the \*Division of Cardiovascular Diseases, Department of Medicine, Mayo Clinic, Scottsdale, Arizona, <sup>†</sup>Division of Cardiovascular Diseases, Department of Medicine, Mayo Clinic College of Medicine, Rochester, Minnesota, <sup>‡</sup>Division of Pediatric Cardiology, Department of Pediatrics, Department of Molecular Pharmacology, Mayo Clinic College of Medicine, Rochester, Minnesota

Idiopathic ventricular fibrillation (VF) is generally defined as VF that occurs in the absence of identifiable structural heart disease. It is largely a diagnosis of exclusion that requires a normal electrocardiogram (ECG), echocardiogram, and coronary angiogram.<sup>1</sup> Idiopathic VF is considered the cause of sudden cardiac death (SCD) in 5%–10% of SCD survivors. Mapping and ablation of idiopathic VF has been reported.<sup>2,3</sup> We report an unusual case of idiopathic VF that was cured by ablation of a focal premature ventricular contraction (PVC) in a patient previously diagnosed with long QT syndrome (LQTS).

## Case report

Six months before presenting to our institution, a 39-year-old woman had been resuscitated from SCD. Results of transthoracic echocardiography, ambulatory ECG, exercise treadmill testing, and coronary angiography with coronary endothelial function testing all were normal. She did not have a family history of SCD, and screening ECGs in first-degree relatives did not demonstrate QT-interval prolongation. Because the initial ECG after her resuscitation had shown borderline QT-interval prolongation (QTc = 450 ms), a clinical diagnosis of LQTS was made, and an implantable cardioverter-defibrillator (ICD) was placed. She was treated with propranolol 160 mg daily in divided doses, and amiodarone was initiated because of multiple appropriate ICD shocks. She was referred to our institution because of a 4-month history of recurrent ICD therapies for VF.

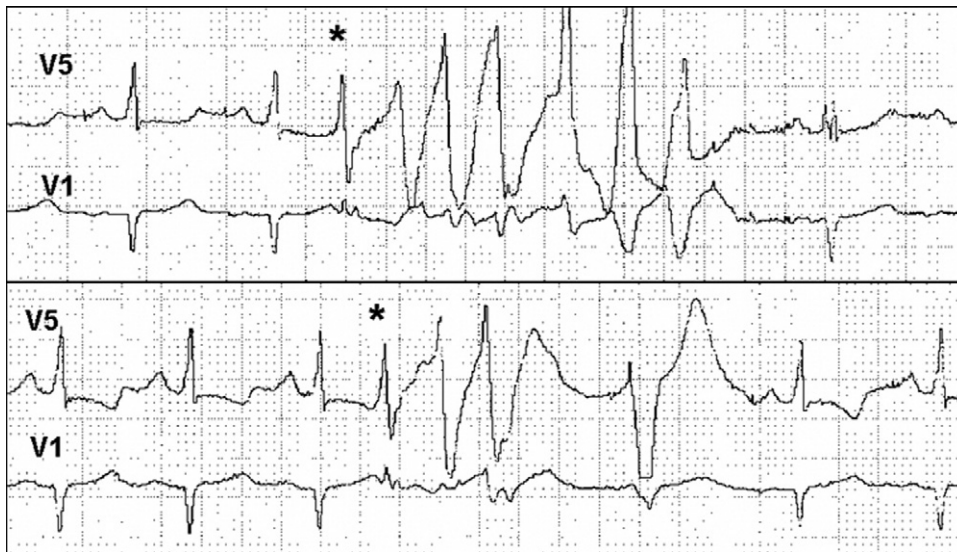
Upon our initial evaluation, interrogation of the ICD revealed 29 VF episodes, 26 aborted shocks, and 3 ICD therapies with 8-J shocks in the preceding 3 months. Mon-

itoring by 24-hour ambulatory ECG showed an average daily heart rate of 70 bpm and no significant abnormality in QT interval or T-wave morphology. Multiple episodes of VF were documented. Each episode of VF was preceded by PVCs of identical morphology and fixed coupling interval (320 ms; Figure 1). The PVCs had a relatively narrow QRS (width 110–120 ms) and normal upstroke, raising the possibility of a fascicular origin.

The patient underwent a comprehensive electrophysiologic study under conscious sedation with and without isoproterenol administration. Bipolar intracardiac electrograms were recorded at a filtered band width of 30–500 Hz. Polymorphic ventricular tachycardia or VF was initiated with a single PVC at a drive train of 300 ms and coupling interval of 340 ms. Multiple spontaneous initiations of VF occurred throughout the study with and without isoproterenol use. VF episodes always occurred after PVCs having an identical morphology to those seen during ambulatory monitoring. These PVCs also occurred repeatedly without initiating VF (Figure 2). Careful mapping of these PVCs was undertaken with both multielectrode catheters and electroanatomic mapping. Electroanatomic mapping was used to generate a map of the earliest ventricular myocardial activation and a map of near-field Purkinje-like potentials (Figure 3).<sup>4</sup> The PVCs responsible for initiating VF had a Purkinje-like potential 30 ms before the initial portion of the QRS complex (Figure 4). Additional high-density mapping located a site where prepotentials occurred 35 ms prior to the QRS complex. Pacing from the site of the earliest prepotential at low output (just sufficient to capture) produced a QRS complex having morphology in all 12 ECG leads similar to the morphology of the PVCs that triggered VF. Furthermore, the time interval from the pacing stimulus to the QRS complex was identical to the time interval from the Purkinje potential to the QRS complex for spontaneous PVCs.<sup>5</sup> Radiofrequency ablation at this site produced a flurry of monomorphic PVCs similar to the PVCs that initiated VF. The PVCs terminated after 6 seconds during a

**KEYWORDS** Ablation; Fascicle; Idiopathic ventricular fibrillation; Premature ventricular contraction (Heart Rhythm 2007;4:1090–1093)

**Address reprint requests and correspondence:** Dr. Samuel J. Asirvatham, Mayo Clinic, 200 First Street SW, Mary Brigh Building 4-523, Mayo Clinic College of Medicine, Rochester, Minnesota 55902. E-mail address: asirvatham.samuel@mayo.edu. (Received January 15, 2007; accepted March 2, 2007.)



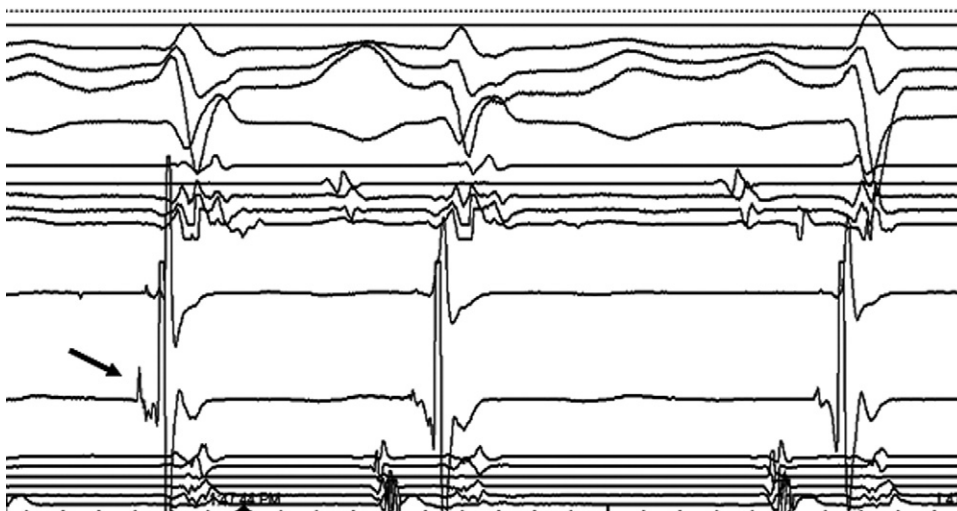**Figure 1** Ambulatory ECG showing two episodes of nonsustained polymorphic ventricular tachycardia preceded by premature ventricular contractions (asterisks) having identical morphology and coupling interval.

63-second energy application of 27 W and electrode temperature of 56°C. Areas immediately adjacent to this site also were ablated (nine energy applications ranging from 30–89 seconds). After ablation was complete, VF was not inducible with triple extrastimulation or ventricular burst pacing with and without isoproterenol use. Amiodarone was discontinued upon release from the hospital.

Six weeks after ablation, ambulatory ECG monitoring demonstrated a marked reduction in the frequency of PVCs (from >4,000/day preablation to <100/day and no episodes of ventricular tachycardia). Several subsequent ECGs continued to show a rate-corrected QT interval in the normal range. Sixteen months after ablation, the patient has remained free of ICD therapies, and ICD interrogation has not shown recurrent episodes of nonsustained VF.

## Discussion

The primary mechanisms of SCD are VF and polymorphic ventricular tachycardia. These arrhythmias may occur in the absence of structural heart disease. In the patient described in this report, the lack of abnormality on ECG, echocardiogram, coronary angiogram, and coronary endothelial function study raised the probability of idiopathic VF. The patient's sentinel event of resuscitated SCD at age 39 years with documented polymorphic ventricular tachycardia and rate-corrected QT interval of 450 ms resulted in a presumptive diagnosis of LQTS and placement of an ICD. Multiple ECGs, including those recorded during treadmill testing and ambulatory monitoring, showed normal QT intervals; nevertheless, a



**Figure 2** Purkinje potential (arrow) preceding a typical premature ventricular contraction that triggered ventricular fibrillation.

Download English Version:

<https://daneshyari.com/en/article/2924913>

Download Persian Version:

<https://daneshyari.com/article/2924913>

[Daneshyari.com](https://daneshyari.com)