

Swallowing-induced atrial tachycardia arising from superior vena cava: Significant involvement of parasympathetic nerve activity



Koji Higuchi, MD, PhD,^{*} Kenzo Hirao, MD, PhD, FHRS,^{*} Hitoshi Hachiya, MD, PhD,[†] Mitsuaki Isobe, MD, PhD[‡]

From the ^{*}Heart Rhythm Center, Tokyo Medical and Dental University, Tokyo, Japan, [†]Division of Cardiovascular Medicine, Tuchiura Kyodo Hospital, Ibaragi, Japan, and [‡]Division of Cardiovascular Medicine, Tokyo Medical and Dental University, Tokyo, Japan.

Introduction

Swallowing-induced tachyarrhythmia is a rare clinical entity, and is defined as supraventricular tachyarrhythmia, such as atrial premature contractions (APCs), paroxysmal atrial tachycardia (AT), and paroxysmal atrial fibrillation, that is reproducibly and consistently induced during a wet or dry swallow. Although the first case of a swallowing-induced tachyarrhythmia was reported as far back as 1926 by Sakai et al,¹ no more than 50 cases have been described in the worldwide literature, as Tada et al² organized in a report.

In this present report, we describe a case of swallowing-induced AT arising from the superior vena cava (SVC), which is assumed to have considerable association with parasympathetic nerve activity.

Case report

A 36-year-old man suffered from recurrent episodes of palpitation, which occurred several seconds after swallowing solid foods or drinking hot water. APCs and AT during swallowing were documented on electrocardiography and 24-hour Holter monitor. P wave morphology was positive in inferior leads and positive in V1 lead. Since beta-blockers and other antiarrhythmic drugs could not reduce episodes of this tachycardia, he was admitted to our hospital for an electrophysiological study and a catheter ablation. No structural heart disease was recognized in the echocardiogram.

An esophagogram by swallowing contrast media revealed that the esophagus was located relatively leftward and was not adjacent to the right atrium. A decapolar catheter was

placed into the SVC, and 2 decapolar circular catheters (Lasso; Biosense-Webster, Baldwin Park, CA) were placed into the left superior pulmonary vein and the right superior pulmonary vein. **Figure 1** shows the location of these catheters and the intracardiac electrocardiogram of APCs after swallowing hot water. The earliest activation site of sinus rhythm was near SVC4, and this level was at the SVC–right atrium junction. The earliest activation site of APCs after swallowing was SVC1–2, which was above the SVC–right atrium junction.

In this patient, heart rate variability (HRV) during the procedure was evaluated using a real-time HRV analyzing system (MemCalc; GMS Co, Ltd, Tokyo, Japan). This system can eliminate extrasystoles automatically and calculate HRV every 2 seconds. Low-frequency (LF) and high-frequency (HF) components of the patient's heart rate were measured in order to evaluate changes in autonomic tone during the procedure. The HF component, which indicates parasympathetic nerve activity, increased immediately after swallowing, followed by APC induction. On the other hand, the LF/HF ratio, which indicates sympathetic nerve activity, decreased after swallowing (**Figure 2A-1**).

APCs were mapped in the SVC using a 4-mm-tip ablation catheter. The earliest activation site of APCs was the posteroseptal aspect of the SVC and the local activation at the site preceded the onset of the P wave of APCs by 38 ms. APCs recorded from the unipolar lead of the ablation catheter showed a QS pattern at the site (**Figure 3**). Radiofrequency energy was applied at the site during sinus rhythm and the sinus interval was decreased from 760 to 700 ms. After ablation at this site, APCs or AT did not occur even after swallowing.

After successful ablation, LF and HF components of the patient's heart rate were measured again. The HF component was strongly suppressed and did not increase even after swallowing, while the LF/HF ratio was suppressed as before (**Figure 2A-2**).

The HF component in 24-hour Holter monitoring was consistently suppressed significantly at 1 day after ablation

KEYWORDS Swallowing-induced atrial tachycardia; Superior vena cava; Parasympathetic nerve activity
(Heart Rhythm Case Reports 2016;2:306–309)

Address reprints and correspondence: Dr Koji Higuchi, Assistant Professor, Heart Rhythm Center, Tokyo Medical and Dental University, 1-5-45 Yushima Bunkyo-ku, Tokyo, Japan 113-8510. E-mail address: khigu1013@gmail.com.

KEY TEACHING POINTS

- The autonomic nerve system, especially the parasympathetic nerve system, is strongly involved in the cause of swallowing-induced atrial tachyarrhythmia (SIAT).
- Direct contact from the esophagus seems not to have an association with SIAT.
- SIAT can be radically cured by catheter ablation.

compared to preablation 24-hour Holter monitor (Figure 2B-1 and B-2), which means a suppression of parasympathetic nerve activity continued even at 1 day after ablation.

APCs did not occur for 15 months after this procedure.

Discussion

The true mechanism of swallowing-induced AT is still unclear. Direct mechanical interaction between the distended esophagus and the adjacent left atrium was previously suggested.^{3,4} Burton et al⁶ reported a case in which the patient needed intrapleural repositioning of the esophagus for curing swallowing arrhythmia. This suggested the direct mechanical stimulation from the esophagus to the left atrium.

On the other hand, Lindsay⁷ proposed a vagal nerve-mediated neural reflex as the initiating mechanism. In a case report by Morady et al,⁵ an esophageal manometric study demonstrated that the swallowing tachycardia was coincident with relaxation of the upper esophageal sphincter and preceded the peristaltic activity in the esophageal body. They

also described that the most possible mechanism was a vagally mediated neural reflex involving a neurotransmitter other than acetylcholine because atropine and bethanechol did not affect the swallowing-induced AT. Recently, many other reports suggested a neural reflex as the cause of swallowing-induced AT.⁸⁻¹¹

In this case report frequent atrial extrasystoles arising from the SVC were provoked by swallowing. The fact that the SVC was far away from the esophagus suggested that extrasystoles were provoked by neural reflex, not by direct contact from the esophagus. We also found a significant involvement of the autonomic nerve system in this AT from an HRV evaluation during the catheter ablation. The increase of parasympathetic nerve activity with suppression of sympathetic nerve activity were recognized when swallowing-induced AT occurred. The HF component was solely suppressed after ablation with suppression of APCs, suggesting that parasympathetic nerve activity was strongly involved in the cause of this arrhythmia rather than the sympathetic nerve system. Since AT was suppressed by ablation at a single site, not by SVC isolation, the success site might be the end of axons from ganglionated plexi (possibly the SVC-aorta ganglionated plexi), which contained mainly the parasympathetic nerve system, as previously reported.^{10,11}

Conclusion

We experienced a case of swallowing-induced AT arising from the SVC that was cured by catheter ablation. HRV measurement revealed that this AT had a strong involvement of the parasympathetic nerve system as the cause of arrhythmia.

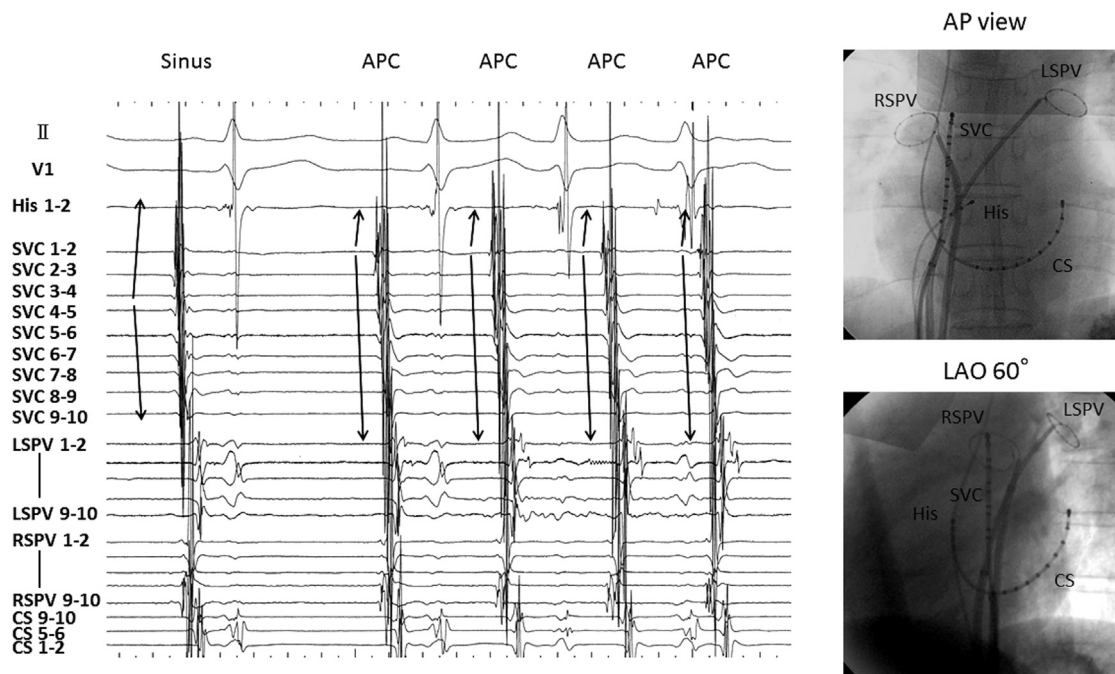


Figure 1 Intracardiac electrocardiogram during sinus rhythm and atrial premature contractions (APCs) after swallowing and catheter locations. The earliest activation site of sinus rhythm was superior vena cava (SVC) 4 (SVC-right atrium junction), while the earliest activation site of APCs was SVC1-2, which was in the SVC. LAO = left anterior oblique; LSPV = left superior pulmonary vein; RSPV = right superior pulmonary vein; CS = coronary sinus; AP = anteroposterior.

Download English Version:

<https://daneshyari.com/en/article/2925740>

Download Persian Version:

<https://daneshyari.com/article/2925740>

[Daneshyari.com](https://daneshyari.com)