

Transjugular lead fragment extraction to improve tricuspid regurgitation



Robert D. Schaller, DO,^{*} Mouhannad M. Sadek, MD,^{*} Jeffrey J. Luebbert, MD,[†] Jian-Fang Ren, MD,^{*} Francis E. Marchlinski, MD, FHRS^{*}

From the ^{*}Hospital of the University of Pennsylvania, Philadelphia, Pennsylvania, and [†]Pennsylvania Hospital, Philadelphia, Pennsylvania.

Introduction

A 28-year-old-man with a history of human immunodeficiency virus (HIV), end-stage renal disease requiring hemodialysis, and HIV-related cardiomyopathy with a severely reduced left ventricular ejection fraction (LVEF) and severe tricuspid regurgitation (TR) per a transthoracic echocardiogram (TTE) underwent implantation of a single-chamber implantable cardioverter-defibrillator (ICD) in 2009 (Riata 1581, St Jude Medical, St Paul, MN). Because of lead failure resulting in electrical noise manifesting as nonphysiological signals, a totally subcutaneous ICD (Boston Scientific, Inc, Natick, MA) was implanted. The patient was referred for percutaneous extraction of the endovascular lead because of his young age, relatively short lead dwell time, high risk of a future blood stream infection in an HIV-positive patient on chronic hemodialysis, and patient preference after an informed discussion of risks and benefits. The procedure was scheduled for 2 months after subcutaneous ICD implantation to facilitate healing of the new device sites.

There was no fluoroscopic evidence of conductor extrusion (Figure 1A). Examination of the pocket revealed severe calcification of the capsule, requiring complete capsulectomy for the removal of the ICD generator (Figure 2). A transvenous lead extraction procedure was performed using a combination of a locking stylet (LLD EZ, Spectranetics, Colorado Springs, CO) and a 14-F outer diameter SLS II Excimer laser-powered sheath (Spectranetics). Of note, the locking stylet could not be advanced past the distal coil of the

right ventricular (RV) lead. Preoperative intracardiac echocardiography (ICE) imaging with an 8-F phased-array AcuNav catheter (Acuson Corporation, Mountain View, CA) demonstrated an LVEF of 5%–10% with spontaneous echo contrast in the left ventricle (Figure 3A), severe TR, as well as enhanced echogenicity at the lead-myocardial interface along the inferoseptal wall (Figure 3B), suggesting a potentially strong binding site. Antegrade laser application advanced the sheath to the superior vena cava (SVC) where progress was impeded. Because of the tenacious adhesion at the RV apex, further traction resulted in severing of the lead and the locking stylet in the SVC and the right atrium (Figure 1B) before upsizing to a 16-F outer diameter laser-powered sheath or rotational dilator sheath could be considered. The lead was snared from a femoral approach with a 20-mm Amplatz GooseNeck snare (ev3 Inc, Plymouth, MN), as some of the inferiorly directed frayed conductors were amenable to this approach. Despite reinforcement with a steerable sheath (Agilis, St Jude Medical Inc), repeated attempts to disengage the lead from the myocardium resulted in removal of proximal fragments, with inability to extract the distal portion of the lead (Figure 1C). Each attempt resulted in severe hypotension due to partial obstruction of the tricuspid valve (TV) annulus. This resulted in frayed ICD conductors floating freely in the TV as well as a proximal high-voltage coil fragment affixed to the SVC (Figure 1B). No further attempts were made at this point to discuss the risks and benefits of repeated attempts with the patient.

Postoperative ICE imaging revealed normal TV leaflet morphology but worsening of TR, from severe to torrential, on the basis of visual estimation of a dedicated echocardiographer (Figure 3D), likely secondary to the retained lead fragment and frayed conductors restricting valve closure. After a discussion with the patient, a decision was made for a repeat attempt at percutaneous extraction, and this time via a right internal jugular (IJ) approach. Preoperative ICE imaging once again revealed torrential TR. Ultrasound-guided percutaneous access to the right IJ was achieved, and a 25-mm GooseNeck snare was advanced through a steerable sheath (Agilis) to the right atrium (Figure 1D). Once the lead was captured, the Agilis sheath was advanced over the lead

ABBREVIATIONS HIV = human immunodeficiency virus; ICD = implantable cardioverter-defibrillator; ICE = intracardiac echocardiography; IJ = internal jugular; LVEF = left ventricular ejection fraction; RV = right ventricular; SVC = superior vena cava; TTE = transthoracic echocardiogram; TR = tricuspid regurgitation; TV = tricuspid valve (Heart Rhythm Case Reports 2015;1:95–98)

This work was supported in part by the F. Harlan Batrus Research Fund.
Address reprint requests and correspondence: Dr Robert Schaller, Hospital of the University of Pennsylvania, 3400 Spruce St, 9 Founders Pavilion, Philadelphia, PA 19104. E-mail address: robert.schaller@uphs.upenn.edu.

KEY TEACHING POINTS

- The decision to extract an abandoned lead is complex. One must weigh the risks and benefits of each approach and individualize it to each patient.
- Percutaneous lead extraction from the right internal jugular vein is a nontraditional and uncommon technique. In the setting of failed subclavian or femoral extraction, this strategy appears safe and should be considered.
- Right ventricular pacing and defibrillator leads can cause worsening of tricuspid regurgitation. Extraction of such leads may help valvular function. This should be one of the considerations as part of a comprehensive lead management strategy.

body enveloping some of the conductors but was ultimately unable to advance to the lead tip. With the lead firmly positioned at the tip of the sheath, traction was used to pull the lead back to the TV (Figures 1E and 3E; Online Supplemental Video 1), where it finally broke free of its endocardial binding site. The lead and the sheath were

removed from the body at the same time, followed by manual pressure at the entrance site. Next, the Agilis sheath was placed in the right femoral vein and used to snare and remove the high-voltage coil fragment in a similar manner. ICE imaging revealed a significant decrease in TR immediately after the procedure compared to before the procedure (Figure 1I). The patient was discharged home the following day in stable condition. Follow-up TTE at 5 months revealed TR to be mild, suggesting that much of the baseline TR was likely caused by mechanical interaction with the RV lead before the index procedure. Of note, the LVEF also improved from 5%–10% to 40% (Online Supplemental Videos 2 and 3).

Discussion

There is an increasing demand for percutaneous lead extraction as indications have expanded and tools and technologies have evolved.¹ Lead advisories and an increase in device-related infections are some of the reasons why physicians are now more likely to encounter patients with complicated management issues requiring complex and inventive solutions.

One must always balance the risks and benefits of lead extraction vs abandonment on a case-by-case basis. In this

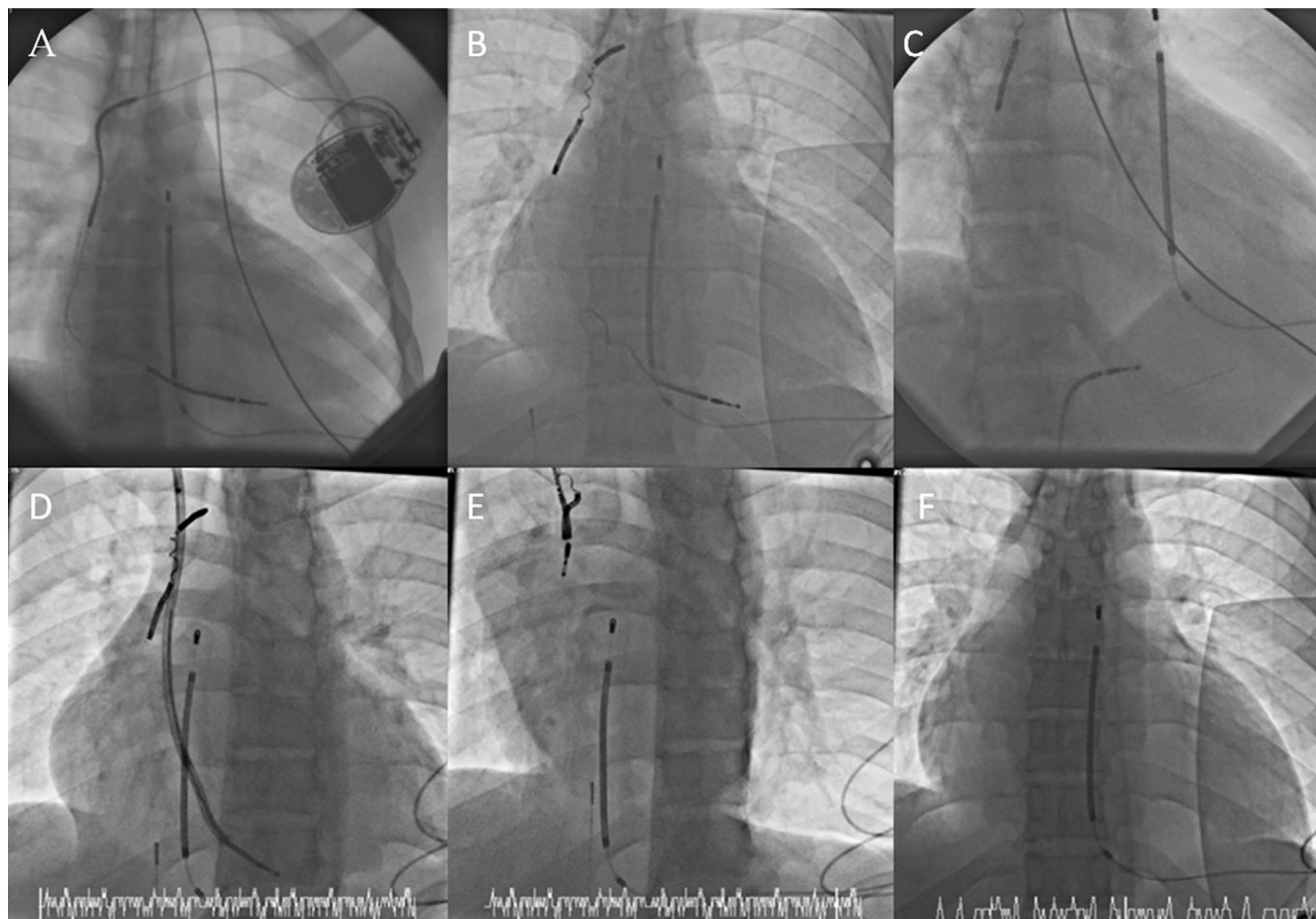


Figure 1 Fluoroscopic images for the extraction of an implantable cardioverter-defibrillator (ICD) lead: (A) baseline image, (B) broken lead with frayed conductors in the tricuspid valve and coil fragment along the superior vena cava, (C) snare attempt with traction from below, (D) lead fragment snared from above, (E) snare attempt with traction from above (note the deformity of the cardiac silhouette before disengagement), and (F) immediately after extraction.

Download English Version:

<https://daneshyari.com/en/article/2925758>

Download Persian Version:

<https://daneshyari.com/article/2925758>

[Daneshyari.com](https://daneshyari.com)