

Successful interventional management of catastrophic coronary arterial air embolism during atrial fibrillation ablation



Khurram Ahmad, MD,^{*} Samuel Asirvatham, MD,[†] Sreenivas Kamath, MD,^{*} Stephen Peck, MD,^{*} Xiaoke Liu, MD, PhD^{*}

From the ^{*}Borgess Medical Center and Western Michigan University, Homer Stryker M.D. School of Medicine, Kalamazoo, Michigan, and [†]Mayo Clinic, Rochester, Minnesota.

Introduction

Air embolism is a well-recognized complication associated with interventional cardiac procedures, including electrophysiologic studies and ablations.^{1–4} Much less common is air embolization leading to immediate cardiogenic shock requiring resuscitation, especially in the electrophysiology (EP) laboratory.^{5–8} There have been several anecdotal reports of cardiogenic shock caused by massive coronary artery air embolism not related to EP procedures in the literature.^{9–13} However, the true incidence of air embolism in the EP laboratory remains unclear, possibly owing to under-reporting or underdetecting, since most of these cases have a relatively benign clinical course and do not require urgent, resuscitative treatment.^{14–17} We here report a case of massive air embolism with obstruction of the entire right coronary artery (RCA), leading to rapid hemodynamic collapse, and successful management of this condition using catheter-based coronary aspiration.

Case report

A 55-year-old man with highly symptomatic, drug-refractory paroxysmal atrial fibrillation was admitted for an elective ablation procedure under conscious sedation. His past medical history included hypertension, hyperlipidemia, and coronary artery disease (CAD) status post drug-eluting stent placement in the left circumflex coronary artery. He had no documented history of obstructive sleep apnea.

After usual sterile preparation and draping, 3 8F venous sheaths were placed in the right femoral vein and 1 4F sheath was placed in the right femoral artery for hemodynamic

monitoring, which is routinely performed for atrial fibrillation ablation in our laboratory. An intracardiac echocardiogram catheter (ICE) was placed in the right atrium to examine the atrial septum and pulmonary vein anatomy and to guide transseptal access. Real-time continuous arterial pressure was recorded for hemodynamic monitoring. Anticoagulation was maintained with intravenous heparin to keep the anticoagulation time of >350 seconds.

The first transseptal access was obtained without difficulty under ICE and fluoroscopy guidance. The patient was noted to have short episodes of obstructive apnea and intermittent snoring in the beginning of the procedure when he was placed under conscious sedation. After transseptal access, as part of the routine air management, the 3-way valve on the transseptal sheath was opened to air to bleed out a small amount of blood to purge off small air bubbles that are usually present in the long sheath. At the same time that the valve was opened, the patient took a very strong, deep breath after overcoming a short period of obstructive apnea and a significant amount of air was seen being suctioned back into the sheath. The valve was immediately closed and negative pressure was applied via a syringe to try to suction out the air trapped in the transseptal sheath. Despite that, within a few minutes, there was prominent ST segment elevation on the monitor observed in leads II, III, and aVF. This was accompanied by a precipitous drop in the systolic blood pressure to the 60s–70s range and the patient became unresponsive. Real-time ICE did not show any evidence of cardiac tamponade, but the entire right ventricle was found to be nearly akinetic. Air embolism in the RCA was immediately suspected. Intravenous (IV) fluids and IV epinephrine were given, followed by a continuous IV drip. An interventional cardiologist was urgently called to the EP laboratory and a temporary pacemaker was placed in the right ventricle in anticipation of atrioventricular (AV) block. Emergent right coronary angiography was performed within the first 5–10 minutes of the onset of ST elevation, which revealed extensive air bubbles in the entire RCA territory with TIMI 0 flow (Figure 1). At this time, the patient was noted to develop

KEYWORDS Atrial fibrillation; Ablation; Air embolism; ST elevation; Interventional procedure; Aspiration (Heart Rhythm Case Reports 2016;2:153–156)

Dr Ammad is currently at Beaumont Hospital, Oakwood Campus, Dearborn, Michigan. **Address reprint requests and correspondence:** Dr Xiaoke Liu, Director, Device and EP Clinic, Borgess Medical Center, 1722 Shaffer St, Kalamazoo, MI 49048. E-mail address: Xiaoke.liu@borgess.com.

KEY TEACHING POINTS

- Every effort should be made to prevent air embolism, which can be potentially life-threatening.
- Early recognition of air embolism is extremely important to prevent irreversible organ damage.
- Urgent intervention through air aspiration can lead to successful resuscitation in catastrophic cases.

worsening AV block and eventually developed complete heart block. Temporary pacing was commenced but the patient continued to deteriorate, with increasing pacing output required to maintain capture in the right ventricle. As the resuscitation continued, intermittent loss of right ventricular capture started to develop despite adequate positioning of the pacing wire and maximum pacing output. At this time, we elected to proceed with urgent aspiration of the air emboli through an interventional thrombus aspiration catheter. This was successfully achieved using a Pronto (Vascular Solutions, Inc, Minneapolis, MN) aspiration catheter. Post intervention, TIMI 3 flow was immediately achieved in the RCA (Figure 2). No additional flow-limiting lesion was found in the right and the left system. The patient had baseline mild to moderate CAD including 30% left main, 30% left circumflex, and 40% proximal RCA lesions. These lesions did not demonstrate any significant change compared to his previous coronary angiogram, which was performed about 6 months before

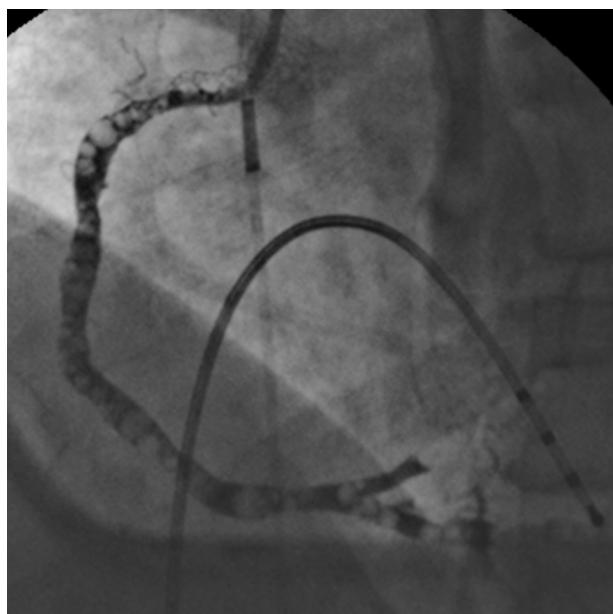


Figure 1 Right coronary artery (RCA) angiography in the left anterior oblique view. Extensive air bubbles were shown to fill the entire RCA. An intracardiac ultrasound catheter and temporary pacing catheter are also shown in the figure. The transseptal apparatus has already been removed. The left coronary artery was not involved (not shown).

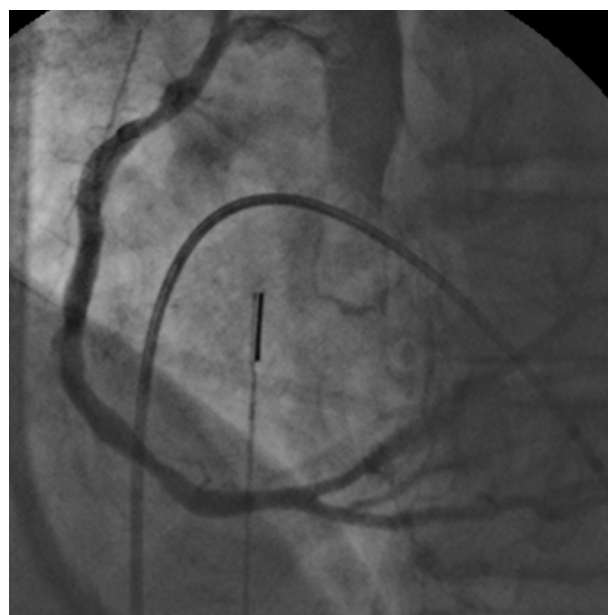


Figure 2 Follow up angiogram after successful intervention. TIMI 3 flow has been restored immediately after air aspiration using a thrombus aspiration catheter. No residual air bubbles were observed.

the ablation procedure. The patient's hemodynamics improved shortly after the intervention, with complete resolution of AV block within 15 minutes post intervention. ICE imaging showed rapid, progressive improvement of the right ventricular systolic function immediately after intervention. Essentially complete recovery of the right ventricular contractility was observed within 30 minutes after coronary intervention. The patient completely recovered and was off vasopressors and temporary pacing within an hour. The procedure was aborted but the patient subsequently underwent 2 successful ablations under general anesthesia without further complications and remained in sinus rhythm off antiarrhythmics since the last ablation in 2011.

Discussion

Coronary air embolism is a well-known and potentially life-threatening complication of left heart catheterization, with a reported incidence of 0.1%–0.3%.^{2,3,5} Most of these are asymptomatic or have a benign outcome, but mortality has been reported from severe air embolism.¹ Similarly, coronary air embolism has been reported in the literature during transseptal puncture with an incidence of coronary air embolism and other thromboembolic complication rate of 0.71%⁵ to up to 1.4%.¹⁸ Air emboli may potentially be treated by several approaches, such as hyperbaric oxygen, forceful flushing of coronary arteries with saline, or aspiration of the air.^{4,5} In this case, we found that catheter-based aspiration of air bubbles inside the RCA resulted in immediate recovery of the patient and appeared to be a life-saving technique to manage this complication.

Download English Version:

<https://daneshyari.com/en/article/2925834>

Download Persian Version:

<https://daneshyari.com/article/2925834>

[Daneshyari.com](https://daneshyari.com)