

Epicardial ablation of ventricular tachycardia in a patient with Becker muscular dystrophy



Siva Mohan Krothapalli, MD, Elaine Demetroulis, MD, Gardar Sigurdsson, MD, Gary Goldsmith, RT, Alexander Mazur, MD

From the Division of Cardiovascular Medicine, University of Iowa Hospitals and Clinics, Iowa City, Iowa.

Introduction

Becker muscular dystrophy (BMD) and Duchenne muscular dystrophy (DMD) are X-linked genetic disorders involving abnormal dystrophin synthesis.¹ Cardiac involvement is frequent in these disorders. Echocardiograms show abnormal systolic function of the left ventricle (LV) in 50%–70% of BMD patients, whereas evidence of myocardial damage detected by cardiac magnetic resonance (CMR) imaging can be found even in patients with normal echocardiograms.^{2–4} Some mutations in the dystrophin gene cause isolated cardiomyopathy without skeletal myopathy.⁵ Although ventricular arrhythmias appear to be a common manifestation of dystrophin-associated cardiomyopathy, their mechanism and arrhythmogenic substrate are poorly characterized.²

We report a case of recurrent drug-refractory ventricular tachycardia (VT) treated with epicardial ablation in a BMD patient with dilated cardiomyopathy.

Case report

The patient is a 26-year-old male with a history of BMD due to deletion of exons 38–43 in the dystrophin gene. The disease was first diagnosed in 2005 when he presented to a pediatric neurology clinic with proximal muscle weakness and elevated creatinine kinase levels. A multigated acquisition scan, done as a part of his initial workup, revealed an LV ejection fraction (LVEF) of 36%. In 2011, in view of progressive worsening of his LV systolic function despite optimal medical therapy (LVEF of 20% by echocardiogram), he underwent placement of a primary prevention implantable cardioverter defibrillator (ICD). In June 2013, he received an ICD shock for syncope monomorphic VT at a rate of 260 beats per minute (bpm). ICD interrogation also showed multiple logged nonsustained VTs. He was subsequently started on amiodarone. In November 2014, after a period of

relative quiescence, the patient presented to an outside hospital with recurrent VT requiring 2 ICD shocks. The maintenance dosage of amiodarone was temporarily increased from 200 to 400 mg a day. In April 2015, he presented with another episode of syncope. ICD interrogation revealed 2 additional episodes of monomorphic VT (230–250 bpm) terminated by shocks. VT ablation was thus pursued. A preprocedure contrast-enhanced cardiac computed tomography (CT) image showed severely enlarged LV (LV-end diastolic volume and end systolic volume of 366 mL and 256 mL, respectively), LVEF of 30%, global hypokinesis, and akinesis of the inferolateral wall of the LV. The right ventricle was normal. First-pass contrast-enhanced images suggested loss of myocardium predominantly within the inferolateral wall of the LV (Figure 1A). Delayed enhancement was noted in these segments, with sparing of the subendocardium. An epicardial origin of his arrhythmia was suspected based on the latter finding as well as previously published postmortem and CMR series showing predominantly subepicardial involvement in dystrophin-associated cardiomyopathies (please see the Discussion section).

The patient presented to the electrophysiology (EP) laboratory in sinus rhythm (SR) with intermittent atrial pacing at a rate of 65 bpm. Surface electrocardiogram (ECG) showed a right bundle branch block (RBBB) intrinsic QRS pattern with QRS duration of 190 milliseconds and PR interval of 250 milliseconds. The AH interval was 75 milliseconds and HV interval was 84 milliseconds. An intracardiac ultrasound probe (CARTO Sound, Biosense Webster, Diamond Bar, CA) and an electroanatomic mapping (EAM) system (CARTO 4, Biosense Webster) were then used to create endocardial geometries of the ventricles.

After obtaining pericardial access, a high-density epicardial voltage map was obtained in SR using a decapolar catheter (DecaNav, Biosense Webster). The mapping catheter was placed into the pericardium via a steerable sheath used for better maneuverability and support (40 cm, Agilis, St Jude Medical, St Paul, MN). There was a large area of low-amplitude (< 1 mV) fractionated electrograms (EGMs) in the inferolateral wall of the LV consistent with “scar” (Figure 1B).⁶ The “scar” area corresponded to the area of abnormal substrate on the CT images (Figures 1A and 1B).

KEYWORDS Becker muscular dystrophy; Ventricular tachycardia; Electroanatomic mapping; Epicardial ablation; Epicardial scar; Cardiomyopathy (Heart Rhythm Case Reports 2016;2:183–186)

Conflict of interest: None relevant to this manuscript for all authors.
Address reprint requests and correspondence: Dr Alexander Mazur, 318E GH, 200 Hawkins Dr, Iowa City, IA 52242. E-mail address: alexander-mazur@uiowa.edu.

KEY TEACHING POINTS

- Evidence of myocardial damage on cardiac magnetic resonance images is found in a majority of patients with muscular dystrophies involving abnormal dystrophin synthesis (Becker and Duchenne muscular dystrophies).
- Subepicardial fibrosis of the inferolateral wall of the left ventricle (LV) is a pathological hallmark of dystrophin-associated cardiomyopathies. Subendocardial myocardium is usually spared.
- In our case, the area of abnormal electroanatomic substrate was confined entirely to the epicardial surface of the inferolateral LV, whereas endocardial LV mapping was normal. This case report highlights importance of epicardial ventricular tachycardia (VT) mapping in patients with dystrophin-associated cardiomyopathies.
- Contrast-enhanced cardiac computed tomography can be potentially useful for localizing of abnormal myocardial substrate in patients with an implantable cardioverter defibrillator undergoing VT ablation.

High-frequency (mostly multicomponent) potentials were noted predominantly at the border of the “scar” (Figure 1C). Following transseptal access, high-density SR endocardial

voltage mapping of the LV was performed with a duodecapolar catheter (Pentaray, Biosense Webster). This mapping demonstrated normal voltage (>1.5 mV) and EGM morphology over the entire endocardial surface of the LV.

A monomorphic VT with RBBB/superior-axis QRS morphology and a cycle length (CL) of 305 milliseconds was easily (double extrastimuli) and reproducibly induced with programmed ventricular stimulation (Figure 2A). There were no identifiable His potentials. Twelve-lead QRS morphology of the tachycardia suggested its epicardial origin (slurring in the initial portion of the QRS, inferior Q waves, pseudo delta wave of 95 milliseconds, and a maximum deflection index of 0.6 milliseconds).^{7,8} Detailed activation and entrainment mapping was not feasible, because of rapid hemodynamic compromise and inconsistent ventricular capture at the maximum output over most of the attempted pacing sites within the epicardial “scar.” Thus, brief epicardial activation mapping with the decapolar catheter during VT was limited to the area exhibiting high-frequency potentials in SR. Sites showing sharp high-frequency mid- or continuous diastolic potentials were tagged on the map (Figures 1B and 2B). VT CL transiently increased from 305 to 330 milliseconds during mapping at these sites. Endocardial LV mapping during VT was not done. Coronary angiography of the left coronary system was then performed, and the angiogram was registered to the epicardial map using the UNIVU technology (Biosense Webster) to avoid ablating directly near the coronary arteries. High-output pacing was performed to mark the course of the phrenic nerve (PN)

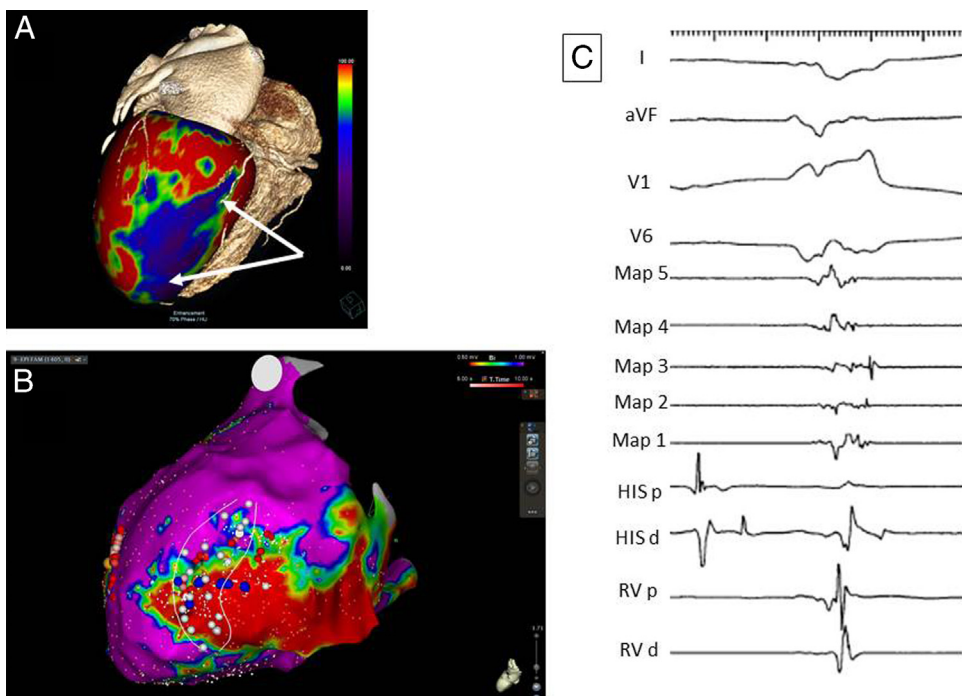


Figure 1 **A:** Electrocardiogram-gated cardiac computed tomography image with a volumetric, color-coded, first-pass contrast enhancement map of the left ventricle (LV). Note an area of hypoenhancement in the inferolateral wall of the LV (arrows) suggesting abnormal myocardial substrate. **B:** Epicardial voltage map demonstrates an extensive area of low-amplitude (<1 mV) and fractionated electrograms consistent with “scar” in the inferolateral LV. Sites with diastolic potentials recorded during initially induced ventricular tachycardia are shown as blue spheres. Teal and red spheres represent ablation lesions color-coded according to their duration. Phrenic nerve capture sites are marked with white spheres. **C:** An example of high-frequency multicomponent potentials (Maps 1–5) recorded in the area of epicardial “scar” in sinus rhythm.

Download English Version:

<https://daneshyari.com/en/article/2925841>

Download Persian Version:

<https://daneshyari.com/article/2925841>

[Daneshyari.com](https://daneshyari.com)