

Pseudo typical atrial flutter occurring after cavotricuspid isthmus ablation in a patient with a prior history of Senning operation



Naoki Yoshida, MD, Takumi Yamada, MD

From the Division of Cardiovascular Disease, University of Alabama at Birmingham, Birmingham, Alabama.

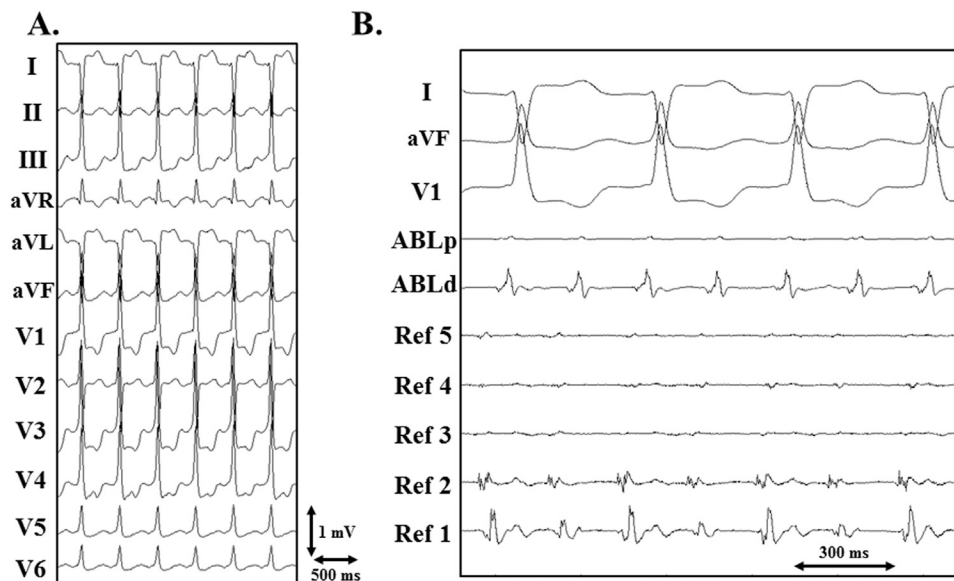


Figure 1 A: Twelve-lead electrocardiogram recorded during supraventricular tachycardia. B: Cardiac tracings showing supraventricular tachycardia with a cycle length of 220 ms and 2:1 atrioventricular conduction. ABLd (p) = the distal (proximal) electrode pair of the ablation catheter; Refs 1 to 5 = the first (distal) to fifth (proximal) electrode pairs of the reference catheter positioned in the systemic venous atrium.

Introduction

A typical cavotricuspid isthmus (CTI)-dependent atrial flutter (AFL) is the most common among supraventricular tachycardias (SVTs) that occur after a surgical repair of congenital heart diseases.¹⁻⁴ It is known that recurrent SVTs after successful CTI ablation can mimic a typical AFL.⁵⁻⁷ We report a pseudo typical AFL occurring after successful CTI ablation with a unique mechanism in a patient with a Senning operation.

KEYWORDS Transposition of the great arteries; Senning operation; Trans-baffle puncture; Intra-atrial reentrant tachycardia; Catheter ablation
ABBREVIATIONS AFL = atrial flutter; CTI = cavotricuspid isthmus; IVC = inferior vena cava; PVA = pulmonary venous atrium; SVA = systemic venous atrium; SVT = supraventricular tachycardia; TA = tricuspid annulus (Heart Rhythm Case Reports 2015;1:54-57)

Address reprint requests and correspondence: Dr Takumi Yamada, Division of Cardiovascular Disease, University of Alabama at Birmingham, FOT 930A, 510 20th St S, 1530 3rd Avenue S, Birmingham, AL 35294. E-mail address: takumi-y@fb4.so-net.ne.jp.

Case report

A 33-year-old woman with a history of d-transposition of the great arteries, Senning operation, and tricuspid valve replacement had undergone successful catheter ablation of CTI-dependent AFL.⁴ CTI conduction block had been achieved at the posteroseptal aspect of the tricuspid annulus (TA) by catheter ablation from the systemic venous atrium (SVA) and the addition of irrigated ablation from underneath the mechanical tricuspid valve via a retrograde transaortic approach.⁴ However, several months later, SVT recurred and she underwent catheter ablation of SVT. A decapolar catheter was positioned in the SVA via the inferior limb of the Senning baffle as a reference. SVT with a cycle length of 220 ms exhibited sawtooth-type flutter waves in the inferior leads (Figure 1). Activation mapping with an irrigated ablation catheter in the SVA revealed a centrifugal activation pattern from the mid-posterior border between the SVA and the pulmonary

KEY TEACHING POINTS

- Recurrent supraventricular tachycardias after successful cavotricuspid isthmus ablation can mimic a typical atrial flutter (AFL).
- This case report illustrated a pseudo typical AFL occurring after successful cavotricuspid isthmus ablation with a unique mechanism using the isthmus between the intercaval scar and the inferior vena cava baffle in a patient with a prior history of Senning operation.
- Mapping and catheter ablation via a transbaffle approach is effective in treating this kind of AFL.

venous atrium (PVA). A transbaffle puncture was then performed under fluoroscopic guidance and an atriogram in the superior portion of the inferior baffle limb to gain access

to the PVA. Activation mapping in the PVA revealed a counterclockwise reentrant activation pattern along the TA, and the total activation time was equal to the cycle length of SVT (Figure 2A). Entrainment pacing was attempted at the CTI site in the PVA, resulting in termination of SVT. Activation mapping was performed in the PVA during pacing from the posterior septum in the SVA, confirming CTI conduction block (Figure 2B). Voltage mapping was then performed in the PVA during sinus rhythm, revealing a large intercaval scar on the right atrial posterior wall (Figure 2C). SVT was reinduced, and activation mapping was repeated. SVT was terminated during mapping at the site of the isthmus between the intercaval scar and the inferior vena cava (IVC) baffle where a delayed fractionated atrial electrogram was recorded during sinus rhythm (Figure 3). Irrigated radiofrequency ablation was performed to connect the intercaval scar and IVC baffle (Figure 2C). Activation mapping was performed in the PVA during pacing from the posterior septum in the SVA, confirming conduction block at the isthmus between the intercaval scar

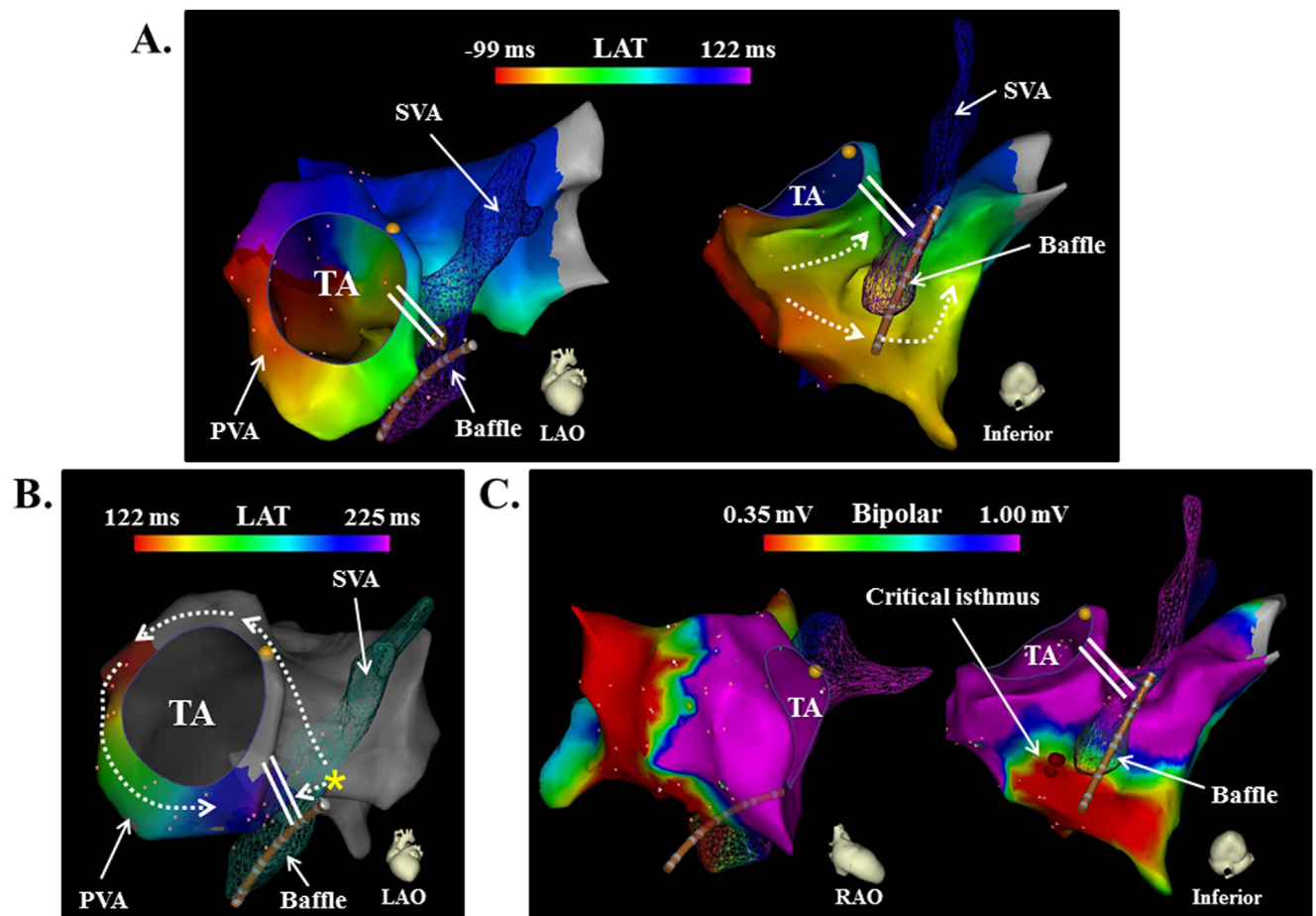


Figure 2 **A:** Activation map of the pulmonary venous atrium (PVA) and systemic venous atrium (SVA) during supraventricular tachycardia (SVT) exhibited a counterclockwise activation pattern along the tricuspid annulus (TA). Note that the total activation time was equal to the cycle length of SVT. Also note that the activation in the posterior wall of the right atrium propagated upward more quickly than along the tricuspid annulus, suggesting conduction block of the cavotricuspid isthmus at the posteroseptal aspect of the TA. The double line indicates the site of the conduction block line at the cavotricuspid isthmus. LAO = left anterior oblique projection; LAT = local activation time. **B:** Activation map of the PVA obtained during pacing from the reference catheter positioned in the inferior baffle of the SVA demonstrated cavotricuspid isthmus conduction block. The yellow asterisk indicates the pacing site. The double line indicates the site of the conduction block line at the cavotricuspid isthmus. **C:** A bipolar voltage map of the PVA and SVA obtained during sinus rhythm revealed a large intercaval scar on the right atrial posterior wall. RAO = right anterior oblique projection.

Download English Version:

<https://daneshyari.com/en/article/2925954>

Download Persian Version:

<https://daneshyari.com/article/2925954>

[Daneshyari.com](https://daneshyari.com)