

Functional permanent 2:1 atrioventricular block treated with cardioneuroablation: Case report



Tolga Aksu, MD,^{*} Sukriye Ebru Golcuk, MD,^{*} Tümer Erdem Guler, MD,^{*} Kıvanç Yalin, MD,[†] Ismail Erden, MD^{*}

From ^{*}Department of Cardiology, Derince Education and Research Hospital, Kocaeli-Turkey, and [†]Department of Cardiology, Istanbul Faculty of Medicine, Istanbul, Turkey.

Introduction

A 54-year-old woman had undergone slow pathway ablation for AV nodal reentrant tachycardia 3 years ago. Before admission she had started to present with recurrent dizziness and syncope due to 2:1 AV block and was referred for pacemaker implantation. She was asymptomatic and had no signs of AV conduction abnormalities until 2 weeks ago. AV conduction abnormality resolved with atropine infusion until stage 2 of a treadmill exercise test. Electrophysiologic study showed suprahisian 2:1 AV block. After cardioneuroablation, the parameters of AV conduction normalized. Holter recordings were normal, and the patient was asymptomatic at the end of 12-month follow-up.

Several clinical conditions comprise autonomic dysfunction by enhanced parasympathetic tone together with decreased sympathetic tone. Enhanced parasympathetic tone may cause sinus bradycardia or pauses, transient or permanent atrioventricular (AV) block, carotid sinus syndrome, or neurally mediated reflex syncope. Although the conduction system is not involved in these patients, they may present with serious symptoms. The parasympathetic postganglionic neuron body cell is located at the cardiac wall in the paracardiac ganglia.^{1–3} Cardioneuroablation is a little known technique for management of patients with excessive vagal activation. The technique is based on radiofrequency (RF) catheter ablation of autonomic connections in the 3 main ganglia around the heart.⁴

Case report

Medical history

A 54-year-old woman was referred to our clinic for implantation of a permanent pacemaker because of symptomatic 2:1 AV block. The patient had undergone successful selective slow pathway ablation for AV nodal reentrant tachycardia 3 years ago.

KEYWORDS Cardioneuroablation; Atrioventricular block; Ablation; Syncope
ABBREVIATIONS AV = atrioventricular; EPS = electrophysiologic study; LA = left atrium; RA = right atrium; RF = radiofrequency (Heart Rhythm Case Reports 2015;1:58–61)

Address reprint requests and correspondence: Dr. Tolga Aksu, Derince Education and Research Hospital Department of Cardiology, Derince, Kocaeli/Turkey 41000. E-mail address: aksutolga@gmail.com.

At EPS, the shortest atrial pacing cycle length that maintained 1:1 anterograde conduction was in the normal range (280 ms before the procedure and 320 ms after the procedure). The A-H interval was unchanged at the end of the procedure. The patient was asymptomatic during 3-year follow-up, and follow-up ECGs revealed no conduction abnormalities.

Admission history

Three weeks before admission, the patient began to present with recurrent dizziness and syncope. Repeated Holter recordings showed 2:1 AV block with a ventricular rate of 45 bpm that was ongoing throughout the day. After atropine sulfate infusion (0.04 mg/kg), 2:1 AV block gradually disappeared (Figure 1). During stage 2 of a treadmill exercise test, her ventricular rate suddenly increased, and stable 1:1 AV conduction with a rate of 120 bpm appeared. There was no chronotropic incompetence. Based on these findings, we considered AV block to be functional; therefore, we decided to perform cardioneuroablation. The patient provided written informed consent for the ablation procedures. The procedure was performed with the patient in a nonsedated state.

Electrophysiologic study

Three electrophysiologic catheters were placed via venous puncture into the right atrium (RA), right ventricle, and His-bundle region for conventional EPS, which revealed suprahisian 2:1 AV block with normal sinus node function. Using a 4-mm open-tip irrigated RF catheter (Cool Flex, St. Jude Medical, St. Paul, MN), the 3-dimensional geometry of the RA and the left atrium (LA) was created using a 3-dimensional electroanatomic mapping system (EnSite Velocity, St. Jude Medical, Sylmar, CA). Bipolar endocardial electrograms were displayed at filter settings of 30–500 Hz and 300–500 Hz (for EPS and online spectral analysis, respectively) and measured at a sweep speed of 400 mm/s. All recordings were stored on optical disk (EP-Workmate Recording System, St. Jude Medical, St. Paul, MN). Localization of the ganglia was detected by high-frequency stimulation (20 Hz, 0.1–1 mA, 1- to 10-ms pulse width; 3510 multiprogramming stimulator, St. Jude Medical, Sylmar, CA) through the ablation catheter to atrial tissue. This technique has been reported elsewhere.⁵

KEY TEACHING POINTS

- The right atrial approach is sufficient for vagal denervation of the atrioventricular (AV) node.
- Potentials > 300 Hz have excellent correlation with fibrillar atrial myocardium in the region compatible with paracardiac ganglia, which present a heterogenous and coarse segmented spectrum.
- Cardioneuroablation in patients with functional AV block is feasible and may be a valuable adjunctive therapy in patients who cannot be adequately treated by conventional modalities and refuse pacemaker implantation.

Potentials > 300 Hz were shown to have excellent correlation with fibrillar atrial myocardium in the region compatible with paracardiac ganglia, which present a heterogenous and coarse segmented spectrum (Figure 2).

Cardioneuroablation

As shown by animal studies, 3 main parasympathetic ganglia located outside the atrial wall in paracardiac fat pads provide innervation to the heart.^{1–3} Ganglion A is located between the aorta and the superior vena cava; ganglion B is located between the right pulmonary veins and the RA; and ganglion C is located between the inferior vena cava and the RA/LA (Figure 3). Ganglion A appears to be the “head station” of vagal fibers traveling to both the atria and the sinus and AV nodes.^{2,3} Bilateral vagal fibers to the sinus and AV nodes also converge first at ganglion A (a few fibers to the sinus node go directly to ganglion B) and then project to ganglia B and C, which provide vagal innervation to the sinus and AV nodes, respectively.

As mentioned earlier, the ablation procedure was performed only via the RA. The RA sites showing a parasympathetic response (bradycardic response with progressive slowing of the sinus rate by 50%) and fibrillar atrial myocardium pattern

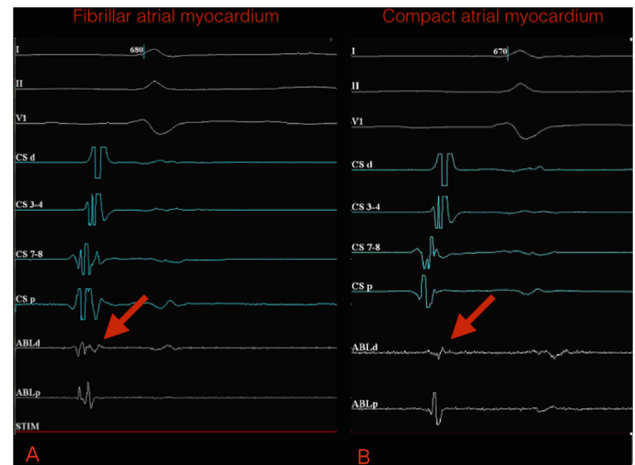


Figure 2 A: Fibrillar atrial myocardium potentials (heterogeneous and coarse segmented spectrum) (arrow) on intracardiac electrograms. B: Compact atrial myocardium potentials (homogeneous spectrum) on intracardiac electrograms. Bipolar endocardial electrograms are displayed at filter settings of 300–500 Hz at a sweep speed of 400 mm/s. ABLd = distal electrode of ablation catheter; ABLp = proximal electrode of ablation catheter; CSd = distal electrode of coronary sinus catheter; CSp = proximal electrode of coronary sinus catheter.

were assigned as targets and ablated until atrial electrical potential was almost completely eliminated (<0.1 mV; Figure 4 and Online Supplementary Video). A high degree AV block was seen during RF application at targeted sites. After AV node denervation by ablation of ganglia A and C via the RA approach, AV conduction resolved completely.

RF current was delivered point by point at a power of 35 W (maximum 40 W) and applied in temperature-controlled mode. The target temperature was 40°C, with a cooling rate of 18 mL/min until elimination (<0.1 mV) of atrial fractionated potentials >300 Hz. Continuous flow during mapping was 2 mL/min.

Postprocedure Wenckebach point was 285 ms. Total procedural time was 75 minutes, and total fluoroscopy time was 17 minutes. A total of 21 endocardial points were treated.

Follow-up

The patient has been completely asymptomatic, experiencing no episodes of dizziness or syncope and taking no medications at the end of 12-month follow-up. All follow-up ECGs and Holter recordings have been normal. No other pause or AV block has yet been recorded. The minimum and mean heart rates changed from 65 and 79 bpm at 1 month to 62 and 77 bpm, 58 and 72 bpm, and 55 and 71 bpm at 3 months, 6 months, and 1 year postprocedure, respectively.

Discussion

Pachon et al⁴ were the first to report cardiac autonomic modulation through catheter ablation guided by fast Fourier transformation analysis as an alternative treatment of functional intermittent high-degree AV block. In 7 of 21 patients included in their study, the diagnosis was

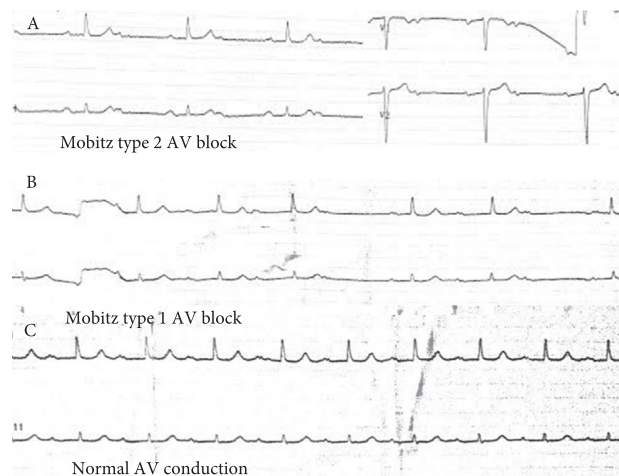


Figure 1 A: Baseline ECG showing 2:1 AV block. B: After atropine bolus, 2:1 AV block immediately turns to Mobitz type 1 AV block. C: Normal AV conduction is achieved at the late stage of atropine sulfate infusion.

Download English Version:

<https://daneshyari.com/en/article/2925955>

Download Persian Version:

<https://daneshyari.com/article/2925955>

[Daneshyari.com](https://daneshyari.com)