

Available online at [www.sciencedirect.com](http://www.sciencedirect.com)

ScienceDirect

journal homepage: [www.elsevier.com/locate/ihj](http://www.elsevier.com/locate/ihj)

## Case Report

# Total arterial anaortic off-pump coronary artery bypass grafting for diffuse coronary disease – A case report



Kamales Kumar Saha<sup>\*</sup>, Mandar M. Deval, Shekhar Ambardekar, Ajay Kumar, Kakalee K. Saha

Fortis S L Raheja Hospital, Raheja Rugnalaya Marg, Mahim West Mumbai, Maharashtra, India

## ARTICLE INFO

## Article history:

Received 6 August 2014

Accepted 9 April 2015

Available online 14 May 2015

## Keywords:

Off-pump coronary artery bypass grafting

Diffuse coronary artery disease

Anaortic CABG

Arterial graft

## ABSTRACT

Surgical treatment of diffuse coronary artery disease remains challenging. We present here a diabetic patient, with diffuse coronary disease, revascularized using total arterial anaortic off-pump coronary artery bypass grafting. He received total nine distal grafts. He continues to be asymptomatic after more than 2 years. CT angiography follow-up shows eight out of nine grafts are patent. Anaortic off-pump coronary artery bypass grafting has the least incidence of stroke and arterial grafts have the best long-term patency rate. This is the first case report of nine arterial bypass graft performed off-pump using both internal mammary and both radial arteries. Anaortic total arterial off-pump coronary artery bypass grafting has achieved excellent intermediate term result in this patient of diffuse coronary artery disease.

Copyright © 2015, Cardiological Society of India. All rights reserved.

## 1. Introduction

Surgical treatment of diffuse coronary artery disease remains challenging. We are using anaortic total arterial off-pump coronary artery bypass (OPCAB) revascularization to deal with such complex surgical challenges. We report here successful surgical revascularization of a patient with very diffuse coronary artery disease and small distal vessels.

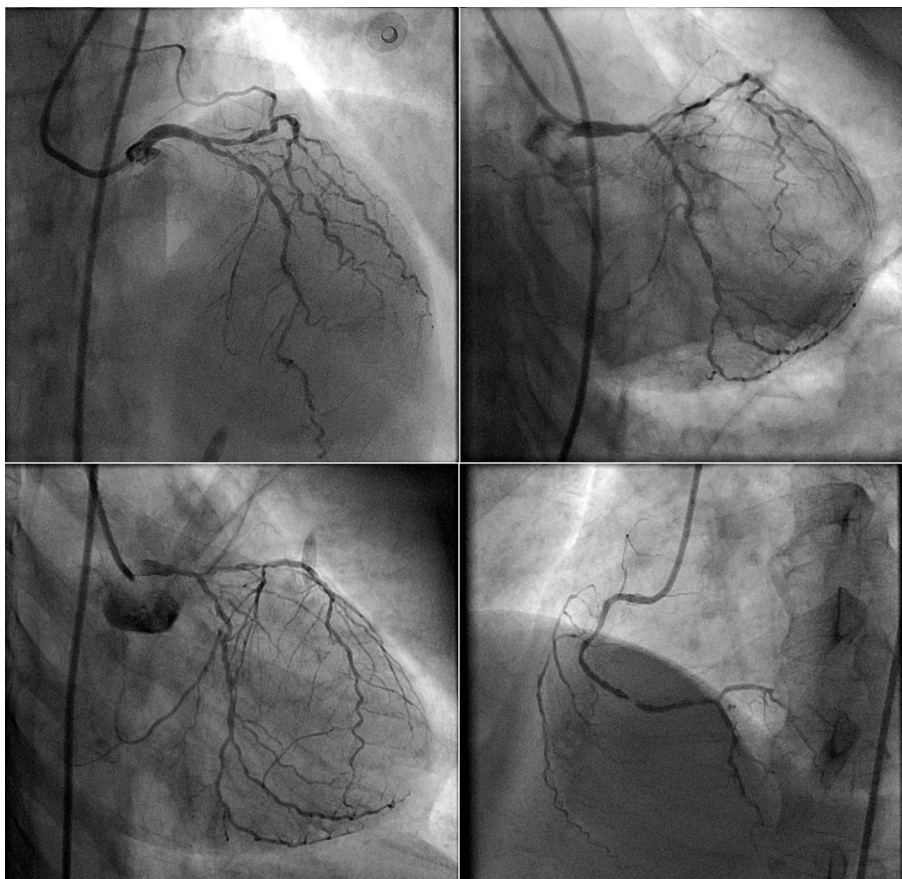
## 2. Case report

A 56 years old male diabetic, hypertensive patient presented with triple vessel coronary artery disease and normal ventricular function. The coronary angiography revealed diffuse coronary artery disease with small distal vessels (Fig. 1). He underwent elective coronary artery bypass grafting.

<sup>\*</sup> Corresponding author. C-801/802 Raheja Sherwood, Behind Hub Mall, Off Western Express Highway, Nirlon Compound, Goregaon East, Mumbai 400063, India. Tel.: +91 7208045555.

E-mail address: [kamalessk@gmail.com](mailto:kamalessk@gmail.com) (K.K. Saha).  
<http://dx.doi.org/10.1016/j.ihj.2015.04.005>

0019-4832/Copyright © 2015, Cardiological Society of India. All rights reserved.



**Fig. 1 – Coronary angiography of the patient showing severe coronary artery disease with diffuse distal disease and small distal vessels.**

### 3. Surgical technique

OPCAB surgery was performed through median sternotomy. Both radial arteries and both internal mammary arteries were harvested. We did not use any deep pericardial stay suture. Warm saline soaked gauze pieces were used to position the heart. Suction type of stabilizer and mister blower was used for OPCAB grafting.

LAD (left anterior descending) had diffuse mid segment disease. LIMA (left internal mammary artery) was used for sequential grafting of mid and distal LAD. Right internal mammary artery (RIMA) and right radial artery (RRA) y graft was prepared where end of RRA was anastomosed to the side of RIMA. RIMA was used to graft diagonal artery. Left radial artery (LRA) was anastomosed to the side of the RRA as ‘y’ graft. RRA was used to graft first obtuse marginal (OM1) in proximal segment and second obtuse marginal (OM2) in distal segment. LRA was used to graft third obtuse marginal (OM3), posterior left ventricular branch (PLVB), posterior descending artery (PDA) and acute marginal (AM) artery. PDA had diffuse disease and required endarterectomy. Rest of the operation was completed in usual fashion. Total operating time was 12 h. Patient had uneventful recovery. Postoperative creatinine phosphokinase-MB fraction (CPK-MB) measurement did not reveal any significant rise. He was discharged on 7th postoperative day.

During regular follow-up patient did not complain of any angina. Function of both hands was normal. Postoperative left ventricular function was normal. Postoperative CT angiography after 2 years revealed 8 patent grafts (Fig. 2) with good distal flow including PDA (which had endarterectomy) but ninth bypass graft to acute marginal artery was blocked.

### 4. Discussion

OPCAB techniques continue to evolve. The advantage of anaortic OPCAB is near zero incidence of stroke.<sup>1–6</sup> Higher stroke rate is the main drawback of coronary artery bypass grafting (CABG) when compared to percutaneous coronary intervention (PCI) in all recent trials. Moreover, internal mammary artery and radial artery grafts have superior patency rate compared to vein graft.<sup>7</sup> So anaortic total arterial OPCAB can be considered the best form of surgical revascularization.

OPCAB is often criticized for incomplete revascularization, poor long-term graft patency rate and technical difficulty.<sup>8</sup> It is often argued still, motionless heart is an essential prerequisite to perform good quality distal anastomosis when distal coronary arteries are small and diffusely diseased. Moreover, sequential internal mammary artery grafting of small diffusely diseased distal coronary using OPCAB is considered

Download English Version:

<https://daneshyari.com/en/article/2927469>

Download Persian Version:

<https://daneshyari.com/article/2927469>

[Daneshyari.com](https://daneshyari.com)