

Available online at www.sciencedirect.com

ScienceDirect

journal homepage: www.elsevier.com/locate/IPEJ

CrossMark

A case of ‘tachy-brady syndrome’: What is the mechanism?

Narayanan Namboodiri*, Shomu Bohora, Valaparambil K. Ajitkumar, Jaganmohan A. Tharakan

Sree Chitra Tirunal Institute for Medical Sciences and Technology, Thiruvananthapuram, India

ARTICLE INFO

Article history:

Available online 10 March 2016

Keywords:

Tachycardiomyopathy
Sinus node dysfunction
Radiofrequency ablation
Supraventricular tachycardia

ABSTRACT

A young male presented with incessant narrow QRS tachycardia and left ventricular dysfunction. 24-Holter monitoring revealed multiple episodes of sustained and non-sustained episodes of tachycardia with prolonged sinus pauses at termination. The analysis of the electrocardiogram, followed by an invasive electrophysiological study, suggested an unusual mechanism for this tachy-brady syndrome.

Copyright © 2016, Indian Heart Rhythm Society. Production and hosting by Elsevier B.V.

This is an open access article under the CC BY-NC-ND license (<http://creativecommons.org/licenses/by-nc-nd/4.0/>).

1. Case presentation

An 18-year old male presented with recurrent palpitations associated with occasional presyncope for the preceding 3 months. Nonsustained episodes of narrow QRS tachycardia with sinus pauses at termination were noted on the electrocardiogram (ECG) (Fig. 1A & B). Holter monitoring showed sustained and nonsustained episodes of tachycardia, with a cumulative duration of 14 h in a 24-h recording, and intervening sinus pauses (Fig. 1C) lasting up to 4.5 s. His left ventricular ejection fraction was 35% at presentation.

During electrophysiological study, sinus cycle length was 734 ms with normal atrio-hisian (AH) and His-ventricular (HV) intervals. Atrial pacing till atrioventricular (AV) Wenckebach didn't reveal any preexcitation. No dual AV nodal physiology was seen. The clinical tachycardia was easily induced on

ventricular pacing. The termination and re-initiation of the tachycardia are shown in Fig. 2.

2. Discussion

The ECG in Fig. 1A and B show a narrow QRS long RP tachycardia with negative P waves in inferior leads. The episodes of this nonsustained tachycardia are initiated with sinus beats, and the second QRS complex of the tachyarrhythmia shows right bundle branch block morphology. The morphology and axis of the subsequent P waves (P') are different from the sinus beats. The short tachycardia episodes terminate with P' wave and are followed by sinus pauses. Occasionally, the isolated sinus beat is followed by a single P' wave, without continuing as tachycardia. The differential diagnosis of this long RP tachycardia includes atrial tachycardia (AT) originating from inferior

* Corresponding author. Department of Cardiology, Sree Chitra Tirunal Institute for Medical Sciences and Technology, Thiruvananthapuram, Kerala, 695011, India. Tel.: +91 9447223340; fax: +91 471 2446433.

E-mail address: knnamboodiri@gmail.com (N. Namboodiri).

Peer review under responsibility of Indian Heart Rhythm Society.

<http://dx.doi.org/10.1016/j.ipej.2016.03.001>

0972-6292/Copyright © 2016, Indian Heart Rhythm Society. Production and hosting by Elsevier B.V. This is an open access article under the CC BY-NC-ND license (<http://creativecommons.org/licenses/by-nc-nd/4.0/>).

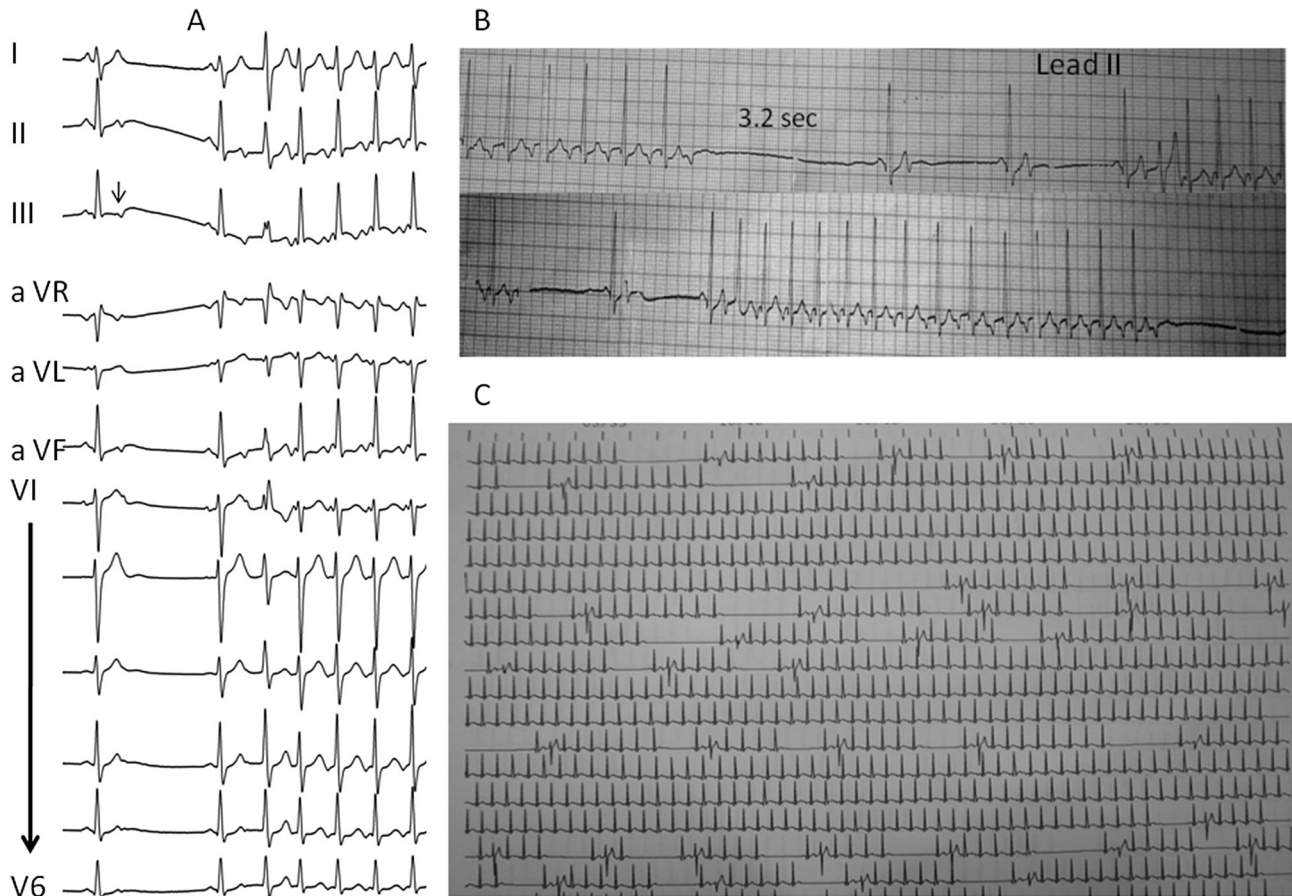


Fig. 1 – A) 12-lead ECG showing the long RP tachycardia initiated by a sinus beat. The first sinus beat is followed by a non-conducted atrial echo beat. B) Rhythm strips (lead II) showing the onset and termination of the nonsustained episodes of tachycardia. C) Holter showing episodes of tachycardia interspersed with sinus pauses.

atrium, AV nodal reentrant tachycardia (AVNRT) of fast-slow sub-form and persistent form of junctional reciprocating tachycardia (PJRT). During AT, the P waves of the initial and subsequent beats tend to be similar, unlike what is observed in this case. The fast-slow type of AVNRT is usually initiated following ventricular premature beat and the incessant nature is unusual. Orthodromic reentrant tachycardia using an accessory pathway (AP) with decremental retrograde conduction properties, i.e., PJRT can be initiated by sinus beat, and this tachyarrhythmia tends to be incessant. Termination on either antegrade or retrograde limb can occur in both reentrant mechanisms, but to terminate with a P' wave is unusual for AT.

The intracardiac tracing in Fig. 2 helps to confirm PJRT as the mechanism in this case. The initial 2 cycles of tachycardia in Fig. 1 have cycle length of 360 ms with the earliest atrial activity recorded with 'bracketing' at proximal coronary sinus (CS) bipole (CS 7-8). The tachycardia terminates following a paced beat from the right ventricular apex, timed 30 ms later than the His signal. The morphology of this paced complex suggests QRS fusion between the paced and tachycardia beat. Termination following a paced ventricular beat not conducted to atrium and resulting in QRS fusion suggests orthodromic AV reentry as the tachycardia mechanism. The prolonged local ventriculoatrial (VA) interval of 210 ms even

at the site of earliest retrograde atrial activation during the tachycardia suggests slow conduction through the AP. Immediately following its termination, the next sinus beat re-initiates the tachycardia. Notably, the first local V–V interval at CS 7-8 after the re-initiation is 370 ms, as compared to 360 ms during its stable phase. The increment of 10 ms is contributed by a delay in the AH interval by 60 ms (40–100 ms) despite the shortening of the conduction time across the AP by 40 ms (210–170 ms). Despite a delay in conduction down the His bundle, the anterograde impulse finds the right bundle in refractoriness, and conducts down the left bundle with an HV interval similar to that in other tachycardia beats. This functional block and its mitigation in the subsequent beats follows that the recovery period in the bundle branch is directly related to the previous RR interval. The conduction times through the pathway, as measured by the local VA interval in CS 7-8 bipole, showed progressive prolongation (170, 190 and 210 ms), in response to a shortening of the preceding local V–V intervals (720, 370 and 330 ms respectively). This shows a decremental nature of the conduction through the AP. The progressive reduction in the time interval of the retrograde impulses at the ventricular end of the AP during the re-initiation, related to the conduction delay in the AV node in the second beat, unmasked

Download English Version:

<https://daneshyari.com/en/article/2928366>

Download Persian Version:

<https://daneshyari.com/article/2928366>

[Daneshyari.com](https://daneshyari.com)