



## CASE REPORT

# Supraventricular tachycardia and syncope during pregnancy: A case for catheter ablation without fluoroscopy<sup>☆</sup>



Tiago Luiz Luz Leiria<sup>\*</sup>, Leonardo Martins Pires, Marcelo Lapa Kruse, Gustavo Glotz de Lima

*Serviço de Eletrofisiologia Cardíaca, Instituto de Cardiologia do Rio Grande do Sul, Fundação Universitária de Cardiologia do Rio Grande do Sul, Brazil*

Received 24 February 2014; accepted 10 July 2014

Available online 20 December 2014

### KEYWORDS

Pregnancy;  
Ablation;  
Supraventricular  
tachycardia

**Abstract** Arrhythmias during pregnancy pose a dilemma for the treating physician. Most antiarrhythmic drugs are classified as category C in the FDA labeling system during pregnancy. We describe the case of a pregnant woman who presented syncope due to drug-refractory supraventricular tachycardia who underwent catheter ablation without the use of fluoroscopy.

© 2014 Sociedade Portuguesa de Cardiologia. Published by Elsevier España, S.L.U. All rights reserved.

### PALAVRAS-CHAVE

Gestação;  
Ablação;  
Taquiarritmias

**Tratamento de taquicardia supraventricular sincopal durante a gestação sem uso de raios-X: relato de caso**

**Resumo** As arritmias na gestação geram um dilema para o médico que assiste o paciente. A maioria das drogas antiarrítmicas possuem indicação classe C durante a gestação. Aqui fazemos o relato de mulher na gestação que apresentou TSV, sincopal, refratária ao tratamento ao qual foi submetida a ablação por cateter sem o uso de fluoroscopia.

© 2014 Sociedade Portuguesa de Cardiologia. Publicado por Elsevier España, S.L.U. Todos os direitos reservados.

<sup>☆</sup> Please cite this article as: Leiria TLL, Pires LM, Kruse ML, de Lima GG. Tratamento de taquicardia supraventricular sincopal durante a gestação sem uso de raios-X: relato de caso. Rev Port Cardiol. 2014;33:805.e1–805.e5.

<sup>\*</sup> Corresponding author.

E-mail address: [drleiria@gmail.com](mailto:drleiria@gmail.com) (T.L.L. Leiria).

## Introduction

Sustained arrhythmias are relatively rare during pregnancy (2–3/1000 pregnant women investigated for palpitations); when present, supraventricular forms are the most common.<sup>1</sup> Paroxysmal supraventricular tachycardia (SVT) presents a high rate of recurrence in pregnancy (20% in those with a history of tachyarrhythmia). In some cases, due to the physiological changes resulting from pregnancy, including increased cardiac output and reduced vascular resistance, SVT may be poorly tolerated.<sup>1</sup>

Arrhythmias during pregnancy pose a dilemma for the treating physician. Most antiarrhythmic drugs are classified as category C in the US Food and Drug Administration (FDA) labeling system during pregnancy, with the exception of sotalol (category B).<sup>2</sup> All category C drugs cross the placental barrier and can have adverse effects on the fetus. Catheter ablation is accordingly the procedure of choice for drug-refractory, poorly tolerated SVT in pregnant women.<sup>3</sup> However, catheters are normally visualized inside the heart by the use of ionizing radiation (X-rays), which is teratogenic and has a cumulative effect. Exposure during an electrophysiological study is approximately 25 mGy/min, resulting in a mean total exposure of 0.07 Gy.<sup>4,5</sup> Doses higher than 0.10–0.20 Gy are associated with teratogenic effects; this figure is close to that used in one hour of fluoroscopy.<sup>5</sup>

We describe the case of a pregnant woman who presented syncope due to drug-refractory SVT who underwent catheter ablation without the use of fluoroscopy.

## Case report

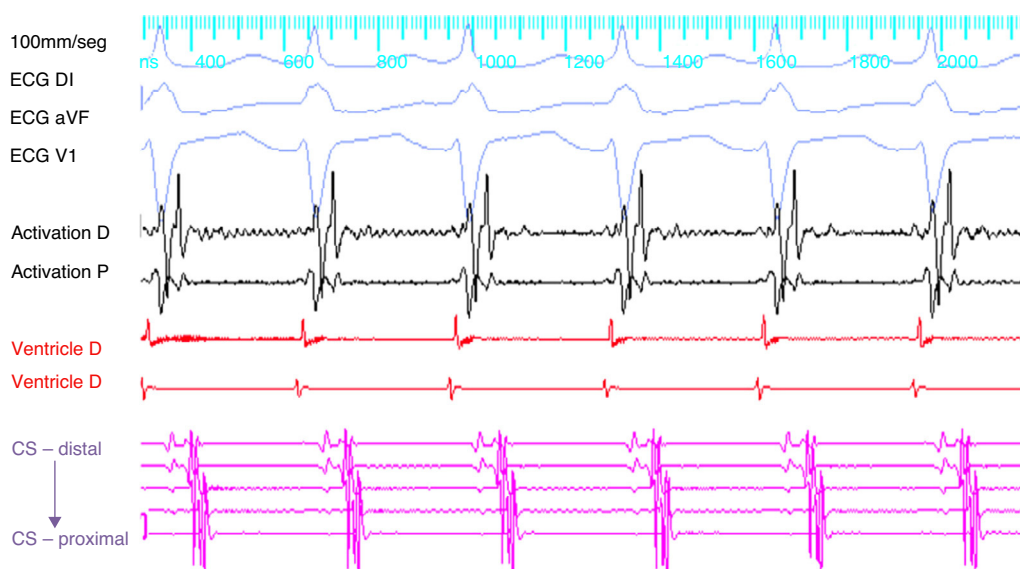
A 33-year-old woman, gravida 4, 26 weeks pregnant, with no known history of disease or family history of sudden death, was transferred to our department after being admitted for syncope due to paroxysmal SVT. She reported taking

propranolol and sotalol prescribed during pregnancy following the first episode of SVT. Because of the severity of the clinical presentation and symptoms refractory to therapy, including class III antiarrhythmics, it was decided to treat her arrhythmia invasively. After discussing the risks and benefits with the patient, a zero-radiation approach was adopted.

## Procedure

The patient arrived at the electrophysiology laboratory in a fasting state and was sedated with propofol and fentanyl. The baseline ECG showed sinus rhythm with normal atrioventricular (AV) conduction and no ventricular pre-excitation. Fetal echocardiography was performed during the procedure for real-time monitoring of the effects of sedation and of the tachyarrhythmia on fetal dynamics. The introducer sheaths were introduced via three venous punctures and the EnSite NavX three-dimensional mapping system (St. Jude Medical, USA) was used to advance the catheters from the femoral region to the right atrium. Using only the three-dimensional mapping system, the coronary sinus and the right ventricle were catheterized and another catheter was positioned in the region of the His bundle, which was tagged with several catheter shadows to protect the AV node. Programmed atrial stimulation at a cycle length of 600 ms and extrastimuli at 340 ms reproducibly induced SVT with eccentric retrograde atrial activation that was earlier at the distal electrodes of the coronary sinus catheter (Figure 1). A ventricular extrastimulus in the refractory His bundle reproducibly terminated the SVT without atrial activity, demonstrating that it was an AV reentrant tachycardia via a left lateral accessory pathway.

A 4-mm ablation catheter was then introduced via the femoral artery and advanced to the left ventricle under the guidance of the EnSite NavX system (Figure 2). It was not necessary to map the geometry of the left ventricle since



**Figure 1** Paroxysmal supraventricular tachycardia with eccentric retrograde activation and atrial activation earlier at the distal electrodes of the coronary sinus. At this point the ablation catheter is in the left ventricle. CS: coronary sinus.

Download English Version:

<https://daneshyari.com/en/article/3020150>

Download Persian Version:

<https://daneshyari.com/article/3020150>

[Daneshyari.com](https://daneshyari.com)