

CASE REPORT

New less invasive ventricular reconstruction technique in the treatment of ischemic heart failure



Rita Faria^{a,*}, Bruno Melica^a, Gustavo Pires-Morais^a, Alberto Rodrigues^a,
José Ribeiro^a, Miguel Guerra^b, Vasco Gama^a, Luís Vouga^b

^a Serviço de Cardiologia, Centro Hospitalar de Vila Nova de Gaia/Espinho, Vila Nova de Gaia, Portugal

^b Serviço de Cirurgia Cardiorádica, Centro Hospitalar de Vila Nova de Gaia/Espinho, Vila Nova de Gaia, Portugal

Received 19 October 2013; accepted 26 February 2014

Available online 8 August 2014

KEYWORDS

Ischemic cardiomyopathy;
Heart failure;
Surgical ventricular reconstruction;
Off-pump surgery

Abstract Ischemic cardiomyopathy is the leading cause of heart failure. In patients with left ventricular (LV) dilatation, low ejection fraction, and transmural scar in an anteroseptal distribution, surgical ventricular reconstruction (SVR) is a treatment option.

We describe our first experience with the Less Invasive Ventricular Enhancement (LIVE) technique using the Revivent™ system (Bioventrix Inc., San Ramon, CA), in the treatment of a large anteroapical aneurysm.

© 2013 Sociedade Portuguesa de Cardiologia. Published by Elsevier España, S.L.U. All rights reserved.

PALAVRAS-CHAVE

Cardiomiopatia isquémica;
Insuficiência cardíaca;
Reconstrução ventricular esquerda;
Cirurgia sem circulação extracorporeal

Nova técnica menos invasiva de reconstrução ventricular no tratamento de insuficiência cardíaca isquémica

Resumo A cardiomiopatia isquémica é a principal causa de insuficiência cardíaca. A cirurgia de reconstrução ventricular é uma opção terapêutica em doentes com dilatação e disfunção sistólica do ventrículo esquerdo e cicatriz de enfarte transmural da parede anterior e septo.

Os autores pretendem descrever a sua experiência inicial com uma técnica menos invasiva de reconstrução ventricular (*Less Invasive Ventricular Enhancement* [LIVE]) utilizando o sistema Revivent™ (Bioventrix Inc., San Ramon, CA, EUA), no tratamento de um volumoso aneurisma ântero-apical.

© 2013 Sociedade Portuguesa de Cardiologia. Publicado por Elsevier España, S.L.U. Todos os direitos reservados.

* Corresponding author.

E-mail address: rita.d.faria@gmail.com (R. Faria).

Introduction

Surgical ventricular reconstruction (SVR) has become a surgical option for patients with severe ischemic heart failure. SVR effectively reduces LV volume and wall tension and is known to improve neurohormonal status.¹⁻³ However, its impact on mortality, functional capacity and quality of life is still controversial.⁴

Recently, a new technique, Less Invasive Ventricular Enhancement (LIVE), has been developed using the Revivent™ Myocardial Anchoring System (Bioventrix Inc., San Ramon, CA). In this technique, plication and exclusion of the aneurysm is achieved using anchors which are implanted into the scarred portion of the heart, rendering the LV smaller. Conceptually, the final configuration in SVR can be achieved by placing these implants. However, Revivent™ achieves this outcome without an LV incision and thus without the need for cardiopulmonary bypass (CPB).

The system consists of four components: a catheter-based delivery system, a force gauge to control the anchors when apposing the LV walls, the implantable anchor

elements, and a retrieval system (to remove the implants if necessary). The implantable components consist of polyester fabric-covered titanium anchor pairs: one hinged internal anchor that passes through a low-profile catheter to the right side of the septum and one locking external anchor deployed in an LV epicardial position (Figure 1A and B).

Case report

We report the case of a 41-year-old Caucasian male evaluated in our center for severe ischemic cardiomyopathy. The patient had suffered a transmural anterior myocardial infarction six months earlier for which he sought no medical help, and was in NYHA class II despite optimal heart failure therapy for at least 90 days (160 days). His past history included smoking, hypertension, dyslipidemia and type II diabetes. He was evaluated after this event for post-infarction angina. Catheterization showed occlusion of the proximal left anterior descending coronary artery without additional lesions.

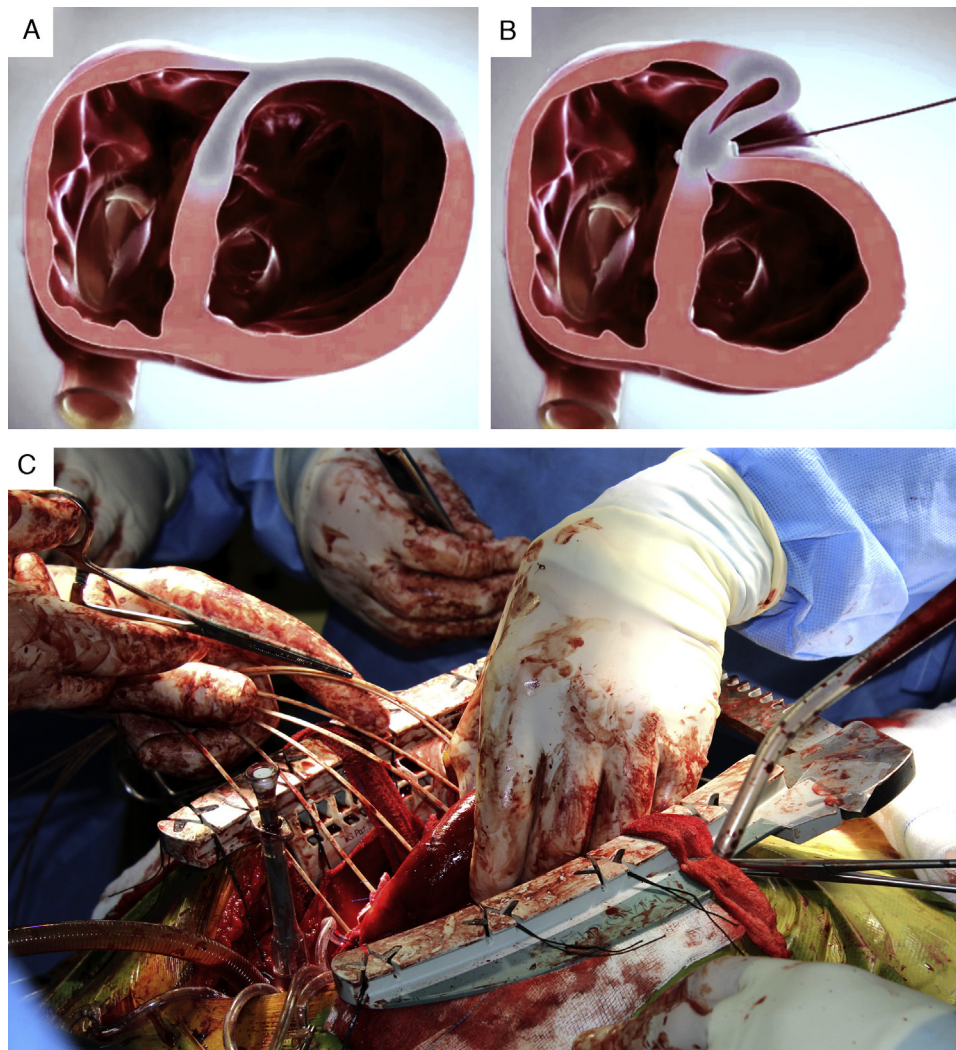


Figure 1 (A and B) LIVE technique, consisting of plication of the LV scar through a series of epicardially delivered anchor pairs that pull the LV free wall to the septum; (C) intraoperative image of plication of the large anteroapical aneurysm.

Download English Version:

<https://daneshyari.com/en/article/3020396>

Download Persian Version:

<https://daneshyari.com/article/3020396>

[Daneshyari.com](https://daneshyari.com)