

HOSTED BY



ELSEVIER

Available online at www.sciencedirect.com

ScienceDirect

www.elsevier.com/locate/sss

CrossMark

Case Report

Treatment of obstructive sleep apnea with mandibular advancement appliance over prostheses: A case report

Thais Moura Guimarães, Sâmia Colen, Paulo Afonso Cunali, Rowdley Rossi, Cibele Dal-Fabbro, Otávio Ferraz, Sergio Tufik, Lia Bittencourt*

Departamento de Psicobiologia, Disciplina de Medicina e Biologia do Sono, Universidade Federal de São Paulo, São Paulo, SP, Brasil

ARTICLE INFO

Article history:

Received 5 May 2015

Received in revised form

25 May 2015

Accepted 27 May 2015

Available online 11 June 2015

Keywords:

Mandibular advancement device

Prosthesis

ABSTRACT

Treatment with a mandibular advancement device (MAD) is recommended for mild obstructive sleep apnea (OSA), primary snoring and as a secondary option for Continuous Positive Airway Pressure, because it has better adherence and acceptance. However, edentulous patients do not have supports to hold the MAD. This study aimed to present a possible to OSA treatment with MAD in over complete upper and partial lower dentures. The patient, a 38-year-old female with mild OSA, was treated with a MAD. The respiratory parameter, such as apnea–hypopnea index, arousal index and oxyhemoglobin saturation was improved after treatment.

© 2015 Brazilian Association of Sleep. Production and Hosting by Elsevier B.V. This is an open access article under the CC BY-NC-ND license (<http://creativecommons.org/licenses/by-nc-nd/4.0/>).

1. Introduction

Obstructive Sleep Apnea (OSA) is a respiratory sleep disorder characterized by partial and/or complete obstruction of the upper airway [1]. OSA is highly prevalent, affecting up to 32.8% of the adult population in the São Paulo city [2].

The most common treatments for OSA include Continuous Positive Airway Pressure (CPAP) and oral appliances (OA). CPAP is used as the first option in severe OSA because it normalizes respiratory parameters [3]. However, oral appliances are recommended for milder cases, such as primary

snoring and mild OSA, or as a secondary treatment for CPAP or alternative treatment in CPAP failures [4].

OAs can be divided into two groups: mandibular advancement devices (MADs), which are attached to the teeth and move the mandible anteriorly, and tongue retaining devices, which use suction to position the tongue anteriorly inside a bulb [5]. MADs have higher success and compliance rates than tongue retaining devices [5] and have more scientific support for their use [6].

MADs are anchored to the teeth; therefore, their efficacy is directly related to the retention of the device to the dental

*Correspondence to: Departamento de Psicobiologia, Universidade Federal de São Paulo, Napoleão de Barros Street, 925, Vila Clementino, CEP 04021-002, Sao Paulo, Brasil. Tel.: +55 11 55725092.

E-mail address: lia@liabittencourt.com.br (L. Bittencourt).

Peer review under responsibility of Brazilian Association of Sleep.

arches [7]. Contraindications for treatment with these appliances include oral conditions with less than 10 teeth per arch [4], because this condition leads to lower retention and consequently failure of the treatment.

Importantly, Brazil has a large number of lost teeth and edentulous people [8,9], and this population is contraindicated for MAD use due to total and/or partial tooth loss. This case report contains an alternative treatment using a MAD constructed on a complete upper and partial lower prosthesis in a patient with mild OSA.

2. Case report

Patient NPDS, a 38-year-old female, was referred to the AFIP Dental Sleep Clinic with a diagnosis of mild OSA (AHI=12.5). During anamnesis, the patient reported gagging and interrupted breathing during sleep. She complained of agitated sleep, tiredness after waking, and excessive daytime sleepiness and the Epworth Sleepiness Scale (ESS) score was 8. Her main complaint was loud snoring.

The full night polysomnography was performed using a digital system (EMBLA (R) S7000, Embla System, Inc., Broomfield, CO., USA) and according to Academy American Manual (2007) [10]. The scoring of hypopnea events was made according to the alternative rules [10].

During a clinical examination, the patient showed a body mass index (BMI) of 29.8 kg/m² and neck circumference of 38 cm. The oral examination showed complete upper denture, and a partial lower prosthesis constructed eight months before. The seven remaining teeth were a good periodontal condition and did not have caries. The alveolar ridge was good bone support and had a healthy aspect. The anchoring and stability of the prosthesis were evaluated and was satisfactory to do anchoring and stability of the MAD.

The patient was informed that the treatment would be a therapeutic trial, and there was a possibility that the treatment would fail. As the amount of force that the device would apply to the prosthesis was unknown we did not have sure if the MAD would move these prosthesis. Fig. 1 shows the oral condition of the patient with and without the prosthesis installed.

We planned to confection the PM positioner appliance that it is a custom-made titratable MAD and does not have laterality, which could produce less rocking force on the prosthesis, leading to better stability.

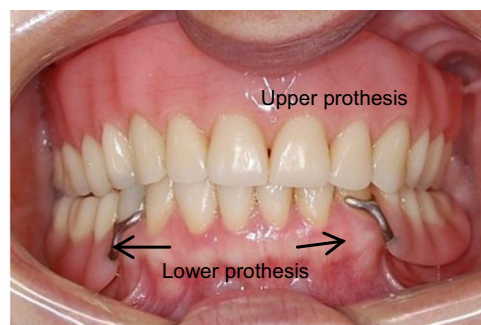
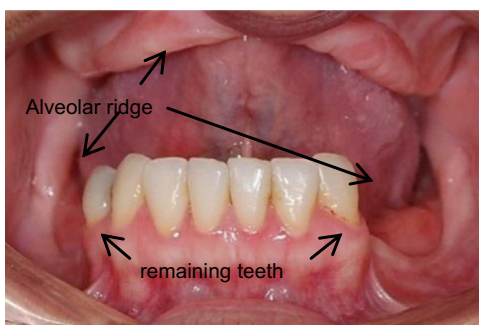

Fig. 1 – The intraoral condition with and without the prosthesis.

Her prior dental history was requested, including photographs, panoramic x-rays, and lateral telerradiography. Next, molds were taken with the prosthesis in the mouth, and register the protrusion measured using a George Gauge. The maximum protrusion (from the maximum posterior contact to the maximum tolerable protrusion) was 7 mm. The appliance was set to 50% when it was installed and advanced by 1 mm per by week until the snoring complaint was over. The advanced was finish at 100% of maximum tolerable protrusion, at 7 mm. She was submitted to a polysomnography after 5 months with a maximum tolerable protrusion position. Fig. 2 shows the patient with the MAD appliance installed.

The treatment resulted in improvement on subjective sleepiness, ESS score was 4, on fatigue report and subjective and objective quality of sleep. On the polysomnography parameters, the treatment decrease a sleep latency, REM latency, arousal index, AHI and increased of percentage of REM and N3 (Table 1).

3. Discussion

The present study reports a successful treatment using a MAD constructed on a complete upper and partial lower prosthesis. This report is important because it broadens the potential uses of MAD appliances.

Treatment of edentulous patients with mild OSA is normally limited to CPAP or tongue retainers, which have low compliance [5,11]. The prevalence of OSA increases with age [2], and the prevalence of edentulous individuals is also high in the elderly population [8]. Using a MAD on a prosthesis is an alternative, as it is a low-cost treatment and does not require a power source [4].

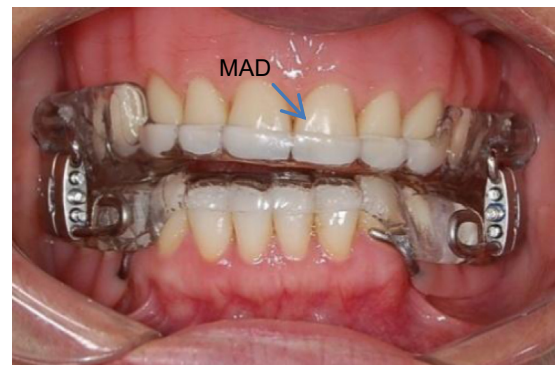

Fig. 2 – Patient with dentures and MAD installed.

Download English Version:

<https://daneshyari.com/en/article/3026602>

Download Persian Version:

<https://daneshyari.com/article/3026602>

[Daneshyari.com](https://daneshyari.com)