

Case Report

Ictal central apnea and bradycardia in temporal lobe epilepsy complicated by obstructive sleep apnea syndrome



Yoko Nishimura ^{a,*}, Yoshiaki Saito ^a, Noriko Kondo ^{a,b}, Eriko Matsuda ^c, Misato Fujiyama ^c, Rie Morizane ^c, Yoshihiro Maegaki ^a

^a Division of Child Neurology, Institute of Neurological Science, Faculty of Medicine, Tottori University, Japan

^b Division of Child and Adolescent Psychiatry, Tokyo Metropolitan Children's Medical Center, Japan

^c Division of Otolaryngology, Head and Neck Surgery, Faculty of Medicine, Tottori University, Japan

ARTICLE INFO

Article history:

Received 10 May 2015

Accepted 18 May 2015

Available online 23 July 2015

Keywords:

Ictal epileptic apnea

Bradycardia

Temporal lobe

SUDEP

Obstructive sleep apnea

Polysomnography

ABSTRACT

We describe the case of a 12-year-old boy who developed temporal lobe epilepsy (TLE) with daily complex partial seizures (CPS) and monthly generalized seizures. Moreover, he frequently snored while asleep since early childhood. Polysomnography (PSG) revealed severe obstructive sleep apnea with apnea–hypopnea index (AHI) of 37.8/h. Video-PSG with simultaneous electroencephalography (EEG) recording captured two ictal apneic episodes during sleep, without any motor manifestations. The onset of rhythmic theta activity in the midtemporal area on EEG was preceded by the onset of apnea by several seconds and disappeared soon after cessation of central apnea. One episode was accompanied by ictal bradycardia of <48 beats/min which persisted for 50 s beyond the end of epileptic activity. After treatment with carbamazepine and tonsillectomy/adenoidectomy, the seizures were well controlled and AHI decreased to 2.5/h. Paroxysmal discharges also disappeared during this time. Uncontrolled TLE complicated by sleep apnea should be evaluated for the presence of ictal central apnea/bradycardia.

© 2015 The Authors. Published by Elsevier Inc. This is an open access article under the CC BY-NC-ND license (<http://creativecommons.org/licenses/by-nc-nd/4.0/>).

1. Introduction

Ictal apnea and/or ictal bradycardia has been well recognized as a part of the autonomic manifestation in epileptic seizures and are most commonly observed in temporal lobe epilepsy (TLE). Ictal apnea and ictal bradycardia can be the sole manifestation of epileptic seizures not accompanied by any motor phenomena [1,2]. Meanwhile, prolonged periictal apnea and bradycardia are both regarded as risk factors for sudden unexpected death in epilepsy (SUDEP) [3]. In another aspect regarding sleep apnea and epilepsy, obstructive sleep apnea (OSA) is common in refractory epilepsies, possibly due to sleep fragmentation that deprives individuals of effective sleep and increases drowsy state, which results in exacerbation of epileptic seizures [4].

We herein describe the case of a 12-year-old boy with new-onset TLE, in whom ictal central apnea with bradycardia was identified

incidentally by overnight polysomnography (PSG), for the evaluation of coexisting obstructive sleep apnea.

2. Case report (Fig. 1)

The patient was a boy with a history of meconium aspiration syndrome at full-term birth, necessitating admission to the neonatal care unit for three weeks. Otherwise, he showed normal development and was healthy until the age of 12 years when he developed several types of seizures. Initially, he developed daily episodes of indescribable feeling and weakness, lasting for 10–20 s upon awakening. He also experienced shorter episodes of motion loss during wakefulness, a state in which he could see and hear but could not understand the contents of a conversation; this was often provoked by certain rustling or clattering sounds. Two months later, secondarily generalized convulsions lasting for 2–3 min appeared during sleep and were accompanied by facial twitch and drooling. Routine EEG revealed focal spikes at the F8 area, rarely propagating to the F4 area. Magnetic resonance imaging showed unremarkable findings.

The boy had been intermittently snoring since early childhood, had become exacerbated recently and resulted in daytime sleepiness and mouth breathing. Bilateral tonsillar hypertrophy was noted on examination. Overnight PSG before initiation of antiepileptic medication revealed a considerable degree of obstructive respiratory disturbance

Abbreviations: AHI, apnea–hypopnea index; OSA, obstructive sleep apnea; PAP, positive airway pressure; PSG, polysomnography; SUDEP, sudden unexpected death in epilepsy; TLE, temporal lobe epilepsy.

* Corresponding author at: Division of Child Neurology, Institute of Neurological Sciences, Tottori University, Faculty of Medicine, 36-1 Nishi-cho, Yonago 683-8504, Japan. Tel.: +81 859 38 6771; fax: +81 859 38 6779.

E-mail address: yokon77@hotmail.com (Y. Nishimura).

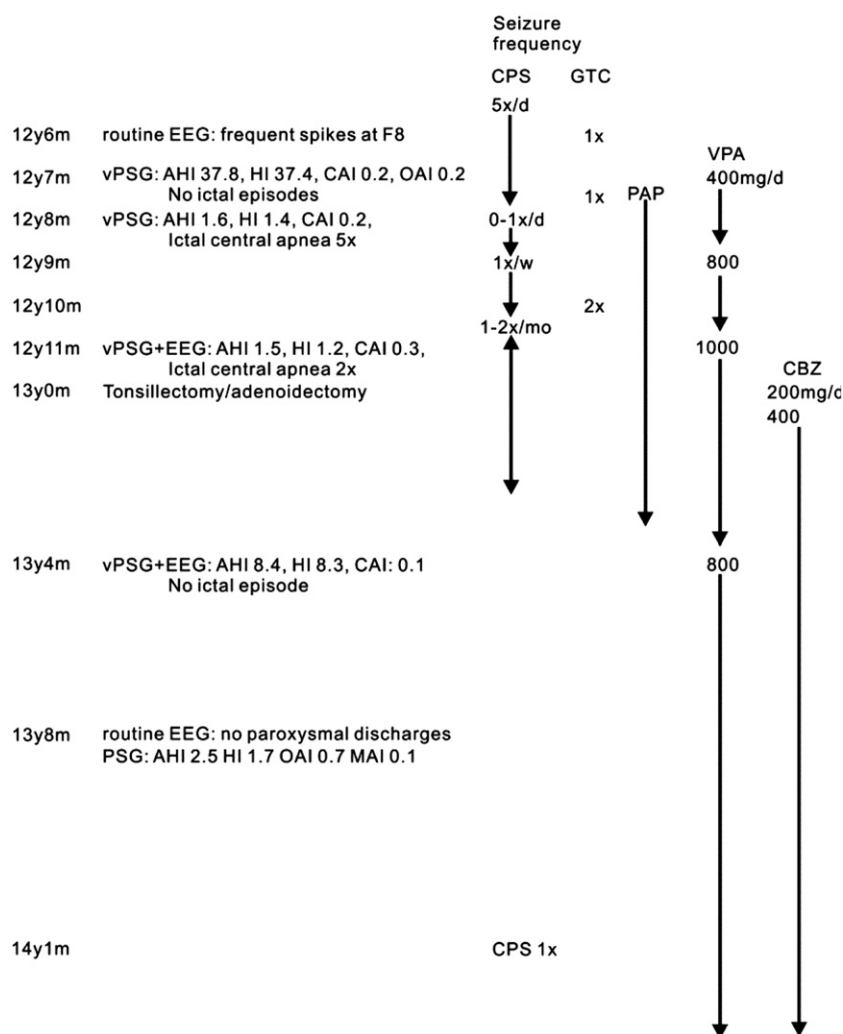


Fig. 1. Clinical course of the patient. AHI: apnea–hypopnea index, CAI: central apnea index, CBZ: carbamazepine, CPS: complex partial seizures, EEG: electroencephalography, HI: hypopnea index, MAI: mixed apnea index, PAP: positive airway pressure, OAI: obstructive apnea index, VPA: valproate, vPSG: video-polysomnography. Each apneic event was identified based on the criteria of the American Academy of Sleep Medicine.

with an apnea–hypopnea index (AHI) of 37.8/h (normal < 5.0) (Fig. 2A). Oxygen saturation from the peripheral artery (SpO₂) often fell to 90–92%, accompanied by marked retractive breathing. Second overnight PSG after initiation of positive airway pressure (PAP) therapy revealed an improved AHI of 1.6. In addition, five episodes of ictal central apnea for 17–30 s were captured, accompanied by rhythmic theta activity over the frontal and central areas. Electroencephalography electrodes over temporal regions were not included in this PSG. Valproate sodium was initiated; however, weekly seizures persisted. Three months later, PSG with EEG recording, including temporal lobe electrodes, revealed two episodes of ictal central apnea (Fig. 2B). During these events, recruiting 5- to 6-Hz theta activity emerged at the T4, T6, and F8 areas and then propagated to the contralateral hemisphere. Onset of these EEG activities was preceded by 5–10 s of apnea onset.

Among a total of seven ictal central apneas, mean duration was 23.9 ± 5.7 s (range: 17.5–31). In all occasions, SpO₂ was decreased by $5.3 \pm 2.1\%$ (range: 2–9); on six occasions, heart rate was also decreased by 6.8 ± 2.2 /min (range: 3–9) with a mean duration of 21.3 ± 15.2 s (range: 5–50). In most cases, SpO₂ and heart rate recovered promptly after termination of rhythmic discharges. However, on one occasion, bradycardia of 46–48 beats/min persisted for 50 s after termination of ictal activity and epileptic apnea (Fig. 2B). Ictal motor manifestation was not observed on surface electromyography of the mentalis and tibialis anterior muscles, as well as in the video recording of these episodes. Carbamazepine was added to the regimen.

Positive airway pressure therapy was terminated three months after tonsillectomy/adenoidectomy. Repeat PSG revealed an AHI of 8.4 and 2.5 during the follow-up period. Apneic and other types of epileptic

Fig. 2. Polysomnography (PSG) and EEG during apneic events. A: PSG during an episode of obstructive apnea. Note that thermistor flow (T-flow) and pressure flow (P-flow) are attenuated, accompanied by paradoxical thoracic/abdominal movements (bar). The top 6 channels represent EEG with monopolar montage (F3–A2, F4–A1, C3–A2, C4–A1, O1–A2, O2–A1). Channel 7: chin electromyogram; channel 8: nasal thermistor airflow; channel 9: nasal pressure airflow; channels 10 and 11: thoracic and abdominal movements recorded with plethysmography; channel 12: electrocardiography; channel 13: oxygen saturation of peripheral artery (SpO₂); channel 14: heart rate; channels 15 and 16: surface electromyography of left and right tibialis anterior muscles. B: PSG combined with EEG recording during ictal central apnea under positive airway pressure (PAP) therapy. Sudden cessation of mask flow (bar over the tracing) and thoracic/abdominal movements is noted, without any contraction of the mentalis/tibialis anterior muscles on surface electromyography. Seven seconds after the initiation of central apnea, recruiting 5- to 6-Hz theta activity appeared at the T4 area and subsequently at the T6 and F8 areas, then propagated to the contralateral hemisphere. SpO₂ decreased from 98% to 96%, and heart rate declined from 55/min to 46/min. On EEG, monopolar montage with reference to averaged electrical potentials is used for better illustration of the onset of rhythmic activity at the T4 area. Thermistor and pressure monitoring was not applicable in the situation with PAP treatment due to continuous airflow from the compressor. Instead, mask airflow (channel 8) was used for monitoring naso-oral airflow.

Download English Version:

<https://daneshyari.com/en/article/3051746>

Download Persian Version:

<https://daneshyari.com/article/3051746>

[Daneshyari.com](https://daneshyari.com)