

## Case Report

# Anterior corpus callosotomy in multistep invasive monitoring and surgery for atonic seizures<sup>☆,☆☆</sup>



Van Tri Truong, Tania Tayah, Alain Bouthillier, Dang Khoa Nguyen<sup>\*</sup>

Division of Neurology, Notre-Dame Hospital, Centre Hospitalier Université de Montréal, Montreal, Canada

## ARTICLE INFO

## Article history:

Received 2 December 2013

Accepted 3 December 2013

Available online 4 January 2014

## Keywords:

Anterior corpus callosotomy

Focal atonic seizures

Multistep invasive monitoring

Epilepsy surgery

Mirror focus

## ABSTRACT

Identifying the epileptogenic zone (EZ) in patients with refractory nonlesional frontal lobe epilepsy is frequently challenging. Intracranial EEG (icEEG) recordings are often required to better delineate the EZ, but the presence of an extensive network of connections allowing rapid ictal spread may result in bilateral homologous regional (or extremely diffuse) electrical ictal patterns. Here, we report a case where callosotomy performed after a first nonlateralizing icEEG study allowed for adequate identification of the EZ. The patient, an 18-year-old left-handed woman with daily atonic spells, had synchronous interictal and ictal epileptic activity from both supplementary motor areas (SMAs) during icEEG. Anterior partial callosotomy localized the EZ to the right SMA, as seizures were no longer associated with mirror-image ictal activity over the left SMA. Right SMA resection led to seizure freedom (follow-up of 23 months). This case exemplifies how a partial callosotomy followed by further icEEG recordings may adequately localize the EZ when initial icEEG recordings reveal bilateral synchronous focal or regional ictal activities.

© 2013 . Published by Elsevier Inc. This is an open access article under the CC BY-NC-ND license (<http://creativecommons.org/licenses/by-nc-nd/3.0/>).

## 1. Introduction

Identifying the epileptogenic zone (EZ) is often challenging [1,2] in patients with refractory nonlesional frontal lobe epilepsy. Reasons include the varied nonspecific clinical manifestations due to rapid spread of the epileptic activity to other regions through conduction pathways and the low spatiotemporal resolution of currently available noninvasive localization techniques [3,4]. Intracranial EEG (icEEG) recordings are frequently required to better delineate the EZ [5], but the presence of an extensive network of connections allowing rapid ictal spread may result in bilateral homologous regional (or extremely diffuse) electrical ictal patterns. A slow continuous spread of ictal activity is associated with significantly better surgical outcomes than a fast continuous spread [6]. Here, we report a case where callosotomy performed after a first nonlateralizing icEEG study allowed for the adequate identification of the EZ.

## 2. Case report

The patient is an 18-year-old left-handed woman of normal intellect who began experiencing seizures at 12 years of age. The spells were characterized by sudden flaccidity of the lower extremities, a sense of a loss of balance, and feeling as if a heavy weight was falling on her head followed by a sudden fall and the inability to stand up for 10 to 15 s. At this point, the patient claimed to be unable to move her extremities. If supine, she would report a sensation of continuously falling into the bed for 10–15 s. Video-EEG recording also revealed episodes of awakening with or without minimal motor movements or extension of upper or lower extremities. The episodes would recur an average of 10 times per day with a peak frequency of more than 100 per day. On two occasions since the episodes began, these spells evolved into generalized tonic–clonic convulsions. After 8 antiepileptic drugs failed to improve her seizures, a presurgical evaluation was performed.

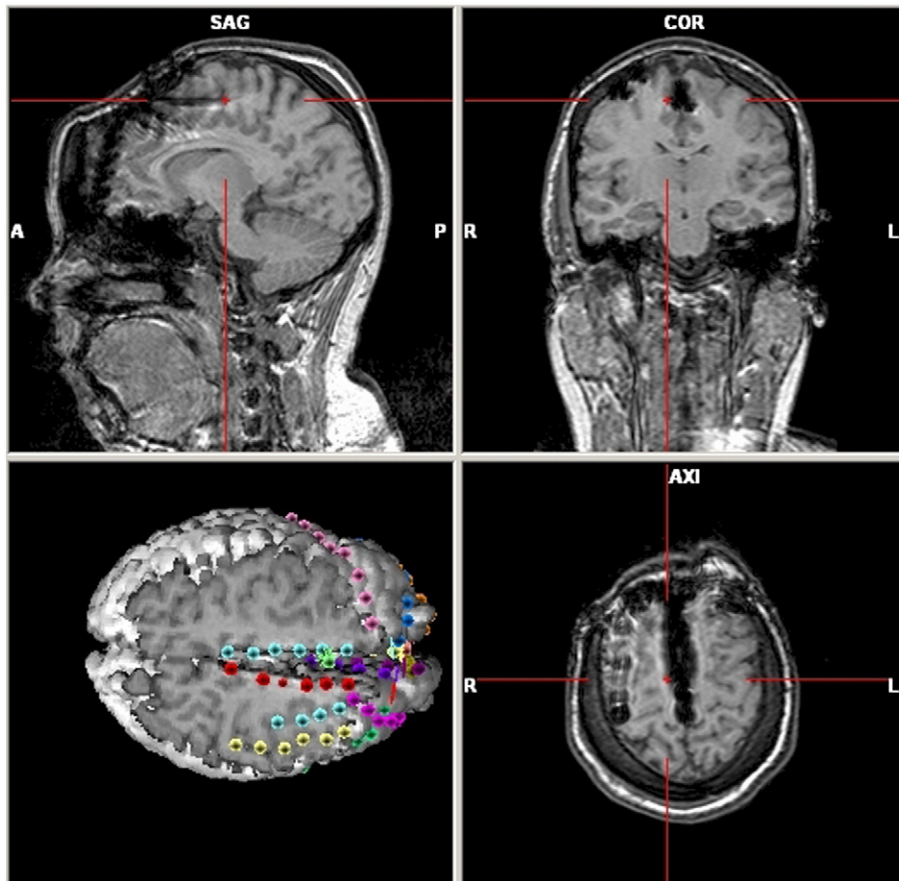
Her high-resolution brain 3-T MRI was normal. Despite a relatively early injection (15 s), the ictal SPECT showed multiple activation sites (bilateral temporal, orbitofrontal, and inferior frontal gyri). A second ictal SPECT showed a right mesial temporal activation. 18F-fluorodeoxyglucose positron emission tomography scan was nonlocalizing. Electroencephalography-correlated functional magnetic resonance imaging revealed maximal bold activations in the right cingulate and right superior frontal gyri. Functional magnetic resonance imaging for language showed bilateral activation without clear lateralization. Magnetoencephalography supported a mesial frontal focus with medial and lateral sources in front of

<sup>☆</sup> This is an open-access article distributed under the terms of the Creative Commons Attribution-NonCommercial-No Derivative Works License, which permits non-commercial use, distribution, and reproduction in any medium, provided the original author and source are credited.

<sup>☆☆</sup> This work was not supported by a grant or otherwise. It was previously presented at the AES annual meeting, December 2011.

<sup>\*</sup> Corresponding author at: Centre Hospitalier Université de Montréal (Hôpital Notre-Dame), 1560 Sherbrooke East, Montréal, Québec H2L 4M1, Canada.

E-mail address: [d.nguyen@umontreal.ca](mailto:d.nguyen@umontreal.ca) (D.K. Nguyen).



**Fig. 1.** 3D representation of the intracranial EEG study: a total of 16 subdural strip electrodes (90 contacts) were inserted to sample the medial, orbital, and dorsolateral aspects of the frontal lobe on both sides.

the central sulcus bilaterally. Neuropsychological testing showed no significant deficits. More than 30 seizures, mostly nocturnal, were captured during video-EEG associated with arousal from sleep and minimal motor movements of the trunk and extremities. The ictal EEG consisted of repetitive central spikes followed within 3 s by diffuse tonic low-voltage fast activity admixed with muscle artifacts.

We proceeded with an intracranial study that included the implantation of seven subdural strips on the left side and nine on the right side sampling the median frontal gyrus, cingulate gyrus, superior frontal gyrus, and supplementary motor area (SMA) bilaterally (Fig. 1).

### 3. Results

Numerous seizures were recorded during the invasive EEG study associated with an early ictal pattern of low-voltage fast activity over both SMAs. Interictal and ictal activity from the right SMA mirrored that of the left SMA and vice versa. Careful scrutiny of ictal manifestations or spreading epileptic activity was unhelpful in lateralizing the EZ (Fig. 2). The decision was eventually made to perform an anterior partial callosotomy and continue with additional invasive icEEG recordings (Fig. 3). This course of action allowed for the proper identification of the EZ to the anterior portion of the right SMA as seizures were no longer associated with mirror-image ictal activity over the left SMA. We did not observe any independent seizures from the left SMA. The patient then returned a third time to the operating room for the removal of the electrodes and resection of the right SMA (Fig. 4). Postoperatively, the patient presented with a left lower limb weakness recovering to near full strength within a month with physical therapy. The patient has had no seizures since surgery (Engel 1; FU = 23 months).

### 4. Discussion

In frontal lobe epilepsy, an extensive network of connections allows for rapid ictal spread. This may result in bilateral homologous regional (or extremely diffuse) electrical ictal patterns, making it difficult to delineate the EZ [7,8]. Clinically, this is reflected by a diversity of semiological features such as clonic activity, symmetric or asymmetric tonic posturing, complex gestural manifestations, or patterns of behavior [9]. We report here a patient with atonic seizures for whom callosotomy performed after a first nonlateralizing icEEG study allowed for the adequate identification of the EZ in the anterior portion of the right SMA. Although atonic seizures have traditionally been described as a clinical manifestation of generalized epilepsies [10], atonia has also been observed in patients with focal epilepsy [11]. The anterior portion of the supplementary motor area has been implicated in the pathophysiology of such focal atonic seizures as electrical stimulation of a 'supplementary negative motor area' can produce predominantly contralateral but also, to a lesser extent, ipsilateral atonia of predominantly limb muscles [12].

Few authors have previously noted that a partial anterior callosotomy followed by further icEEG recordings may be helpful in adequately localizing the EZ when icEEG recordings reveal bilateral synchronous focal or regional ictal activities. This was observed by Iwasaki et al. [13] with the lateralization of interictal spikes on scalp EEG after corpus callosotomy. Ono et al. reported using callosotomy in multistage epilepsy surgery [i.e., callosotomy (without prior icEEG) → icEEG → additional surgery] for children with mostly cryptogenic or symptomatic refractory epilepsy [14]. Similarly, Lin et al. suggested that the addition of invasive monitoring for children undergoing corpus callosotomy for medically refractory symptomatic generalized or

Download English Version:

<https://daneshyari.com/en/article/3051805>

Download Persian Version:

<https://daneshyari.com/article/3051805>

[Daneshyari.com](https://daneshyari.com)