

De novo basilar tip aneurysm. Case report and literature review

M.T.M. Suzuki; G.B. Aguiar; M. Jory; M.L.M. Conti and J.C.E. Veiga

Santa Casa Medical School. Department of Surgery. Division of Neurosurgery. São Paulo. Brazil.

Summary

The de novo aneurysms are the formation of new aneurysms in a location previously observed to be normal by a cerebral angiography or direct microsurgical exploration. In this report, we present a review of the theme and describe a case of a ruptured de novo basilar tip aneurysm in a patient previously treated with carotid occlusion for a giant intracavernous aneurysm and microsurgical clipping of contralateral posterior communicating artery aneurysm.

KEY WORDS. Basilar artery, De novo aneurysm, Subarachnoid hemorrhage

Aneurisma *de novo* del topo basilar. Descripción de un caso y revisión de la literatura

Resumen

Se llaman aneurismas de novo a la formación de aneurismas en una región previamente normal, observado y documentado por una angiografía cerebral o por la exploración microquirúrgica directa. En este trabajo, se presenta una revisión de la literatura sobre el tema y la descripción de un caso de ruptura de un aneurisma de novo en la arteria basilar en un paciente que previamente fue tratado con la oclusión de la arteria carótida para el tratamiento de un aneurisma gigante intracavernoso de un lado y el clipaje microquirúrgico de un aneurisma en la arteria comunicante posterior contralateral.

PALABRAS CLAVE. Arteria basilar. Aneurisma de novo. Hemorragia subaracnóidea.

Introduction

The definition of the de novo aneurysm is the forma-

tion of a new aneurysm in a location previously normal by an angiography or direct surgical exploration^{3,6,14,15}. To be considered a de novo aneurysm, it must be located at a site remote from the original aneurysm^{6,14,15}.

Despite advances in neuroimaging studies in the past two decades, de novo formations are still rare and underestimated among neurosurgeons and neuroradiologists. Even large trials, such the recent International Subarachnoid Aneurysm Trial (ISAT) do not estimate the real incidence of the de novo entity¹⁰. Misdiagnosis may be related to the lack of angiographic studies in patients labeled as cured after surgery or embolization of a previous aneurysm.

The most common location of the de novo aneurysm formation is the anterior circulation⁸. Posterior circulation de novo aneurysms, such as our case, are extremely rare and there is no data in the literature to indicate the actual number of cases reported until now.

We report on a case of basilar tip de novo aneurysm in an elderly woman previously treated with microsurgical clipping of a right posterior communicating artery aneurysm and carotid occlusion for a giant contralateral intracavernous aneurysm.

Case report

A 62-year-old woman experienced the worst headache of her life during rest, followed by a brief lost of consciousness. She was admitted to the emergency room awake, fully conscious, complaining of a holocranial headache. She had complete palsy of the III and VI nerves on the left side, as a cavernous sinus syndrome. There was no history of smoking, hypertension, previous neurological diseases or other associated risks for subarachnoid hemorrhage. The CT scan demonstrated a hyperdense lesion in the left carotid artery, resembling a giant intracavernous aneurysm. Cerebral angiography revealed a right carotid aneurysm in the communicating segment (Figure 1A) and a giant intracavernous carotid artery aneurysm in the left side

Abbreviations. CT: computed tomography. SAH: subarachnoid hemorrhage. MRI: magnetic resonance imaging.

Recibido: 28-09-10. Aceptado: 12-02-11

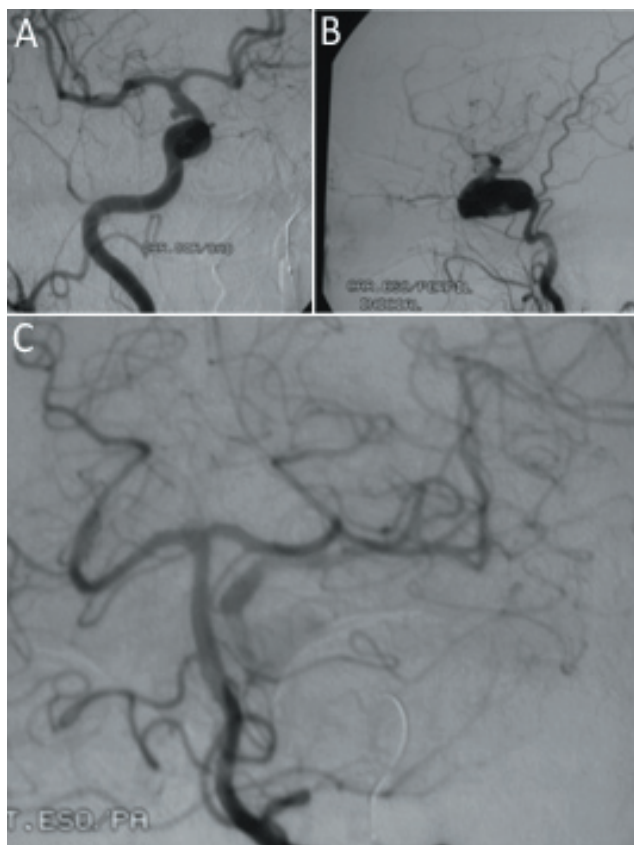


Figure 1. Angiography showing: A - Right PComA aneurysm and B - Left giant carotid aneurysms; C - Left vertebral selective angiography, during balloon occlusion test, showing no basilar aneurysms.

(Figure 1B). No abnormalities were observed in the posterior circulation after injection of contrast in the left vertebral artery (Figure 1C).

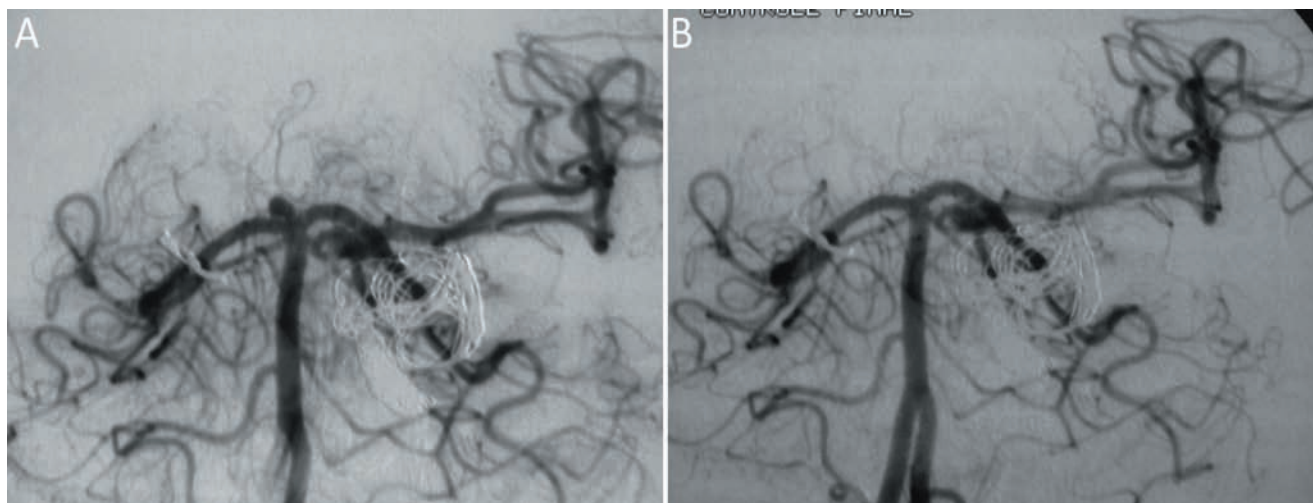


Figure 2. A - Angiography of the de novo tip basilar aneurysm. B - Angiography post-embolization of the de novo aneurysm

She was submitted to a right pterional craniotomy and microsurgical clipping of the right carotid aneurysm without any complications. Within 2 weeks, endovascular occlusion of left internal carotid artery was performed to treat the giant intracavernous aneurysm after a successful balloon occlusion test for carotid obliteration. Following the endovascular procedure, she was discharged without headache and with a remarkable improvement in the III nerve palsy.

Six months later, she experienced a new sudden event of pain, without loss of consciousness. No new deficits were added, the CT scan showed a subarachnoid hemorrhage and the angiography showed a de novo tip basilar aneurysm (Figure 2A). The patient was submitted to another endovascular procedure for the embolization of the de novo aneurysm and was discharged without new deficits (Figure 2B).

Discussion

De novo aneurysms were probably first mentioned by Grafi and Hamby in 1964^{4,8}. They reported on a case of a 39-year-old female with a recurrent subarachnoid hemorrhage due to a de novo aneurysm in the middle cerebral artery.

The development of a de novo aneurysm is rare, with a frequency of 0.84-1.8% per year⁸. Its formation is probably the result of the interplay between hemodynamic factors and structural weakness³. According to Matheus et al⁸, the pathophysiology of the de novo aneurysm formation involves changes in the vascular connective tissue, such as the presence of hemodynamic stress or formation of a defect in the arterial media or injury to the elastic lamina, corroborating its appearance in patients with multiple aneurysms, or after carotid occlusions, as described in this paper.

Download English Version:

<https://daneshyari.com/en/article/3071791>

Download Persian Version:

<https://daneshyari.com/article/3071791>

[Daneshyari.com](https://daneshyari.com)