



Microvascular Decompression of the Optic Nerve for Paroxysmal Phosphenes and Visual Field Deficit

Dirk De Ridder¹, Mary Jane Sime², Peter Taylor³, Tomas Menovsky⁴, Sven Vanneste^{1,5}

Key words

- Microvascular decompression
- Optic nerve
- Paroxysmal phosphenes
- Visual field deficit

Abbreviations and Acronyms

ICA: Internal carotid artery
MRI: Magnetic resonance imaging
MVD: Microvascular decompression
VEP: Visually evoked potential

From the ¹Departments of Surgical Sciences, Section of Neurosurgery, ²Ophthalmology, and ³Internal Medicine, Section of Neurophysiology, Dunedin School of Medicine, University of Otago, Dunedin, New Zealand; ⁴Department of Neurosurgery, University Hospital Antwerp, Belgium; and ⁵School of Behavioral and Brain Sciences, The University of Texas at Dallas, Dallas, Texas, USA

To whom correspondence should be addressed:
 Dirk De Ridder, M.D., Ph.D.
 [E-mail: dirk.deridder@otago.ac.nz]

Citation: *World Neurosurg.* (2016) 85:367.e5-367.e9.
<http://dx.doi.org/10.1016/j.wneu.2015.09.094>

Journal homepage: www.WORLDNEUROSURGERY.org

Available online: www.sciencedirect.com

1878-8750/\$ - see front matter © 2016 Elsevier Inc.
 All rights reserved.

INTRODUCTION

Microvascular compression syndromes are well-known entities in neurosurgery and are commonly treated by surgical microvascular decompression (MVD). Whereas vascular compression of the trigeminal nerve and facial nerve and its respective decompressions are mainstream treatments for trigeminal neuralgia and hemifacial spasm,¹⁻³ similar conditions affecting other cranial nerves have attracted less attention or are considered controversial.⁴ For most other cranial nerves, only case reports or small case series have been described. Microvascular compressions and surgical decompressions of the oculomotor,⁵ trochlear,⁶ abducens,⁷ vestibulocochlear,^{4,8} intermediate,⁹ glossopharyngeal,¹⁰ vagal,¹¹ accessory,¹² and hypoglossal¹³ nerve have been reported.

A recent addition is the surgical decompression of the optic nerve or chiasm for progressive visual field

■ **BACKGROUND:** Microvascular decompression surgery is standard neurosurgical practice for treating trigeminal neuralgia and hemifacial spasm. Most other cranial nerves have been decompressed for paroxysmal intermittent hyperactivity of the affected cranial nerve or in very long-standing compressions to treat cranial nerve hypofunctioning.

■ **CASE DESCRIPTION:** We describe a case of intermittent paroxysmal unilateral phosphenes (i.e., light flashes) associated with worsening visual field defects. Magnetic resonance imaging showed a sandwiched optic nerve/chiasm between an inferior compression of the internal carotid artery and a superior compression of the anterior communicating artery. The patient was successfully treated by microvascular decompression and anterior clinoidectomy plus optic canal unroofing.

■ **CONCLUSIONS:** This case report adds to the few previous case reports combining 2 previously described techniques (i.e., microvascular decompression and anterior clinoidectomy plus optic canal unroofing).

deficits,¹⁴⁻¹⁸ and 1 case report¹⁹ described phosphenes, or flashes of light, to be related to vascular compression of the optic nerve by an anterior communicating artery aneurysm. Whereas the 4 case reports caused by an ectatic carotid artery describe improvements after surgical decompression, 2 case reports from the era before magnetic resonance imaging (MRI) describing fusiform aneurysm compression failed to improve after surgical decompression.^{20,21}

Here, we describe a case of a patient presenting with unilateral flashes of light associated with a progressive visual field deficit treated by insertion of Teflon between the anterior communicating artery and the chiasm complemented by anterior clinoidectomy, transection of the falciform ligament, and unroofing of the optic canal.

CASE REPORT

A 73-year-old man presented at the eye clinic with photopsia at night or in the dark, with short paroxysms of white light, lasting less than a second, and only in his right eye. The flashes became more frequent but not longer lasting. The

flashes were present only at night or in darkness and were not triggered by sunlight or other visual stimuli. He had had long-standing (since childhood) esotropic strabismus, which caused intermittent diplopia when he was tired. Further ophthalmologic testing showed that unaided acuities were 4/6 on the right not improved by pinhole and 4/6 on the left improving to 4/4 with pinhole. He had a right-sided inferonasal field defect (Figure 1).

On clinical neurologic examination, no gross visual loss or field defect could be detected. He had strabismus but his eye movements were normal. Other cranial nerve, motor, and sensory examinations were normal, as were his reflexes.

An MRI scan showed an ectatic distal right internal carotid artery (ICA) abutting the undersurface of the right optic nerve and a compression of the optic chiasm by the anterior communicating artery (Figure 2). The right-sided optic nerve and chiasm thus appeared to be sandwiched between these 2 compressions.

Visually evoked potentials (VEP) were performed using full-field and half-field stimulation. Delays were found after right eye stimulation, with both temporal

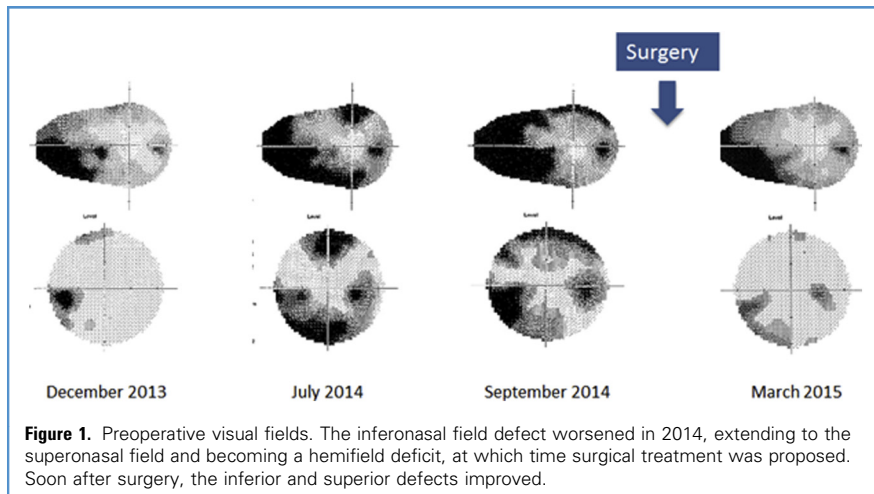


Figure 1. Preoperative visual fields. The inferonasal field defect worsened in 2014, extending to the superonasal field and becoming a hemifield deficit, at which time surgical treatment was proposed. Soon after surgery, the inferior and superior defects improved.

and nasal fields affected. The delays were mild to moderate and consistent with early optic nerve disease. No abnormalities were present on the left.

In view of the typical history, nasal field defect, VEP, and MRI, the diagnosis of microvascular compression of the optic nerve was withheld and the patient was informed that conservative management would be maintained except if the symptoms worsened.

Six months later, the patient presented for routine follow-up at the eye clinic and a dramatic worsening of his visual field defect was noted, with both inferior and superior defects (see **Figure 1**). He also had the impression that his depth

perception had deteriorated, which troubled him when reaching for items such as a cup of coffee. He denied changes in color vision or other visual disturbances. He mentioned that the flashes had become more brilliant and longer lasting. The flashes were triggered by eye movements. In view of his clinical deterioration, confirmed by visual field testing, he was offered an MVD.

SURGERY

After induction of anesthesia, intubation, and ventilation, the patient was put in a supine position with his head rotated 40° to the left. His head was pinned in a Mayfield headrest. An incision was made in the hairline across the midline for 3 cm. A single-piece orbitozygomatic craniotomy was elevated, to minimize retraction of his temporal and frontal lobe. Subsequently, the sphenoid wing was removed as well as the anterior clinoid and the orbital roof posteriorly, overlying the optic nerve. After this, the dura was incised over the anterior part of the temporal lobe and inferior part of the frontal lobe. Subsequently, the sylvian fissure was split widely. Without the use of retractors, the carotid artery was exposed and followed posteriorly to where the A1 branches off from the carotid and a vascular compression can be seen from the A1 as well as the anterior communicating artery on the superior part of the chiasm (**Figure 3A–C**). Shredded Teflon was inserted between

the vascular compression and the right side of the chiasm to perform the MVD (see **Figure 3B**). Subsequently, the dural ring over the carotid was incised anteriorly so that the optic nerve became detached from the dura and could be stretched more by the carotid artery. An indentation could be seen in the nerve where the optic strut and the anterior clinoid were located (see **Figure 3B**). Subsequently, the operative field was thoroughly rinsed and the dura was reconstructed with artificial dura. After this, the orbitozygomatic craniotomy was replaced and fixed with plates and screws, followed by weaning of anesthesia and extubation.

On the night after the MVD and optic nerve release, the flashes of white light in his right eye disappeared and did not return. A postoperative computed tomography scan performed on day 1 showed the orbitozygomatic approach with anterior clinoidectomy, optic canal decompression, and the Teflon in situ (**Figure 4**). Five days after his surgery, he was discharged home and followed up in the outpatient clinic after 6 weeks and 3 months. At follow-up, he had no more phosphenes/ photopsia and subjectively had the impression that his vision had improved. His strabismus on the other hand subjectively felt worse, even although his diplopia had not worsened. He denied any headaches, concentration problems, or memory problems, but still had some fatigue at 6 weeks.

VEP postoperatively showed an improvement in the Proo latency of the right eye nasal half-field VEP from 118 milliseconds preoperatively to 110 milliseconds postoperatively. The temporal half-field VEP remained unchanged at 110 milliseconds.

DISCUSSION

Microvascular compression syndromes, irrespective of the cranial nerve involved, share a common clinical picture, which permits a clinical diagnosis, with MRI to confirm the vascular compression²² or to exclude another cause for the typical clinical picture.^{23,24} Signs and symptoms of a microvascular compression syndrome can be summarized by unilateral, paroxysmal, and intermittent hyperactivity of a cranial nerve, which is often triggered

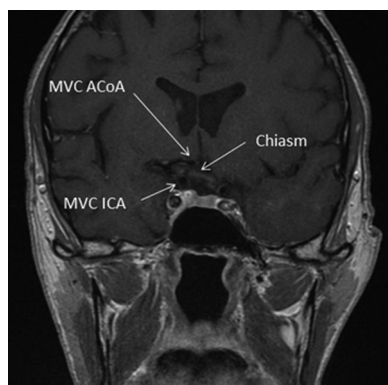


Figure 2. Preoperative magnetic resonance imaging showing the sandwiched right optic nerve/chiasm. AcoA, anterior communicating artery; ICA, internal carotid artery; MVC, microvascular compression.

Download English Version:

<https://daneshyari.com/en/article/3094927>

Download Persian Version:

<https://daneshyari.com/article/3094927>

[Daneshyari.com](https://daneshyari.com)