

Short communication

Cherubism: long-term follow-up of 2 patients in whom it regressed without treatmentGuilherme Costa Carvalho Silva^{a,*}, Ricardo Santiago Gomez^a,
Tainah Couto Vieira^b, Edgard Carvalho Silva^a^a Department of Oral Surgery and Pathology, School of Dentistry, Universidade Federal de Minas Gerais, Belo Horizonte, Brazil^b Department of Paediatric Dentistry and Orthodontics, School of Dentistry, Universidade Federal de Minas Gerais, Belo Horizonte, Brazil

Accepted 27 August 2006

Available online 6 October 2006

Abstract

Cherubism is a rare hereditary, self-limiting fibrous dysplasia characterised by painless enlargement of the jaws in childhood. Although, it is accepted that the lesions of cherubism are eventually replaced by bone, there have been few long-term follow-up reports with clinicoradiographic documentation of spontaneous remission of the disease, without treatment. We report two cases of cherubic boys who were followed for 17 and 19 years. Clinicoradiographic examination during this period showed regression of the disease without surgical correction.

© 2006 The British Association of Oral and Maxillofacial Surgeons. Published by Elsevier Ltd. All rights reserved.

Keywords: Cherubism; Treatment; Follow-up; Giant cell; Familial fibrous dysplasia

Introduction

Cherubism is a rare, non-neoplastic, self-limiting fibro-osseous disease, characterised by painless expansion of the mandible or maxilla, or both. Children are normal at birth and the expanding jaw is noticed within the first years of life, becoming progressively larger until the beginning of adolescence.^{1,2} It is genetically inherited,^{3,4} although many non-familial cases have been reported.^{2,5–7}

Although, regression of the lesion is expected during puberty, documented reports with long-term follow-up are rare.^{1,2,6} The aim of this paper is to report two patients who were followed for 17 and 19 years. Clinicoradiographic observation showed that the cherubic characteristics regressed, emphasising the importance of close long-term follow-up.

Report of cases*Case 1*

A 6-year-old boy was brought by his parents for evaluation of a painless growth on his face. A panoramic radiograph (Fig. 1A), and an incisional biopsy confirmed the diagnosis of cherubism and it was planned to follow him up. By the age of 12, the growth had stabilised. At the age of 21, he returned for extraction of ectopic and unerupted teeth and swelling was seen only in the maxilla (Fig. 1B). At 23 years of age his remaining teeth required extraction and at this time he had only minor residual enlargement of the maxilla (Fig. 1C).

Case 2

A 6-year-old boy presented with painless facial swelling. A clinicoradiographic diagnosis of cherubism was made and it was (Fig. 2A) confirmed by histopathological examination. It was planned to follow him up. By the age of 11 the mandibular enlargement was more noticeable (Fig. 2B), but by the age of 12, the lesion had started to get smaller. When he was

* Corresponding author at: Av Afonso Pena 4334, Belo Horizonte, MG 30130-009, Brazil. Tel.: +55 31 3225 0966; fax: +55 31 3223 7945.

E-mail address: guilhermeccs@ufmg.br (G.C.C. Silva).

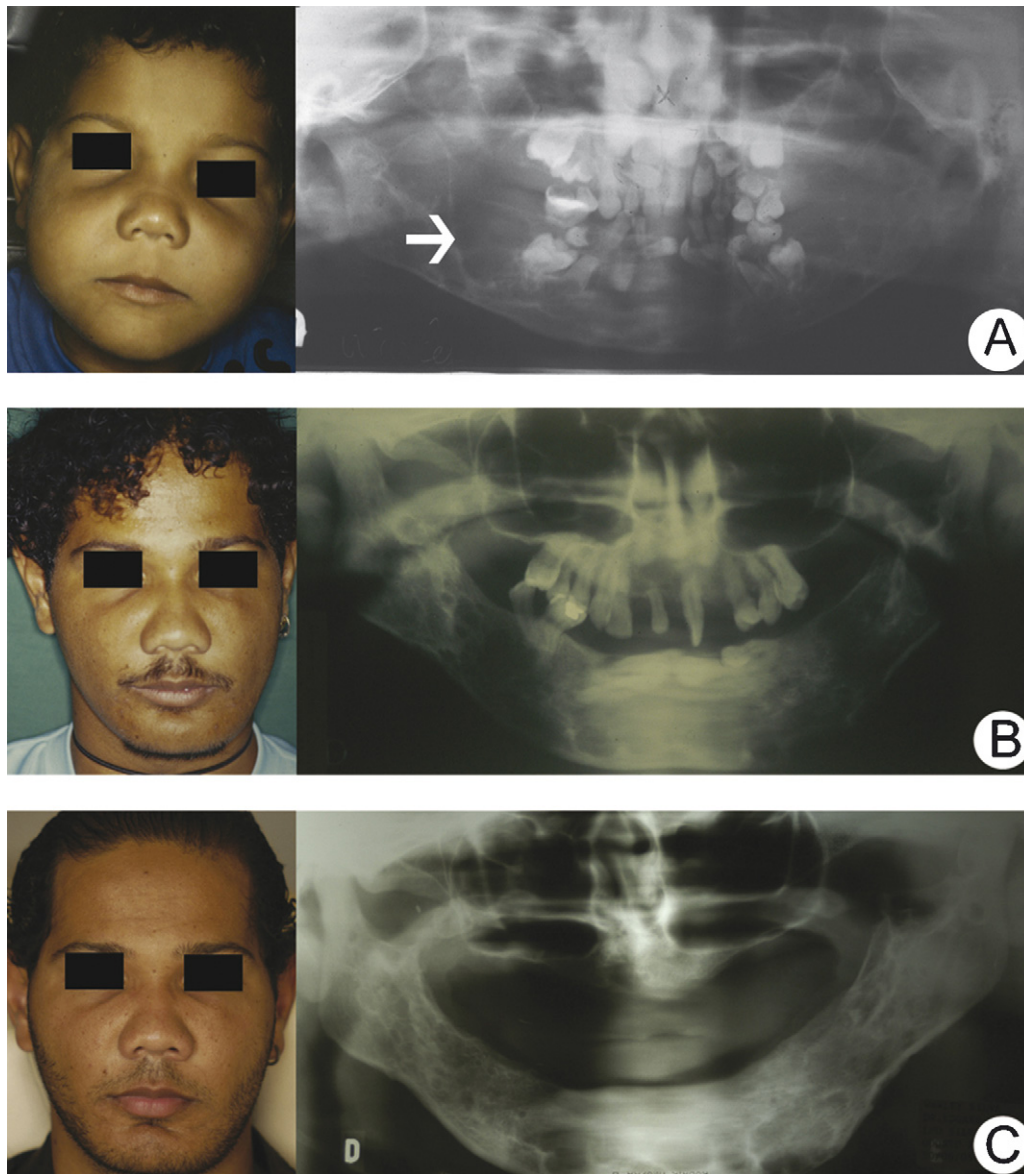


Fig. 1. (A) At 6 years of age, the patient's face was enlarged. A panoramic radiograph showed diffuse multilocular radiolucencies involving the jaws. There was a large radiolucency in the right mandibular body (arrow); (B) by the age of 21 years, facial swelling was restricted to the maxilla, and a radiograph showed impaction of the inferior anterior teeth as well as other teeth abnormalities. Regression of the multilocular lesions was noticeable; (C) by 23 years of age his facial appearance was similar to previous and the radiograph showed almost complete regression of the lesions. Note total bony filling in the large lesion that had been seen at 6 years of age in the right body of the mandible.

16 years of age the mandibular enlargement was slight, and swelling was more noticeable in the maxilla. Radiographs showed considerable shrinkage of the lesions (Fig. 2C). By 25 years of age there was only minor swelling of the maxilla, and a radiograph showed that the lesions were almost totally replaced by bone (Fig. 2D).

Discussion

The current knowledge about the clinical behaviour of cherubism is based on the study by Jones et al.,¹ on a few series of cases,^{2,5,8–10} on single case reports,^{6,7} and on reviews of

published cases. Although, almost every paper states that the disease progresses until puberty, stabilises and then regresses, only a few studies have followed untreated patients for a long period showing documented regression of the lesions. Katz et al.,⁶ who reported regression in a patient with an affected mandible, whom they followed for 15 years, stated: "most reports of remission of cherubism without treatment appear to be anecdotal in nature."

Jones et al.¹ followed three cherubic siblings for 16 years, but the patients were operated during their adolescence for appreciable facial deformity. Before the operation, only one patient had shown signs of reduction in the size of the lesions. Another long-term follow-up study with a considerable num-

Download English Version:

<https://daneshyari.com/en/article/3125670>

Download Persian Version:

<https://daneshyari.com/article/3125670>

[Daneshyari.com](https://daneshyari.com)