

Bony defect of palate and vomer in submucous cleft palate patients

S. Ren¹, L. Ma², X. Zhou², Z. Sun³

¹Department of Implantology, Peking University School of Stomatology, Beijing, China; ²Department of Oral and Maxillofacial Surgery, Peking University School of Stomatology, Beijing, China; ³Department of Radiology, Peking University School of Stomatology, Beijing, China

S. Ren, L. Ma, X. Zhou, Z. Sun: Bony defect of palate and vomer in submucous cleft palate patients. *Int. J. Oral Maxillofac. Surg.* 2015; 44: 63–66. © 2014 International Association of Oral and Maxillofacial Surgeons. Published by Elsevier Ltd. All rights reserved.

Abstract. The aim of this study was to visualize bony defects of the palate and vomer in submucous cleft palate patients (SMCP) by three-dimensional (3D) computed tomography (CT) reconstruction and to classify the range of bony defects. Forty-eight consecutive non-operated SMCP patients were included. Diagnosis was based on the presence of at least one of three classical signs of SMCP: bifid uvula, a translucent zone in the midline of the soft palate, and a palpable ‘V’ notch on the posterior border of the bony palate. Patients were imaged using spiral CT. 3D reconstruction models were created of the palate and vomer. The sagittal extent of the bony cleft in SMCP was classified into four types: type I, no V-shaped hard palate cleft (8.3%); type II, cleft involving the partial palate (43.8%); type III, cleft involving the complete palate and extending to the incisive foramen (43.8%); type IV, cleft involving the complete palate and the alveolar bone (4.2%). The extent of the vomer defect was classified into three types: type A, vomer completely fused with the palate (8.3%); type B, vomer partially fused with the palate (43.8%); type C, vomer not fused with the palate up to the incisive foramen (47.9%). Significant variability in hard palate defects in SMCP is the rule rather than the exception. The association of velopharyngeal insufficiency with anatomical malformations may be complex.

Key words: submucous cleft palate; palatal bony defect; vomer; CT reconstruction.

Accepted for publication 7 September 2014
Available online 23 October 2014

Submucous cleft palate (SMCP) is a congenital anomaly with a reported prevalence of 1:1250–1:6000.¹ Calnan² described SMCP as the anatomical triad of a bifid uvula, a bony notch at the back edge of the hard palate, and a translucent zone in the midline of the soft palate. Occult SMCP was introduced by Kaplan in 1975.³ In this condition, there is no classic triad of SMCP, only a diastasis of the

palatal muscles and velopharyngeal insufficiency (VPI). Occult SMCP can be identified further by nasopharyngeal endoscopy, showing the absence or hypoplasia of the musculus uvulae.

The aim of this study was to examine the anatomical variations of the hard palate and vomer in symptomatic SMCP by three-dimensional (3D) computed tomography (CT). An additional goal was to

examine the correlation of bony defects with mucosal manifestations in SMCP.

Materials and methods

Forty-eight consecutive non-operated SMCP patients, seen at the cleft lip and palate centre from October 2008 to April 2013, were included in this study. Diagnosis was based on the presence of at least one

of the three classical signs and evidence of VPI confirmed by nasopharyngeal endoscopy. The classical signs are a bifid uvula, a translucent zone in the midline of the soft palate, and a palpable 'V' notch on the posterior border of the bony palate.

All patients were scanned using a 16-slice CT scanner (GE BrightSpeed Elite; GE Healthcare) to obtain morphometric CT data of the bony palate and maxillary structures. Axial scans were performed from the anterior cranial base down to the inferior border of the mandible. Before scanning, the patient's head was positioned precisely in the CT scan unit, aligning Reid's base (line joining the infraorbital margin to the centre of the external auditory meatus) with the horizontal laser positioning guide beam. The external midline of the face (represented by the line joining the glabella, soft tissue nasion, and soft tissue pogonion) was aligned to the midsagittal laser positioning guide beam from the CT gantry. CT scans without contrast (thickness 2 mm, 140–160 mA, 120 kV) were obtained in the sequence described above.

Local research and ethics committee approval was obtained for the study. Each patient provided written consent prior to CT scanning.

A 3D CT reconstruction of the patient's head was created using GVCN software (version no. 3.1.35, China, CREALIFE TECHNOLOGY) with bone density. The areas above the anterior nasal spine and below the mandibular dentition were cut out to superimpose the palate alone. Each occlusal view of the hard palate and lateral view of the vomer was captured from the 3D model, as shown in Fig. 1.

3D reconstruction model analysis

Based on analysis of the existing classifications of cleft palate, in particular the

Kernahan⁴ Y classification with the modification of Smith et al.,⁵ we developed a system to describe the deformity of the bony cleft palate in SMCP. The designations and associated descriptions are as follows: type I, no V-shaped hard palate cleft; type II, cleft involving the partial palate; type III, cleft involving the complete palate and extending to the incisive foramen; type IV, cleft involving the complete palate and the alveolar bone.

Bony vomer malformations have rarely been described in previous articles, so we developed a classification based on the CT findings of SMCP. The type descriptions are as follows: type A, vomer completely fused with the palate; type B, vomer partially fused with the palate; type C, vomer not fused with the palate up to the incisive foramen.

Three surgeons independently assessed the classifications of the bony palate and vomer using the CT images and 3D reconstructions, according to the criteria described above.

Results

Bony defect of the palate

A great variation in the sagittal extent of the cleft was observed in malformations of the hard palate, ranging from unaffected to extension of the cleft to the alveolar bone. On clinical examination, the mucous cleft is not necessarily related to the bony cleft. Figure 2 shows four different cases of radiological cleft palate and clinical mucous cleft.

To assess inter-rater reliability, the kappa statistic was used to evaluate the consistency of the classification system. The correlation coefficient (R) was >0.7 , proving good inter-rater reliability.

The proportions of the four types of bony cleft palate were determined to be

as follows: type I, no V-shaped cleft, 8.3% (4/48); type II, cleft involving the partial palate, 43.8% (21/48); type III, cleft involving the complete palate and extending to the incisive foramen, 43.8% (21/48); type IV, cleft involving the complete palate and the alveolar bone, 4.2% (2/48).

Bony defect of the vomer

The proportions of the three types of vomer malformation (Fig. 3) were determined to be as follows: type A, vomer completely fused with the palate, 8.3% (4/48); type B, vomer partially fused with the palate, 43.8% (21/48); type C, vomer not fused with the palate up to the incisive foramen, 47.9% (23/48).

The extent of vomer malformation was not necessarily correlated with the extent of the cleft palate. Some patients with a minimal bony cleft palate malformation had severe hypoplasia and the vomer not fused with the palate at all.

Discussion

The bony defect in SMCP has been described vaguely as 'a bony notch' or 'V notch' of the hard palate since 1954. Sommerlad et al.⁶ described a system for grading the bony defect of the hard palate in SMCP ranging from 0 (normal) to 3 (severe), according to observations made during surgery. Grzonka et al.⁷ also reported anatomical malformations of the hard palate in SMCP observed during surgery, ranging from unaffected to extending to the incisive foramen. In contrast to the vague observations made in the limited surgical view or by palpation during physical examination, CT reconstruction of the hard palate and vomer can provide clear and precise views for use not only by the surgeon but also by the speech pathologist and other doctors involved. With CT confirmation, we found a fourth type of bony malformation in SMCP – bony cleft involving the complete palate and extending to the alveolar bone. The incidence of this type is very rare, hence it has not been reported before.

SMCP was previously thought to be a small subgroup of cleft palate (CP).⁸ Our study showed the proportion of type III SMCP to be equal to that of type II, meaning that a considerable percentage of cases with SMCP have a similar bony defect of the hard palate to isolated CP cases. In previous human embryogenesis studies of CP, bony structures and the related palatal muscles, considered as the complex palatal shelves, have been shown to emerge sequentially during the

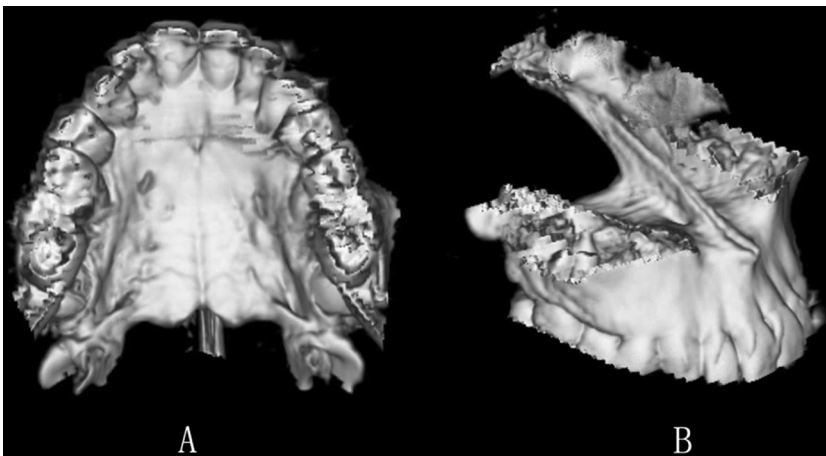


Fig. 1. (A) Occlusal view of the bony palate. (B) Lateral view of the bony vomer.

Download English Version:

<https://daneshyari.com/en/article/3132242>

Download Persian Version:

<https://daneshyari.com/article/3132242>

[Daneshyari.com](https://daneshyari.com)