

Prevalence of 3- and 4-rooted First and Second Mandibular Molars in the Israeli Population

Avi Shemesh, DMD,* Avi Levin, DMD,* Vered Katzenell, DMD,* Joe Ben Itzhak, DMD,* Oleg Levinson, DMD,[†] Avraham Zini, PhD, DMD, MPH,[‡] and Michael Solomonov, DMD*

Abstract

Introduction: Three-rooted mandibular molars are 1 of the anatomic variations of mandibular molars. The location of the additional root is distolingual (radix entomolaris) or mesiobuccal (radix paramolaris). The purpose of this retrospective study was to assess the prevalence of 3- and 4-rooted mandibular first and second molars in the Israeli population and to classify them according to dimension, curvature, and location of separation from the main root. **Methods:** A total of 1020 Israel patients' cone-beam computed tomographic scans were screened and evaluated. The incidence of 3- and 4-rooted first and second mandibular molars were recorded and analyzed. One thousand four hundred sixty-five mandibular second molars and 1,229 mandibular first molars were evaluated. **Results:** The overall incidence of patients with 3-rooted mandibular first and second molars was 2.6% and 1.78%, respectively. The bilateral incidence of 3-rooted mandibular first and second molars was 26%. The incidence of 4-rooted mandibular second molar was 0.55%. No significant difference was found regarding sex or side of occurrence. **Conclusions:** The occurrence of 3-rooted mandibular first molars in the Israeli population was rare, but clinicians should be aware of the special characteristic of this anatomic variation to modify accordingly the form of pulp chamber opening and choose appropriate instrumentation. (*J Endod* 2015;41:338–342)

Key Words

Cone-beam computed tomographic imaging, mandibular molar, radix entomolaris, radix paramolaris

From the *Department of Endodontics, Israel Defense Forces Medical Corps, Tel Hashomer, Israel; [†]Private Practice, Tel-Aviv, Israel; and [‡]Department of Community Dentistry, Hebrew University-Hadassah School of Dental Medicine, Jerusalem, Israel.

Address requests for reprints to Dr Avi Shemesh, Department of Endodontics, Israel Defense Forces Medical Corps, Tel Hashomer, Israel. E-mail address: shemavi2345@gmail.com 0099-2399/\$ - see front matter

Copyright © 2015 American Association of Endodontists. <http://dx.doi.org/10.1016/j.joen.2014.11.006>

The basis of root canal treatment is a procedure of cleaning, shaping, and obturation (1). Knowledge of root anatomy and canal morphology is essential for successful endodontic treatment (2).

The first and second mandibular molars are usually 2 rooted: 1 mesial root and 1 distal root (2). One of the anatomic variations of mandibular molars is an additional root, which was first mentioned in the literature by Carabelli (3) and called radix entomolaris in the distolingual location or radix paramolaris in the mesiobuccal location (4, 5). This variation is well documented in the literature, but most publications deal with first molars with 3 roots. The additional root can be classified by curvature, dimension, and point of separation from the main root (4, 6).

The frequency of an additional root in the first mandibular molar is up to 32% in Eskimos, 30% in Chinese, and 18.8% in Japanese. In the European population, a maximum frequency of 3.4%–4.2% has been found (7–13). The frequency of an additional root in the second mandibular molar is up to 3.5% in Brazilians, 1.9% in whites, and 25.8% in Koreans (14–16).

Cone-beam computed tomographic (CBCT) imaging is a 3-dimensional (3D) imaging technique that can be useful for diagnosing irregular anatomy (17, 18). Recently, CBCT imaging has been found to be useful and accurate in assessing root canal morphology. CBCT scanning is a noninvasive method that provides for axial and cross-sectional observation of each tooth and makes it easier to diagnose additional roots (19–23).

The purpose of the study was to investigate the prevalence of additional roots in the first and second mandibular molars in the Israeli population and to classify them by dimension, curvature, and point of separation from the main root.

Materials and Methods

The study was approved by the Ethics Committee of Medical Corps, Israeli Defense Forces (IDF-1258). A total of 1020 patients' retrospective dental CBCT (Alioth; Asahi Roentgen IND, Kyoto, Japan) records, which had already been recorded in an x-ray institute in Israel from 2009 to 2012, were examined.

The patients (447 males and 573 females) were referred to this institute and required a tomographic examination by CBCT imaging as part of their dental examination, diagnosis, and treatment planning.

The CBCT images were taken using the ASAHI Alioth CBCT device at 360 x-ray tube head rotation. All CBCT scans were reformatted to standard manufacturer settings; the exposure parameters of each scan were as follows: constant tube voltage of 85 kV, tube current of 6 mA, and field of view of 80 × 80 mm with a resolution of 0.155 × 0.155 × 0.154999 mm. CBCT exposures were performed with the minimum exposure necessary for adequate image quality.

Personal details including age and sex of all these patients were recorded. The CBCT images were analyzed with OnDemand3D software (CyberMed, Irvine, CA) in a darkroom. The contrast and brightness of the images were adjusted using the image processing tool in the software to ensure optimal visualization. CBCT images were evaluated by 2 graduate endodontic residents who were calibrated based on the criteria and variants established before their evaluation. CBCT images were analyzed simultaneously to reach a consensus for the interpretation of the radiographic findings. In cases of

disagreement, a third, definitive evaluation was conducted by an endodontist with 10 years of experience who was calibrated based on the same criteria and variants.

First and second mandibular molars were analyzed using 3 planes (sagittal, axial, and coronal) slices (Fig. 1A and B), and additional roots were classified as follows (Fig. 2A–F):

1. Curvature, straight or curved root
2. Dimension, shorter and conical or normal length compared with other roots
3. Point of separation from the main root, cervical or apical

In cases of disagreement, a third, determinate valuation was conducted by an endodontist with 10 years of experience. The reviewers were calibrated on the basis of the criteria and variants established before their evaluation.

The Pearson chi-square test was applied to examine any statistically significant difference between sex and the side of occurrence. A *P* value < .05 was considered significant.

Results

One thousand twenty patients, 573 females and 447 males, aged 13–89 years (mean age = 43.05 years) were included in this study.

A total of 1,465 mandibular second molars and 1,229 mandibular first molars were evaluated. The distribution of 3- and 4-rooted mandibular teeth is shown in Table 1.

Radix entomolaris was found in 25 first mandibular molars (2.03%) and 6 second mandibular molars (0.41%). Radix paramolaris was found in 7 first mandibular molars (0.57%) and 20 second mandibular molars (1.37%). Eight second mandibular molars had 4 roots (0.55%) (Fig. 3). In a total of 2694 first and second mandibular molars, 66 3- and 4-rooted mandibular molars were found (2.45%).

No statistically significant differences of 3-rooted mandibular first and second molars were detected for sex ($P > .05$) or side of occurrence (left vs right side, $P > .05$) (Table 1). Table 2 indicates that 26% (12/46 patients) of the 3-rooted mandibular first molars occurred bilaterally, and all cases of 4-rooted mandibular molars are unilateral (Fig. 4). One of the patients has radix paramolaris in all 4 mandibular molars.

Analysis of the 3-rooted mandibular first molars revealed (Table 3) the following:

1. Most of the radix entomolaris roots are curved roots (18/25) with the same length as the main root (17/25) and the point of separation is in the cervical third of the root (23/25).
2. All of the radix paramolaris roots are straight roots (7/7) and have the same length as the main root (7/7).

Analysis of the 3-rooted mandibular second molars (Table 3) revealed that most of the radix paramolaris roots are of the same length as the main root (18/20).

Discussion

An additional root in mandibular molars is 1 of the anatomic variations of these teeth. The presence of additional roots in mandibular molars is associated with certain ethnic groups (7–16). According to the present results, the occurrence of radix entomolaris roots in mandibular first and second molars in the Israeli population was 2.03% and 0.41% of all teeth examined, respectively.

The occurrence of radix paramolaris roots in mandibular first and second molars in the Israeli population was 0.57% and 1.37% of all teeth examined, respectively. This finding is in agreement with a previous report on Europeans but is lower compared with data reported for non-European races (7–16).

In the present study, no significant difference was found according to sex or the side of occurrence. However, other studies reported that 3-rooted mandibular first molars occurred more frequently on the right or left side (11, 12, 17, 24, 25).

Zhang et al (13) analyzed 232 mandibular first molars and 157 mandibular second molars, and they found one 4-rooted mandibular first molar. In the present study, we found 8 mandibular second molars with 4 roots.

Identifying the additional root is critical for successful treatment. Periapical x-rays are 2-dimensional, and the additional root might be hidden behind the main root, especially if the additional root is short or curved. A second radiograph should be taken from a more mesial or distal angle (30°) and can be useful for the diagnosis (4, 6). The ultimate examination is CBCT imaging, providing 3D observations of the additional root and its exact relation to the pulp chamber.

Knowledge of the additional root's existence and location leads to correct preparation of the access cavity for locating all canals (26). The conventional triangular opening cavity must be modified to a trapezoidal form in order to locate and access the orifice of the additional root better (6). An extension of the access cavity to the orifice location

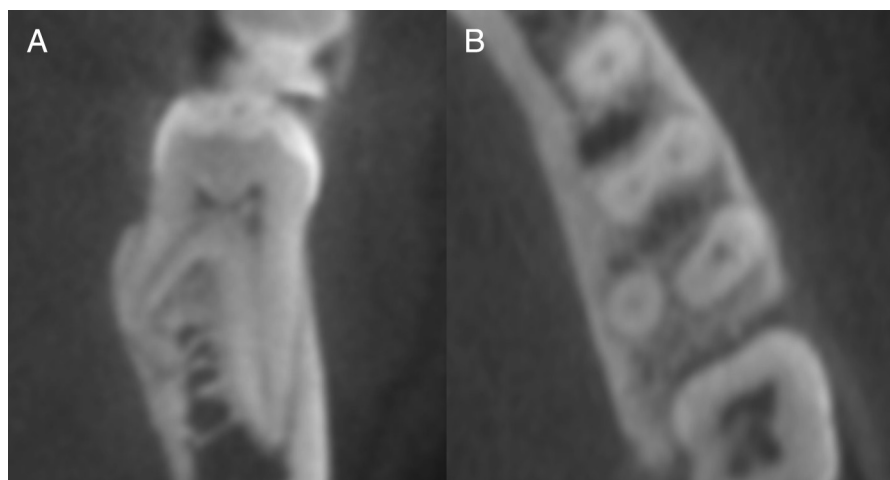


Figure 1. CBCT images of a first mandibular molar with a radix entomolaris: (A) cross-sectional slice and (B) axial slice.

Download English Version:

<https://daneshyari.com/en/article/3148308>

Download Persian Version:

<https://daneshyari.com/article/3148308>

[Daneshyari.com](https://daneshyari.com)