
Management of cervical root fracture using orthodontic extrusion and crown reattachment: a case report

Harun Canoglu, DDS, PhD,^a H. Cem Gungor, DDS, PhD,^b and Zafer C. Cehreli, DDS, PhD,^b
Ankara, Turkey
HACETTEPE UNIVERSITY

Root fractures involve damage to pulp, cementum, dentin, and periodontal ligaments. These injuries affect 0.5% to 7% of permanent teeth. Cervical root fractures are less frequently seen and have a worse prognosis compared with the fractures in the apical or middle third of the root. This case report describes the treatment of a cervical root fracture in a maxillary central incisor. After removal of the coronal fragment, the root was filled temporarily with calcium hydroxide and orthodontic extrusion was initiated. The remaining root portion was elevated above the epithelial attachment and a successful coronal restoration was made using the natural crown of the traumatized tooth. (*Oral Surg Oral Med Oral Pathol Oral Radiol Endod* 2007;104:e46-49)

Root fracture is a rare type of dental traumatic injury, affecting 0.5% to 7% of permanent teeth.^{1,2} In this type of injury, the wound involves damage to the pulp, cementum, dentin, and periodontal ligament.³ As with other types of dental traumatic injuries, the maxillary central incisor region is affected predominantly. Root fractures are uncommon in teeth with incomplete root development and those in various stages of eruption.⁴ Etiological factors for root fractures include mostly fight injuries and foreign bodies striking the teeth.⁵ Root fractures may be transverse (horizontal), oblique, or vertical; however, horizontal and oblique fractures are the most commonly seen types.⁶

Horizontal root fractures frequently occur in the middle third of the root, followed by apical and coronal regions.^{5,7} They comprise less than 3% of all dental injuries,⁸ and are more likely to take place in fully erupted permanent maxillary central incisors with complete root formation.⁹ Depending on the severity of the injury, multiple or single fractures of the root can be observed. Single fractures that are distant from the cervical level are believed to have better prognosis.⁶

This case report presents management of a cervical root fracture using orthodontic extrusion and a final restoration with the patient's fractured natural crown.

CASE REPORT

A 12-year-old boy presented to the pediatric dentistry clinic for the management of pain and mobility of his upper left central incisor. His medical history was noncontributory. Reportedly, he had a bicycle accident 48 hours before admission. Clinical examination revealed absence of perioral and intraoral trauma to soft tissues. The crown of the maxillary right central incisor showed signs of excessive mobility, and the tooth was tender to palpation. The neighboring central and lateral incisor teeth were free of any symptom indicative of trauma. Periapical radiographs taken from different angulations revealed an oblique root fracture that extended to approximately one third of the entire root length (Fig. 1). The absence of radiographic findings in the neighboring teeth confirmed their clinical diagnosis (Fig. 1).

Because of the high mobility and the radiographic findings, the coronal fragment needed to be extracted. It was decided to initiate orthodontic extrusion of the root so as to facilitate placement of a coronal restoration. Because both the patient and his parents were highly concerned with the aesthetic outcome of treatment, the possibility of using the clinical crown was proposed and the advantages and possible complications of the treatment plan were discussed. Upon approval of the patient and his parents, the fractured coronal portion was removed under local anaesthesia (Fig. 1) and stored in sterile saline at +4°C until final restorative procedures. After establishing hemostasis at the extraction site, pulp tissue was removed from the remaining root with barbed broaches and with copious saline irrigation. Because the depth of endodontic access compromised ideal conditions for a single-visit root canal treatment, the root canal was temporarily filled with a radiopaque calcium hydroxide paste (Calcicur, Voco, Cuxhaven, Germany), leaving the coronal third unfilled. Meanwhile, a 0.7-mm round orthodontic wire (Dentaurum, Ispringen, Germany) was bent to form a 3-mm-diameter loop with a 5-mm radicular extension, which was further roughened with diamond disks to provide retention within the root canal. Resin-modified glass ionomer cement (Vitremer, 3M/Espe, Seefeld, Germany) was mixed and in-

^aResearch Assistant, Department of Pediatric Dentistry, Faculty of Dentistry, Hacettepe University.

^bAssociate Professor, Department of Pediatric Dentistry, Faculty of Dentistry, Hacettepe University.

Received for publication Mar 19, 2007; accepted for publication Mar 23, 2007.

1079-2104/\$ - see front matter

© 2007 Mosby, Inc. All rights reserved.

doi:10.1016/j.tripleo.2007.03.030

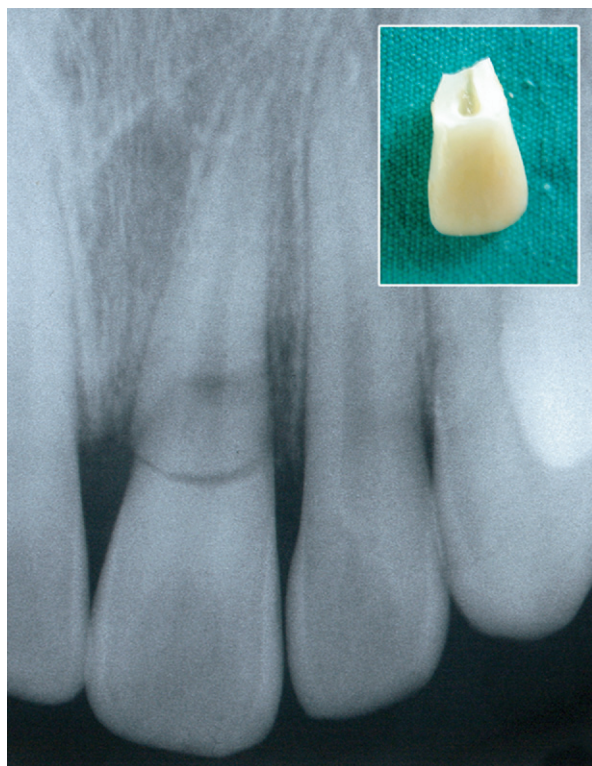


Fig. 1. Radiographic view of the traumatized incisor, revealing borders of the oblique crown-root fracture. The extracted coronal fragment (*upper right*) confirms the radiographic extent of fracture.

jected into the unfilled portion of the root canal, followed by insertion of the radicular portion of the loop. After radiographic confirmation of correct placement of the loop, the excess cement was carefully removed with a small excavator and the cement was light cured for twice the time recommended by the manufacturer (80 seconds), because of the increased distance between the light fiber tip and the root canal orifice. At the same appointment, impressions were taken and model casts were prepared. The patient was scheduled for a second appointment the following day.

A modified Hawley appliance was fabricated, composed of a labial bow with an offset loop over the fractured root (Fig. 2). After insertion of the appliance, an elastic band was placed through the coronal loop and tied to the loop of the labial bow (Fig. 2). The patient was instructed to wear the appliance 24 hours a day. The elastic string was changed twice a week. Orthodontic extrusion was terminated when all root margins were exposed. This corresponded to approximately a 6-mm extrusion, achieved in 6 months (Fig. 3). At the third month of extrusion, the Hawley appliance was replaced with a fixed bonded loop placed between the neighboring teeth to increase the interloop distance and, thus, facilitate further extrusion (Figure 3, C).

Following removal of the loop and the intracanal calcium hydroxide paste, the root canal was filled with gutta percha

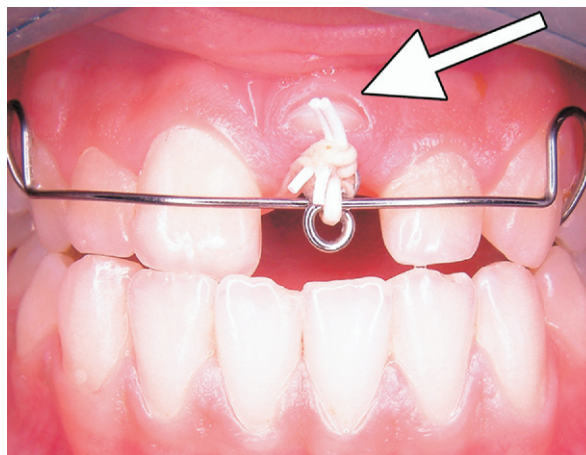


Fig. 2. Intraoral view of the modified Hawley appliance at the second month of orthodontic extrusion. The buccal aspect of the root surface (*arrow*) has recently fenestrated the attached gingiva, indicating the necessity for further extrusion.

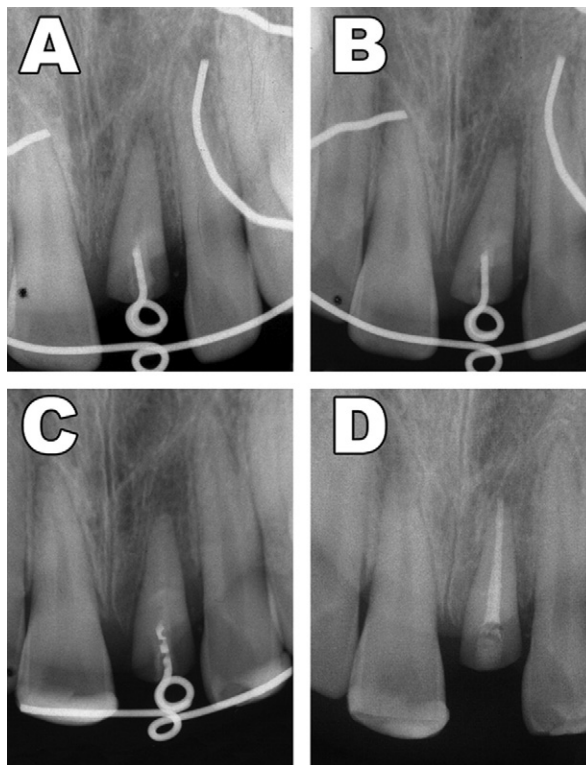


Fig. 3. Position of the loop extension within the canal and advancement of the orthodontic extrusion as viewed radiographically. A, 1-month; B, 3-month; C, 5-month; and D, 6-month view showing extent of extrusion and final obturation of the root canal.

and AH Plus Sealer (Dentsply, Konstanz, Germany), leaving the occlusal third of the root unfilled for placement of the resin composite. Meanwhile, the fractured coronal portion,

Download English Version:

<https://daneshyari.com/en/article/3169261>

Download Persian Version:

<https://daneshyari.com/article/3169261>

[Daneshyari.com](https://daneshyari.com)