Available online at www.sciencedirect.com

ScienceDirect

journal homepage: www.elsevier.com/locate/odw

Original article

Dimensional changes of upper airway after rapid maxillary expansion evaluated with cone beam computed tomography

Soosan Sadeghian [a], Roshanak Ghafari [b], Masoud Feizbakhsh [a], Sepideh Dadgar [c,*]

[a] Azad University of Isfahan, Dental Faculty, Department of Orthodontics, Isfahan, Iran
[b] Azad University of Isfahan, Dental Faculty, Department of Radiology, Isfahan, Iran
[c] Department of Orthodontics, Faculty of Dentistry, Mazandaran University of Medical Sciences, Sari, Iran

ARTICLE INFO

Article history:
Received 9 April 2015
Received in revised form
31 October 2015
Accepted 25 November 2015

Keywords:
Maxillary expansion
Airway
Cone-beam computed tomography

ABSTRACT

Purpose: The objective of this research study was to assess the effect of rapid maxillary expansion treatment on nasal cavity, upper airway, as well as facial height and convexity using cone beam computed tomography (CBCT).

Methods: We evaluated 15 patients with maxillary width deficiency treated with rapid maxillary expansion (RME). Patients were subjected to CBCT at the beginning of the RME treatment and again after the retention period of 4 months in order to measure the changes of retropalatal and retroglossal airways, nasal cavity and cephalometric parameters. The measurements of the before and after RME scans were compared using a paired *t* test.

Results: The average increase of the retropalatal airway volume (2.31 mm^3) and the total upper airway volume (3.23 mm^3) was statistically significant ($p = 0.04$ and $p = 0.05$ respectively), while the change in retroglossal airway volume (0.92 mm^3) was not significant. Significant increase was observed in the transverse distances of the anterior, middle and posterior areas of the lower third of nasal cavity following the RME treatment ($p = 0.008$, $p = 0.003$ and $p = 0.002$ respectively). No significant difference was observed in the cross-sectional areas passing epiglottis (EP), soft palate (SP) and posterior nasal spine (P) planes or other cephalometric parameters before and 4 months after the treatment.

Conclusions: The RME treatment resulted in significant increase in the transverse width of the nasal cavity, as well as upper and retropalatal airways. However, this effect was not observed for the cross-sectional areas of the upper airway, anterior and posterior facial heights and facial convexity following RME treatment.

© 2016 Elsevier Ltd and the Japanese Orthodontic Society. All rights reserved.

1. Introduction

Increasing the width of the palate through rapid maxillary expansion (RME) is a method for correcting transverse maxillary deficiency and posterior cross-bite as well as increasing the dental arch space to correct crowded teeth. Given the tendency toward non-extraction treatments and creating wider and more beautiful smile. The majority of orthodontists use RME treatment to fix arch length discrepancy in patients who have potential arch form [1]. RME treatment is commonly used in orthodontic treatments, where orthopedic force is used to open mid-palatal suture [2].

* *Corresponding author*. Tel.: +98 51137689987.
E-mail address: dadgar_sepideh@yahoo.com (S. Dadgar).
http://dx.doi.org/10.1016/j.odw.2015.11.001
1344-0241/© 2016 Elsevier Ltd and the Japanese Orthodontic Society. All rights reserved.

The effect of RME treatment on respiration has been widely studied in various articles due to the anatomical proximity of the upper airway and maxilla and as a result several radiographic techniques have been proposed.

Cone beam computed tomography (CBCT) is a new technology, which uses cone-beam source and two-dimensional detector to obtain images of desired area. CBCT total basic images are analyzed by computer software programs in order to obtain the previously reconstructed images [3–5]. CBCT technology has provided many benefits compared to the conventional radiography, including a more accurate diagnostic and a higher scanning speed than computed tomography (CT), as well as a better resolution (0.4–0.1) and more importantly patient receives lower dosage [3,6,7].

Many studies have been conducted on the effect of RME on the upper airway and nose, however reported results are contradictory. Some of these studies were not able to show any effect of RME treatments on nasal cavity and oropharynx [8–10]. Whereas other studies hypothesized that RME increases the volume of nose and therefore increases nasal permeability and create nasal breathing pattern [9]. However, RME has been proposed as a method for improving nasal breathing in recent years. In 1987, Hartgerink et al. [11] reported that RME can eliminate the adverse effects of nasal obstruction on the facial form. This method not only improves dental arch but also reduces nasal obstruction following the treatment. In 1976, Hershey et al. [12] showed a significant reduction in nasal obstruction as a result of RME treatment.

There is no study available on the three-dimensional changes of airway following a RME treatment to this date. In addition, all the studies conducted on the effect of RME on nasal and upper airway are controversial. Due to the emergence of the CBCT technology in the field of radiology and dentistry, this study aims to use this technology and further investigates the effect of RME treatment on the three-dimensional changes in the upper airways.

2. Materials and methods

A total of 15 patients (8 boys, 7 girls; mean age, 13.02 ± 1.23 years [boys, 10–15 years; girls, 10–14 years]) were selected among the patients referred to the department of orthodontics dentistry school of the Islamic Azad University of Isfahan in Iran. All of these patients were in need of RME treatment due to the transverse maxillary deficiency. Skeletal maturation for each patient was determined with cervical vertebrae analyses. Only patients with forecasted potential growth were recruited for the study. All participants had bilateral Class I malocclusion. Those with history of craniofacial deformities, previous orthodontic or orthopedic treatment, adenoidectomy, and tonsillectomy were excluded from the study. This research was approved by the Ethics Committee of the Isfahan University of Medical Sciences. Informed consents were obtained from the patients and parents of minors for the participation in this study.

After the selection, patients were treated with four-point (2 bands on premolars and 2 on molars) or two-point (2 bands on molars) Hyrax appliances. These appliances were activated through rapid method. The device screw was opened two turns (each turn equal to 0.25 mm) in the first session and then twice per day (0.5 mm activation per day) on the following days. Screw opening was continued to the extent that the palatal cusp of the upper first molar comes in contact with the lingual slope of the buccal cusp of the lower molar.

The images of CBCT were used to evaluate patients before and 4 months after RME treatment. All CBCT images were taken in a normal position and natural breathing. Images were prepared using Sordex-Scanora 3D-Finland with a large field of view (13.0 cm × 14.5 cm). The resulting images were then transferred to a computer and three-dimensional reconstruction was performed on them.

At the level of the furcation of the first molar and from the axial section of the T1 and T2 CBCT image, a line was drawn between the right and left furca. The palatal maxillary width was the interalveolar distance between the palatal plates along this line.

An on demand 3D version 1 software was used to measure morphological three-dimensional measurements. Three-dimensional airway analysis was performed using the volume measurement section of the software. In order to evaluate the nasal cavity the images were placed in a way that the axial plane of image passed through the palatal plane (ANS-PNS). In the sagittal plane, LA point was defined as the point obtained by the intersection of the true vertical line drawn from nasion and palatal plane [13]. Two other points were located every 15 mm from this point, indicating the medial and posterior region of the nasal cavity (Fig. 1). These anterior, middle and posterior sections were examined using the coronal sections in transverse dimension (Fig. 2).

Upper airway was defined as the volume of the airway between the two planes [14]: the upper plane was posterior nasal spine (P) plane, which horizontally attached the posterior nasal spines (PNS) to basion. These points were selected due to their proximity to the upper airway, as well as their clear CBCT image in the sagittal plane. The inferior plane was epiglottis (EP), which passed horizontally through the

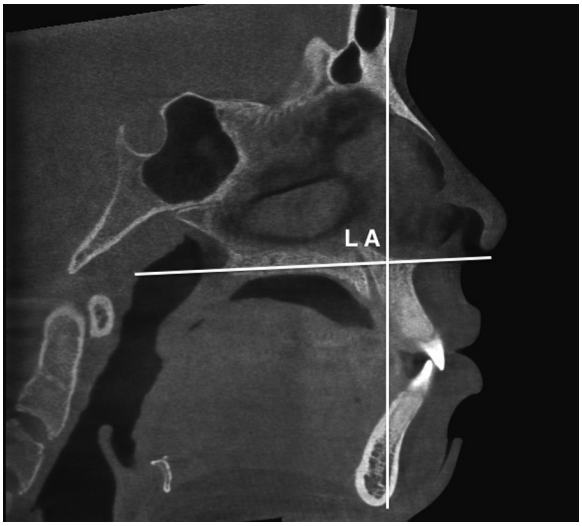

Fig. 1 – Determination of the anterior, middle and posterior nasal cavity.

Download English Version:

https://daneshyari.com/en/article/3170256

Download Persian Version:

https://daneshyari.com/article/3170256

Daneshyari.com