

Spectrum and progression of disease from condyloma to aggressive anogenital squamous cell carcinoma in 3 HIV-positive patients

Olaf Rodriguez, BS,^a and Carrie L. Kovarik, MD^{b,c}
Philadelphia, Pennsylvania

Key words: anogenital; carcinoma; condyloma; HIV; immunosuppressed; squamous.

INTRODUCTION

Human papillomavirus (HPV) is the causative agent of condyloma acuminata (CA). Although it is often assumed that CA are caused by HPV subtypes distinct from those that lead to squamous cell carcinoma, this is not always the case, particularly in immunocompromised patients. A greater percentage of HIV-positive men are infected with multiple HPV subtypes within their CA than their HIV-negative counterparts, with lower CD4 counts associated with higher levels of oncogenic HPV DNA. In addition, HIV-positive individuals have a higher prevalence and incidence of HPV-associated anal intraepithelial neoplasia (AIN) and anogenital cancers than their HIV-negative counterparts. Furthermore, many instances of malignant transformation of CA have been described. Here we show the spectrum and progression of disease from CA to aggressive anogenital squamous cell carcinoma in 3 HIV-positive patients and stress the diversity of clinical presentations that can exist in this patient population. Immunosuppression from HIV infection, co-infection with multiple HPV subtypes including oncogenic strains, a history of a low CD4 nadir, and the inability to adequately clear the HPV puts patients at a much greater risk of malignant progression of HPV-associated skin lesions, which can be rapid in some cases. Hence, it is critical that dermatologists screen patients and those affected receive close clinical monitoring, disease surveillance, and appropriate prompt treatment.

Abbreviations used:

AIN:	anal intraepithelial neoplasia
ARV:	antiretroviral
CA:	condyloma acuminata
HPV:	human papillomavirus
MSM:	man who has sex with men
SCCIS:	squamous cell carcinoma in situ

CASE REPORTS

Patient 1

An HIV-positive man in his 20s with a history of smoking, asthma, and pneumocystis pneumonia presented with numerous raised 2-mm condylomata on his penile shaft and anus. The patient was recently incarcerated and had sexual activity with more than 20 male and female partners. The patient had been inconsistent with his antiretroviral (ARV) regimen (efavirenz, emtricitabine, tenofovir, and ritonavir-boosted atazanavir) since his HIV diagnosis (baseline CD4 count of 22 cells per microliter). After restarting ARV therapy, his CD4 count increased and his viral load decreased; however, 8 months later the condylomata remained stable and continued to be unresponsive to imiquimod 5% 3 times weekly.

The patient did not return for 18 months. He presented with more than 20 skin-colored and hyperpigmented verrucous papules on his penile shaft, grouped hyperpigmented papules extending to the anal verge on his perianal skin, and a pedunculated 1-cm verrucous nodule on his right perianal skin. He underwent cryotherapy to the

From the Perelman School of Medicine at the University of Pennsylvania^a and the Departments of Dermatology^b and Medicine,^c University of Pennsylvania.

Funding sources: None.

Conflicts of interest: None declared.

Correspondence to: Carrie L. Kovarik, MD, Department of Dermatology, University of Pennsylvania, 3600 Spruce Street, 2 Maloney Building, Philadelphia, Pennsylvania 19104. E-mail: carrie.kovarik@uphs.upenn.edu.

JAAD Case Reports 2016;2:47-50.
2352-5126

© 2015 by the American Academy of Dermatology, Inc. Published by Elsevier, Inc. This is an open access article under the CC BY-NC-ND license (<http://creativecommons.org/licenses/by-nc-nd/4.0/>).

<http://dx.doi.org/10.1016/j.jdc.2015.12.003>

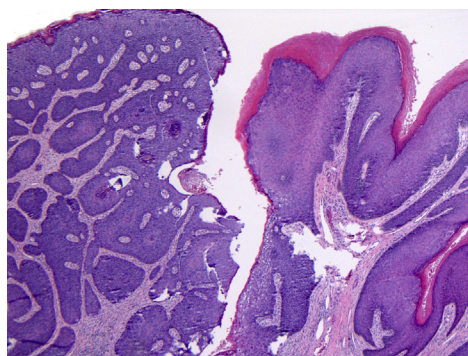


Fig 1. Biopsy of pedunculated perianal lesion from patient 1. The biopsy shows a pedunculated condyloma with a transition zone to SCCIS (Hematoxylin-eosin stain; original magnification: $\times 40$.)

lesions on his penile shaft and perianal area and shave excision of the pedunculated lesion on his perianal skin. The biopsy found a pedunculated condyloma with a transition zone to squamous cell carcinoma in situ (Fig 1) with HPV-16 positivity (Fig 2). Imiquimod 5% was prescribed for treatment 5 times weekly for the remaining condyloma. Although we emphasized to the patient the importance of complete treatment, he was once again lost to follow-up.

Patient 2

A man in his 40s with a long history of HIV positivity, moderate-to-heavy smoking, disseminated Kaposi's sarcoma, HPV-related oral leukoplakia (and subsequent invasive squamous cell carcinoma; Fig 3), HPV-related rectal cancer in remission, and a CD4 count less than 200 cells per microliter presented for evaluation and treatment of condylomata on the penis and perianal region. A diagnosis of CA was rendered; however, 1 lesion on the penis was larger and more atypical than the others, and a biopsy was performed. Histologically, the penile lesion showed squamous cell carcinoma in situ (SCCIS). The patient was treated with a combination of cryotherapy and imiquimod 5%.

Over the next few months, the patient continued to have an excellent response to imiquimod 5%, with complete resolution of his penile CA. However, the patient then began experiencing perianal bleeding, and on physical examination was found to have a new perianal erosion suspicious for malignancy. Histologically, biopsies found SCCIS in the perianal area, and the patient was treated with imiquimod. Over the next year, the patient's CD4 count increased to 217 cells per microliter, and his viral load became undetectable, and all evidence of his perianal CA resolved.

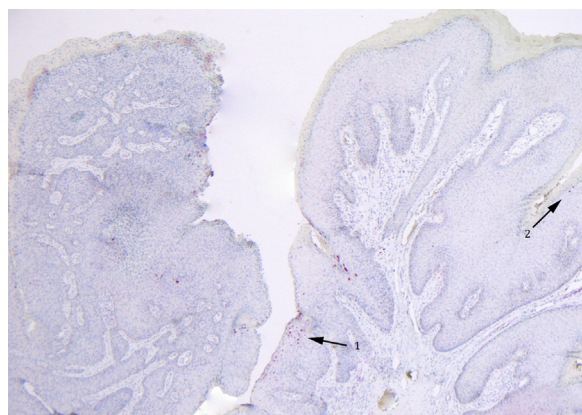


Fig 2. HPV-16 immunostaining of the lesion in Fig 1. Significant HPV-16 nuclear staining is observed within the pedunculated lesion excised from patient 1. HPV-16 staining can be seen within the SCCIS region of the specimen (arrow 1) and within the adjacent condyloma (arrow 2) (original magnification: $\times 40$.)

The patient remained clear of his perianal CA for 3 years, at which point a concerning new perianal thin red plaque was noted. A biopsy of the lesion found recurrent SCCIS, and an excision was performed. Results of a follow-up anoscopy were normal, and the patient was counseled to undergo an annual anoscopy because of his high risk of anal dysplasia and recurrent anal cancer.

Patient 3

An HIV-positive (baseline CD4 count of 138 cells per microliter [20%], viral load of 33,453 copies per milliliter) man in his 20s with a history of central nervous system toxoplasmosis and perianal CA presented in acute renal failure and with a recent history of rectal bleeding. The patient identified as a man who has sex with men (MSM). Upon admission, random biopsies of his rectum during colonoscopy found histologic changes consistent with HPV and low-grade AIN-1. The patient's CD4 count at this time was 77 cells per microliter, and he was started on ARV therapy (Truvada and ritonavir-boosted darunavir).

Over the next 6 months, the patient tolerated his ARV regimen well, with his CD4 count increasing to 120 cells per microliter and his viral load decreasing. However, the patient's lesions did not improve, and he presented for evaluation of a new painful partially prolapsed ulcerated lesion emanating from his anal canal. The patient underwent successful transanal excision of this anal canal mass and distal anal canal condyloma fulguration and excision. He also had new anal and perianal condyloma lesions. Excisional biopsies of these lesions were found to be a mixture

Download English Version:

<https://daneshyari.com/en/article/3197312>

Download Persian Version:

<https://daneshyari.com/article/3197312>

[Daneshyari.com](https://daneshyari.com)