



African Federation for Emergency Medicine African Journal of Emergency Medicine

www.afjem.com
www.sciencedirect.com



CASE REPORT

“Be still my beating heart”: Ventricular standstill occurring in different age groups



Tais-toi mon cœur battant: La pause ventriculaire dans différents groupes d'âge

Richard M. Lynch^{*}, Louise Ballesty, Rawle Maicoo

Emergency Medicine, Midland Regional Hospital, Mullingar, Co. Westmeath, Ireland

Received 20 November 2013; revised 11 February 2014; accepted 15 February 2014; available online 1 August 2014

Introduction: Ventricular standstill is an uncommon yet potentially fatal arrhythmia, which requires urgent recognition and treatment. As the name suggests, the ventricles come to a standstill with an almost immediate cessation of cardiac output. If this persists for more than a few seconds the patient will lose consciousness and no pulse will be palpable. Recommended treatment includes prompt initiation of cardiopulmonary resuscitation, and if return of circulation is achieved, pacemaker insertion is usually required.

Case report: Four case reports are presented which highlight the ECG features of ventricular standstill and that this arrhythmia can occur across a wide range of ages.

Conclusion: Ventricular standstill can occur at any age. It can be difficult to diagnose with many cases only evident on pre-hospital ECG recordings. It may present as recurring episodes of loss of consciousness yet the patient may be well in the intervening period. During episodes of ventricular standstill failure to palpate the pulse and/or over reliance on cardiac monitoring and automated ECG analysis programmes to determine the heart rate, may result in dramatic overestimation of the heart rate and may lead to delays in initiation of cardiopulmonary resuscitation and pacing if required.

Introduction: La pause ventriculaire est une arythmie peu courante, mais potentiellement mortelle, qui nécessite un diagnostic et un traitement urgent. Comme son nom l'indique, les ventricules se mettent en pause, avec un arrêt quasi-immédiat du débit cardiaque. Si cette pause persiste pendant plus de quelques secondes, le patient perdra conscience et le pouls ne sera plus palpable. Le traitement recommandé consiste à pratiquer rapidement une réanimation cardio-pulmonaire, et si le cœur repart, l'insertion d'un pacemaker est généralement nécessaire.

Études de cas: Quatre études de cas sont présentées, qui soulignent les caractéristiques à l'ECG de la pause ventriculaire; elles révèlent également que cette arythmie peut survenir sur une large fourchette d'âge.

Conclusion: La pause ventriculaire peut survenir à tout âge. Elle peut être difficile à identifier, de nombreux cas n'apparaissant qu'à l'ECG réalisé avant l'arrivée à l'hôpital. Elle peut se présenter sous forme d'épisodes de perte de conscience récurrents, mais le patient peut également se sentir bien lorsqu'elle se produit. Lors des épisodes de pause ventriculaire, l'absence de prise de pouls et/ou le recours excessif à l'électrocardioscope et aux programmes d'analyse automatique des ECG pour déterminer la fréquence cardiaque peuvent résulter sur une surestimation considérable de la fréquence cardiaque et retarder l'initiation de la réanimation cardio-pulmonaire ainsi que la stimulation cardiaque si celle-ci s'avère nécessaire.

African relevance

- Ventricular standstill is an uncommon, yet potentially fatal arrhythmia.
- Ventricular standstill can occur at any age.

Introduction

Ventricular standstill (also called ventricular asystole) is a potentially lethal arrhythmia if not treated promptly.¹ It occurs when there is cessation of supraventricular impulse

formation or blockage in the transmission of these impulses from the atria to the ventricles resulting in asystolic cardiac arrest.² Slow ventricular escape rhythms with broad QRS complexes may also be observed.³

As the name suggests the ventricles come to a standstill with an almost immediate cessation of cardiac output. If this persists for more than a few seconds the patient will lose consciousness and no pulse will be palpable. Recommended treatment includes cardiopulmonary resuscitation,⁴ and if return of circulation is achieved, pacemaker insertion is usually required.⁵ Typical ECG appearances of ventricular standstill are the absence of any ventricular activity despite the presence of atrial activity, with or without ventricular escape rhythm.^{1,3}

The prognosis from asystole is extremely poor with only 2–5% of patients, in one study, who suffered an out of hospital asystolic cardiac arrest surviving to hospital discharge.⁶ Therefore prompt diagnosis is required and treatment commenced without delay.

^{*} Correspondence to Richard M. Lynch. richardlynch2@mac.com

Peer review under responsibility of African Federation for Emergency Medicine.



Production and hosting by Elsevier

We present four cases of ventricular standstill, which occurred in patients of very different ages; a young child, a young female, a middle-aged female and an elderly male. These cases highlight the fact that ventricular standstill can occur at any age.

Case reports

Case 1: A 14 month-old boy was brought to our emergency centre (EC) by his parents in the early hours of the morning. He had been unwell for a few days with vomiting and a lower respiratory tract infection. He had a background history of pulmonary hypertension. His condition worsened that night when he had a witnessed episode of unresponsiveness and apnoea. On arrival at the EC he was extremely ill with decompensated hypotensive shock as evident by the presence of hypotension, listlessness, cold to touch and mottling of the skin. The automated ECG analysis programme recorded a heart rate of 134 beats per minute (bpm) when in fact the correct rate was only 20 bpm (Fig. 1b). This error occurred because the tall broad P waves, from pulmonary hypertension, were mistaken for QRS complexes (Fig. 1a). This resulted in a seven fold overestimation of the heart rate and delayed initiation of cardiopulmonary resuscitation by several minutes. At a rate of 20 bpm, chest compressions should have been performed whereas at a rate of 134 bpm chest compressions would not be indicated.²

While being treated he suffered a sudden cardiac arrest. Following prolonged resuscitation, in excess of 45 min, return of spontaneous circulation was achieved. He was subsequently transferred to a tertiary paediatric centre where he underwent insertion of a permanent pacemaker and made a full recovery.

Case 2: A 19 year-old female self-presented to our EC with a 3-month history of dizziness, feeling light headed and on a few occasions felt as if she was going to pass out, although this did not happen. She was previously well and had no family

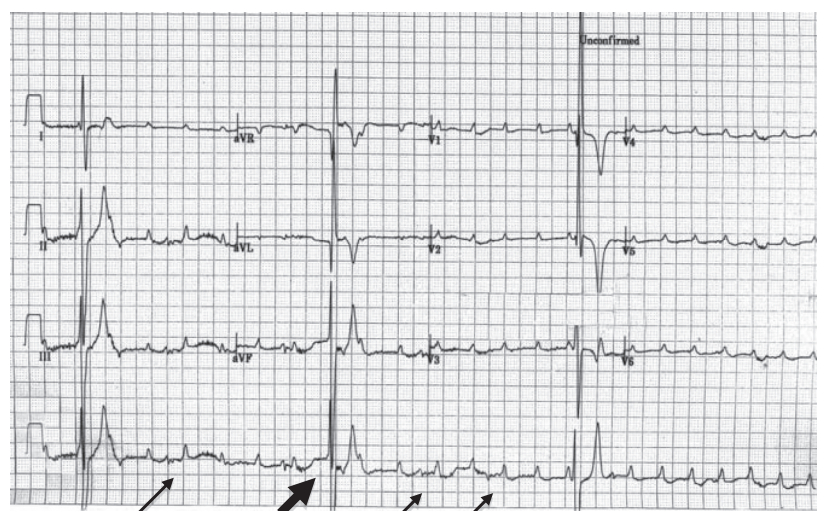
Vent. rate	134 bpm
PR interval	* ms
QRS duration	86 ms
QT/QTc	256/382 ms
P-R-T axes	* 73 252

Figure 1b Automated ECG analysis recorded the heart rate at 134 bpm when in fact it was only 20 bpm.

history of note. Following a number of presentations to her general practitioner and the EC, 24-h Holter monitoring was performed. This revealed several brief episodes of ventricular standstill (Fig. 2). She was referred for pacemaker insertion.

Case 3: A 50 year-old female was brought to our EC by ambulance following six witnessed episodes of loss of consciousness. Each episode lasted only seconds and she recovered rapidly and completely each time without any treatment. She was previously well, had no relevant past medical history, and no risk factors for cardiovascular disease. A rhythm strip recorded during the last of these episodes revealed marked sinus bradycardia at a rate of 30 bpm followed by a 12-s period of ventricular standstill (Fig. 3). No episode of ventricular standstill occurred in the hospital prior to pacemaker insertion.

Case 4: An 82 year-old male presented to our EC after suffering two witnessed episodes of collapse with loss of consciousness at home. He did not report any symptoms prior to these episodes. These persisted for only a few seconds and he recovered quickly without the need for any medical treatment. These occurred following minimal exertion; walking a few steps after standing up. On arrival of the ambulance the patient was alert, vital signs were normal and he had no symptoms following these episodes. Background history of hypertension, which was well controlled for many years, was noted. He did not have any previous cardiac history and apart



Block arrow: Ventricular escape rhythm Small arrows: Tall P waves secondary to pulmonary hypertension

Figure 1a Ventricular standstill with escape rhythm at a rate of 20 bpm with broad and tall P waves.

Download English Version:

<https://daneshyari.com/en/article/3222733>

Download Persian Version:

<https://daneshyari.com/article/3222733>

[Daneshyari.com](https://daneshyari.com)