Injury, Int. J. Care Injured 45S (2014) S16–S23

Contents lists available at ScienceDirect

Injury

journal homepage: www.elsevier.com/locate/injury

New interlocking intramedullary radius and ulna nails for treating forearm diaphyseal fractures in adults: A retrospective study

Gursel Saka [a,*], Necdet Saglam [a], Tuhan Kurtulmuş [a], Cem Coşkun Avcı [a], Fuat Akpinar [b], Halim Kovaci [c], Ayhan Celik [c]

[a] Umraniye Research and Education Hospital, Department of Orthopedics, Istanbul, Turkey
[b] Abant Izzet Baysal University, Faculty of Medicine, Department of Orthopedics, Turkey
[c] Ataturk University, Engineering Faculty, Department of Mechanical Engineering, Turkey

ARTICLE INFO

Article history:
Accepted 1 November 2013

Keywords:
Radius
Ulna
Forearm fracture
Intramedullary nailing
Adult

ABSTRACT

Introduction: The treatment goal for diaphyseal forearm fractures in adults is to restore axial and rotational stability. The treatment of these fractures with intrmaedullary locked nailing remains sparse. We therefore evaluated IM nails for treating forearm diaphyseal fractures in adults.
Methods: We retrospectively reviewed adult patients with isolated unilateral or bilateral fractures of the radius, ulna, or both, who were treated with closed or mini open reduction with a new IM nail between May 2008 and January 2012 and who were followed for a least 1 year. Patients with a Galeazzi fracture, a pathological fracture or patients with nonunion after previous surgeries were excluded. All patients were allowed full range of motion without any external support. Primary outcomes were Grace and Eversmann rating, Disabilities of the Arm, Shoulder and Hand (DASH) scores.
Results: The 43 enrolled patients (mean age, 37 years; 32 men) had 59 forearm fractures: 14 isolated radius fractures, 17 isolated ulna fractures (2 bilateral), and 28 fractures of both the radius and ulna. Mean time to fracture union was 13 weeks (range 10–14 weeks) for ulnar fractures and 12 weeks (range 10–13 weeks) for radial fractures. No patient had nonunion, deep infections, or radioulnar synostosis. Followup ranged from 12 to 44 months. Grace and Eversmann ratings were excellent in 38 patients and good in 5. Mean DASH score was 6.5 points (range 0–13.3).
Conclusions: Intramedullary nailing of adult forearm diaphyseal fractures appears to be a good alternative to plate osteosynthesis. The advantages are short operative time, minimal invasive techniques, and sufficient stability in all planes that allows early motion without additional fracture support.

© 2013 Elsevier Ltd. All rights reserved.

Introduction

The treatment goal for diaphyseal forearm fractures in adults is to obtain axial, rotational stability and restoration of the range of motion. Although closed locked intramedullary nailing is successful in treating femoral, tibial, and humeral shaft fractures [1–3], intramedullary (IM) nails are not routinely used in the surgical treatment of forearm fractures because they cannot provide sufficient rotational and linear stability in this region. High nonunion rates and the need for additional long-term fixation have limited their use [4]. However, newly designed interlocking IM nails that provide control of rotational malalignment at the fracture line have recently been introduced [1,5–8]. In addition to providing rotational stability, these nails can be inserted more easily and safely and have more options for proximal and distal locking.

The purpose of this study is to evaluate the effectiveness and the results of the use of intramedullary nails in the surgical treatment of adults with fractures of the radius, ulna, or both.

Materials and methods

Patients were enrolled between May 2008 and January 2012. Standard anteroposterior and lateral radiographs of the fractured forearm taken at the time of injury were used to classify the fractures according to the system used by Arbeitsgemeinschaft f?r Osteosynthesefragen/Association for the Study of Internal Fixation (AO/ASIF). The inclusion criteria were a forearm diaphyseal fracture, either a closed fracture, a grades I and II or grade IIIa open fracture, or a simple segmental fracture. In addition, cases

* Corresponding author. Tel.: +90 505 561 88 15; fax: +90 216 632 71 21.
E-mail address: gurselsaka@hotmail.com (G. Saka).

0020–1383/$ – see front matter © 2013 Elsevier Ltd. All rights reserved.
http://dx.doi.org/10.1016/j.injury.2013.10.040

with more than 10° angulation in any plane and more than 50% translation, cases with insufficient soft tissue, and those with increased potential for displacement during follow-up were included in the unstable patients surgical group. Patients with a Galeazzi fracture, fractures of the radial neck, or a pathological fracture or patients with nonunion after previous surgeries were excluded. Our institutional ethics committee granted permission for this study. Written informed consent was obtained from all patients.

Design of the intramedullary radius and ulna nails

Multi-functional forearm nails, made from a titanium alloy, were developed specifically for repairing fractures of the radius and ulna. All fractures were stabilised with interlocking IM forearm nails (TST Rakor Tıbbi Aletler San. ve Tic. Ltd. Sti., Istanbul, Turkey).

The radius IM nail is solid, round, conical-ended, and is inserted with the unreamed technique. Its distal end is angled anteriorly at 15°, and the proximal end is angled anteriorly at 10° (Fig. 1). The radius nail provides rotational stability through its proximal design, parabolic body and distal interlocking feature. Its parabolic body, 10° angled proximal 3 cm, and distal interlocking features provide three-point fixation. The design of the proximal and distal ends provides rotational stability and restores radial bowing. Static locking can be achieved by placing a locking screw inside the 17°-, proximal-volar angled, oblique hole, at its distal end. Locking screws are 2.7 mm in diameter, and they are available in 6-, 18-, 20-, 22-, and 24-mm-lengths, and can be placed without the use of fluoroscopy or guides. Diameter choices for the radius nails are 3, 3.5, and 4 mm, and the length choices for the nail are 18, 19, 20, 21, 22, 23, and 25 cm. The same nail can be used for the right and left radius.

The ulna intramedullary nail is solid, round, and unreamed. Distal locking can be achieved by one or more locking screws passing through the eight transverse grooves on the distal 3 cm of the nail without requiring fluoroscopy (Fig. 2). The nail allows static, dynamic, and single-cortex interlocking by round, oval, and proximal oblique holes (Figs. 3 and 4). The IM nail is inserted with the forearm in neutral position and distal locking is done while the forearm is in neutral position. Then, by doing passive full pronation and supination on forearm, the correction is checked. In this way, when it is thought that the desired degreee of rotation is achieved, proximal locking is applied. Using the oblique hole, interlocking can be performed in any direction (360°) with an angle of 20° from the proximal part of nail. Transverse, latero-medial, and postero-anterior dynamic interlocking can be made through the oval hole, which allows 7-mm compression 30 mm distal to the proximal part of nail. To provide the compression effect, firstly, through the oval hole of 10 mm × 3 mm in the proximal aspect of the nail, a 3 mm interlocking screw is applied. Then, by applying compressive endcup, through interlocking screw in oval hole, the gap in fractured line can be closed or the desired compression can be

Fig. 1. Placement of intramedullary radius nail in a cadaveric bone. The distal end is angled anteriorly at 15°, the shaft has parabolic curve, and the proximal part is angled anteriorly at 10°.



Fig. 2. The ulna intramedullary nail is solid, round, and unreamed. Distal locking can be achieved by passing one or more locking screws through the eight transverse grooves on the distal end. The nail allows static, dynamic, and single-cortex interlocking through round, oval, and oblique proximal holes.

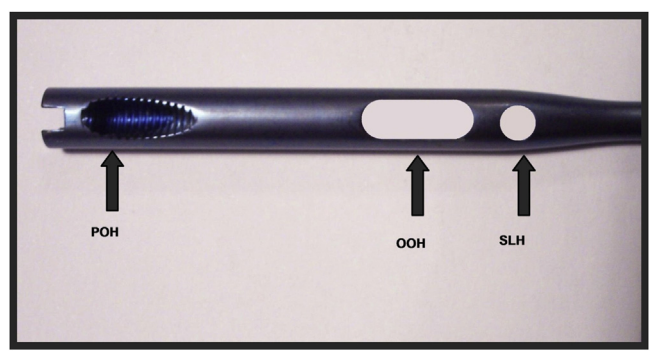

Fig. 3. Proximal design of the interlocking intramedullary ulna nail. POH, proximal oblique hole; OOH, oval oblique hole; SLH, static locking hole.

Fig. 4. Proximal oblique screw placement of the ulna intramedullary nail on the cadaveric model.

Download English Version:

https://daneshyari.com/en/article/3240101

Download Persian Version:

https://daneshyari.com/article/3240101

Daneshyari.com