


Available online at [www.sciencedirect.com](http://www.sciencedirect.com)

ScienceDirect

journal homepage: [www.elsevier.com/locate/jcot](http://www.elsevier.com/locate/jcot)

## Case Report

# Delayed debridement of an open total talar dislocation reimplanted in the emergency room



Essoh J.B. Sié MD (Ortho)\*, A. Traoré MD (Ortho), A.K. Sy MD (Ortho),  
K. Soumaro MD (Ortho), Y. Lambin MD (Ortho)

Department of Orthopaedic Surgery, Yopougon University Teaching Hospital, 21 BP 632 Abidjan, Côte d'Ivoire

## ARTICLE INFO

## Article history:

Received 20 December 2013

Accepted 18 April 2014

Available online 8 July 2014

## Keywords:

Hindfoot

Open dislocation

Reimplantation

Talar injury

## ABSTRACT

Open total talar dislocation is a rare but well known injury. Its management is controversial and fraught with complications such as infection, avascular necrosis, and post-traumatic osteoarthritis.

We report the case of a woman sustaining a pure open talar dislocation reduced in the emergency room. Debridement was done three days after the injury in the operating room. There was no infection. One year after surgery she complained of occasional pain. Ambulation was normal. She wore regular shoes. The overall alignment of the ankle, hindfoot, and midfoot was normal. Movements of the tibiotalar and subtalar joints were not impaired. She has resumed her regular activities. Radiographs showed no signs of avascular necrosis. All components of the treatment strategy of open total dislocation should be carried out in emergency. This results in environment close to the original biological state. Good results can be achieved if infection is avoided.

Copyright © 2014, Delhi Orthopaedic Association. All rights reserved.

## 1. Introduction

Open total talar dislocation is defined as an open injury with a dislocated talus involving dissociation of all three associated joints: tibiotalar, subtalar, and talonavicular.<sup>1</sup> This injury is rare but well known. Its management is controversial.<sup>2,3</sup> Recent publications recommend reimplantation of the native talus whenever it is possible, as it may restore the most normal joints mechanics, hindfoot height, and bone stock for reconstructive procedures.<sup>3–5</sup> The studies by Burston et al<sup>1</sup> and Smith et al<sup>6</sup> based on relatively large sample size could

be considered as recent landmark papers in an area where publications are sparse and often limited to case reports.<sup>2,3</sup>

Data gleaned in these landmark papers encompass epidemiological data, clinical and radiological aspects, treatment, and outcome of this peculiar injury. It is accepted that prompt management of open fracture or dislocation minimises complications and enhances possibilities for good outcome. In the current report the talus was reduced in the emergency room (ER). Debridement in the operating room was performed three days after the injury. Since infection and the need for a secondary surgical procedure are the primary determinants of clinical outcome<sup>6</sup> we present this case to determine whether

\* Corresponding author.

E-mail address: [siessoh@yahoo.com](mailto:siessoh@yahoo.com) (E.J.B. Sié).

<http://dx.doi.org/10.1016/j.jcot.2014.04.002>

0976-5662/Copyright © 2014, Delhi Orthopaedic Association. All rights reserved.

our results are likely to be different from those reported in literature.

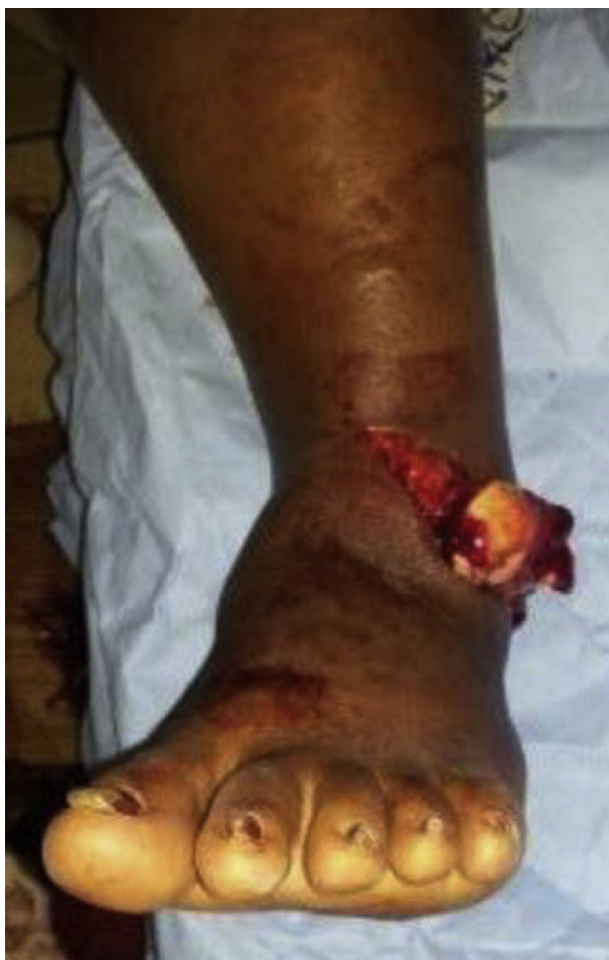## 2. Case report

A 38-year-old woman, a front seat passenger was transported to the emergency department by ambulance 4 h after a motor vehicle collision. She was conscious and sustained an open total talar dislocation through a 14 cm wound on the anterior lateral aspect of her left ankle (Fig. 1). The wound appeared clean.

There were no foreign bodies. The talus was maintained attached to the hindfoot by a soft tissue.

It was dislocated laterally and anteriorly. There was no associated fracture of the talus. The neurovascular status of the foot was normal. Radiographs of the ankle revealed a complete dislocation of the talus from the tibiotalar, subtalar, and talonavicular joints (Fig. 2A and B). There were no associated fractures of the ankle.

Upon admission, the patient was given injectable cefazolin and gentamicin and received a tetanus immune globulin. In the ER, the wound and the dislocated talus were irrigated with normal saline solution and cleansed with povidone



**Fig. 1** – Photograph showing the dislocated talus with the open lateral anterior ankle wound.

iodine. Under conscious sedation, the talus was reimplanted through the open wound and reduced into position, using gentle traction of the foot. The wound was covered with a sterile dressing.

It was remained undisturbed until the definitive debridement in the operating room. A posterior leg splint was applied. Radiographs performed after the reduction showed restoration of the articulations surrounding the talus (Fig. 3A and B). She received parenteral antibiotics and was taken to the operating room three days after the admission. The compound wound was irrigated, cleansed and debrided. The soft tissue was viable.

The reduction appeared stable with manual manipulations. No internal fixation was done. Primary closure of the wound without tension over a suction drainage was performed. A posterior leg splint was applied. Postoperative radiographs showed concentric reduction of the tibiotalar, subtalar, and talonavicular joints. The wound healed uneventfully without evidence of superficial or deep ankle infection. She was discharged home 21 days after the injury. The patient remained non-weight bearing on the injured limb for a period of 8 weeks. Then she was allowed to weight bear as tolerated on the left limb. Fifteen weeks after the injury full weight bearing was achieved. At 12 months follow-up, she complained of occasional pain. Ambulation was normal. She wore regular shoes. The overall alignment of the ankle, hindfoot, and midfoot was normal. Movements of the tibiotalar and subtalar joints were not impaired (Fig. 4A and B). She has resumed her regular activities. Radiographs showed no signs of avascular necrosis (AVN) (Fig. 5A and B).

## 3. Discussion

We report the case of a pure open total talar dislocation without disruption of all soft tissue attachment.

It is not the intent of this single case to deal with a specific surgical protocol. Emphasis is placed on time elapsed between injury and the start of the debridement in the operating room, the reduction in the ER, and complications. Recent landmark papers have not specifically mentioned the exact delay in operation since the time of injury.<sup>1,6</sup> However reimplantation was carried out urgently as soon as the patient was brought to the emergency department. All eight patients in the series by Burston et al.<sup>1</sup> were operated on within 24 h of their injuries. Delay between injury and debridement ranged from 1.5 h to 19.5 h, with an average of 6.7 h in most cases in the study by Smith et al.<sup>6</sup> One patient had a transport time greater than

12 h but was taken immediately to the operating room on arrival.<sup>6</sup> Reduction in the ER has been reported.<sup>6,7</sup> In the series by Smith et al.,<sup>6</sup> this was the case of two patients with other life-threatening injuries. Lee et al because of the urgency to treat the open injury have reduced the talus in the ER.<sup>7</sup> In that report preoperative radiographs have not been performed before the definitive treatment in the operative room. In our patient reduction in the ER and delayed debridement were related to logistic and socioeconomic reasons. One theatre was dedicated to orthopaedics. This was

Download English Version:

<https://daneshyari.com/en/article/3245503>

Download Persian Version:

<https://daneshyari.com/article/3245503>

[Daneshyari.com](https://daneshyari.com)