



## Invited Review Article

## Radiological approach to benign biliary strictures

Dong Il Gwon,<sup>1</sup> Hans-Ulrich Laasch<sup>2,\*</sup>

## A B S T R A C T

Benign biliary strictures can be attributable to a large variety of causes, but are commonly iatrogenic after direct or vascular injury during laparoscopic cholecystectomy and other biliary procedures. An increasing number of patients present with strictures of bilioenteric anastomoses after liver transplantation and radical surgery for hepatopancreaticobiliary cancer. Endoscopic access to the biliary tree may be difficult or impossible following pancreaticoduodenectomy, and in this context strictures are best approached percutaneously. In the past, strictures could only be managed with repeated balloon dilatations and/or long-term transhepatic catheter placement. This is not very satisfactory from a patient point of view. A long-term external drain is disfiguring and challenging to manage, and the patient has to undergo repeated, potentially very painful procedures. Newer developments attempting to achieve long-term resolution of benign strictures include fully covered, removable metal stents and the emerging option of biodegradable stents. Early outcomes of these new technologies are promising, but require a careful and considered multidisciplinary approach and heavy clinical involvement of the interventional radiologist.

Copyright © 2015, Society of Gastrointestinal Intervention. Published by Elsevier. Open access under [CC BY-NC-ND license](https://creativecommons.org/licenses/by-nc-nd/4.0/).

Keywords: absorbable implants, bile ducts, postoperative complications, stenoses, stents

## Introduction

There are many causes of benign strictures of the biliary tree, which include inflammation, gall stone disease, infection including parasites, and congenital abnormalities,<sup>1</sup> with iatrogenic strictures becoming more prevalent.

During cholecystectomy, strictures may be caused by direct trauma to the bile duct, thermal injury from cauterization, ischemia due to vascular injury, or occlusion by erroneous application of vascular clips. An increasingly important context is the radical treatment of cancers of the bile duct, pancreas, or duodenum. Although surgical revision is still regarded as a gold standard of treatment, this may be undesirable after radical cancer surgery, and patients increasingly expect to be treated with a minimally invasive approach.

Strictures of the anastomosis following pancreaticoduodenectomy are particularly difficult to manage because endoscopic access may not be possible even with balloon enteroscopy or endoscopic ultrasound. The same applies to liver transplantation, where there is an additional risk of developing ischemic biliary strictures owing to the devascularization.

Benign bile duct strictures carry the risk of stone formation and ascending cholangitis, which in itself may be life-threatening but can also lead to subsequent biliary cirrhosis.<sup>2</sup> Dealing with benign bile duct strictures can be extremely challenging and requires good collaboration within the multidisciplinary team in order to give the

patient the best outcome possible. Percutaneous transhepatic cholangiography allows drainage of an infected system and establishes access for repeat procedures.<sup>3</sup> However, this requires insertion of a transhepatic catheter, which is uncomfortable for the patient and very inconvenient in terms of the external drainage.

Interventional endoscopic ultrasound is a rapidly developing field, causing much excitement among endoscopists. Unfortunately, in an attempt to push the boundaries, aggressive transesophageal and transgastric access is often promoted as “the new way,” when collaboration with the radiologist might allow a much safer combined approach.<sup>4</sup> A guidewire placed percutaneously into the duodenum can be retrieved endoscopically, allowing a much more physiological drainage arrangement than with an extra-anatomical puncture (Fig. 1).

Owing to the high rate of recurrence of benign strictures, repeat procedures are usually required. A percutaneous approach allows access to be maintained and is often the most appropriate management. Specialist teams need to be aware of the options provided by radiological methods, and only close integration of the specialties can give patients the best chance of a successful outcome.

## Preparation

High-quality imaging is essential in the workup of the patient in order to confirm the benign nature of the lesion as well as the most appropriate access route. Baseline investigations should include

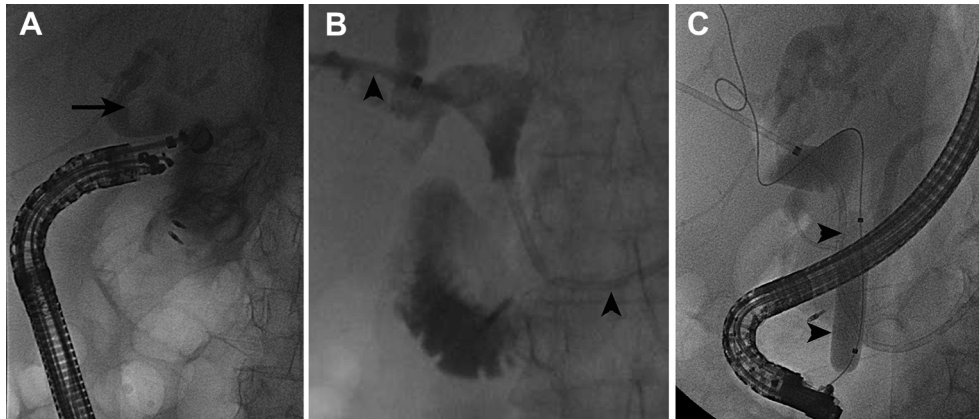
<sup>1</sup> Department of Radiology, Asan Medical Centre, Seoul, Korea

<sup>2</sup> Department of Radiology, The Christie NHS Foundation Trust, Manchester, UK

Received 28 November 2014; Revised 6 January 2015; Accepted 16 January 2015

\* Corresponding author. Department of Radiology, The Christie NHS Foundation Trust, Wilmslow Road, Manchester M20 4BX, UK.

E-mail address: [hul@christie.nhs.uk](mailto:hul@christie.nhs.uk) (H.-U. Laasch).



**Fig. 1.** Combined procedure following failed interventional endoscopy for a distal common bile duct (CBD) stricture. (A) After an unsuccessful attempt at endoscopic retrograde cholangiopancreatography (ERCP), EUS-guided transduodenal puncture managed to opacify the bile duct, but failed to achieve access into the CBD. Arrow: bile duct stone. (B) An 8F internal-external drain (arrowheads) was inserted percutaneously with the lower end in the fourth part of the duodenum. (C) After resolution of sepsis, retrograde access was obtained alongside the drain, followed by, stricture dilatation and sphincteroplasty with a 12 × 40 mm balloon (arrowheads) and the stone crushed.

ultrasound to confirm biliary dilatation, as well as assess for the presence of ascites and the signs of cirrhosis and portal venous hypertension. Computed tomography is usually the mainstay for planning, but magnetic resonance has a number of advantages. The biliary anatomy is very well demonstrated by magnetic resonance cholangiopancreatography, which—with added sequences—also allows characterization of the lesion to be treated.

A full biochemical profile, full blood count, and clotting screen are mandatory. Coagulopathy is usually corrected within 24 hours with an intravenous administration of 5–10 mg vitamin K, if there is sufficient hepatocellular function.<sup>5</sup>

Significant amounts of ascites separating the liver from the abdominal wall should be drained prior to biliary intervention as this increases the risk of hemorrhage and catheter displacement into the peritoneum.

It needs to be understood that chronic biliary obstruction particularly associated with low-grade sepsis may render the liver parenchyma too stiff to allow dilatation of the bile ducts, even in complete obstruction. Occasionally, this may even be associated with a normal bilirubin, but usually with a markedly raised alkaline phosphatase.

Gas in the bile ducts may reflect infection with gas-forming organisms, such as yeasts, and be mistaken as a sign of a patent connection with the small bowel. Administration of prophylactic antibiotics is not always required but should be intravenously administered for at least 24 hours if there is any suggestion of biliary sepsis. Secure intravenous access, ideally in both arms, must be established prior to the procedure and appropriate fluid resuscitation performed.

Planning of the puncture site needs to take into account the biliary anatomy and location of the stricture, but also potentially further steps that might be required in the future, such as insertion of long-term catheter or subsequent stent removal.

The technique of percutaneous transhepatic cholangiography is well established. In a nutshell, it involves ultrasound guided puncture with a 21–22G Chiba needle into a suitable duct, insertion of a 0.018-inch guidewire, over which a 6F access system is inserted. This will accept a 0.035-inch guidewire, at which point a simple external drain can be inserted or the access upgraded to allow for therapeutic maneuvers.

8F vascular access sheaths (Fig. 2A) are ideal for procedures where a number of different tools such as catheters, dilatation balloons, stents, and drains may have to be passed. They safeguard the access into the biliary tree and protect the transhepatic track

from the trauma of multiple exchanges. The side arm allows contrast injection without having to remove the catheter or the guidewire, and a radio opaque ring marker at the tip reduces error regarding the position in the duct and during stent deployment. Sheaths allow operators to work with a 6F catheter along a safety wire (Fig. 2B) and are large enough to accommodate most standard stent delivery systems. If larger transhepatic tracks are required, gradual and gentle dilatation over ultrastiff wires may achieve this.

Biliary intervention, particularly dilatation, can be exquisitely painful and requires at the very least expert administration of conscious sedation. Electroencephalography guidance improves the accuracy of the sedation level,<sup>6</sup> but many of these cases are better performed under deep propofol sedation or general anesthesia.

### Balloon dilatation

Pneumatic dilatation of the stricture is easily performed with an angioplasty balloon in most cases. It is desirable to achieve a 10-mm diameter, but this may require multiple attempts. Angioplasty balloons vary substantially in their rated dilatation pressure as well as their maximum burst pressure. It is advisable to use a pressure inflator with an attached manometer, as it allows much more controlled inflation of the balloon as well as much higher inflation pressures than hand inflation. Tough biliary strictures may need dilatation pressures well in excess of 10 atm and even high-pressure balloons occasionally rupture during a procedure. This should be avoided. Torn balloons may cause significant trauma during removal through the transhepatic track but can usually be extracted through a transhepatic sheath without too much difficulty. It is worth noting that smaller balloons (e.g. 6–8 mm) tend to have higher burst pressures and may perform better than 10- or 12-mm balloons.

There is no consensus on how long dilatation balloons should be left inflated. One school of thought is that once the stricture is disrupted, the job is done. However, strictures vary considerably in their response, and more complex strictures may benefit from leaving the balloon inflated for several minutes.

Cutting balloons incorporating little metal blades are available for angioplasty of calcified arteries. These cause a linear incision within the endothelium, are supposed to achieve a more definitive dilatation, and result in subsequent linear rather than recurrent circumferential scarring. Their use within the bile duct has been described,<sup>7,8</sup> but their value remains to be established.

Download English Version:

<https://daneshyari.com/en/article/3310934>

Download Persian Version:

<https://daneshyari.com/article/3310934>

[Daneshyari.com](https://daneshyari.com)