



CLINICAL CASE

Endoscopic management of a delayed diagnosed foreign body esophageal perforation



Eduardo Rodrigues-Pinto*, Pedro Pereira, Guilherme Macedo

Gastroenterology Department, Centro Hospitalar São João, Porto, Portugal

Received 29 April 2013; accepted 28 October 2013

Available online 1 January 2014

KEYWORDS

Esophageal perforation;
Foreign bodies;
Endoscopy

Abstract Foreign body-induced perforation is responsible for 16.7% of esophageal perforations and may be associated with respiratory failure, sepsis or hemorrhage if delayed diagnosis and treatment. The mortality rate of esophageal perforations hovers close to 20%, especially if treatment is delayed more than 24 h. Esophageal perforation management remains controversial and treatment decisions should be individualized depending on the etiology of perforation, degree of mediastinopleural contamination, underlying esophageal disease, and overall health status of the patient. We report a case of successful endoscopic management in a delayed diagnosis of an esophageal perforation presenting with an associated peri-esophageal abscess. © 2013 Sociedade Portuguesa de Gastrenterologia. Published by Elsevier España, S.L. All rights reserved.

PALAVRAS-CHAVE

Perfuração esofágica;
Corpo estranho;
Endoscopia

Abordagem endoscópica de uma perfuração esofágica por corpo estranho com 5 dias de evolução

Resumo Perfuração por corpo estranho é responsável por 16,7% de perfurações esofágicas, podendo ser complicada por insuficiência respiratória, sépsis ou hemorragia, principalmente se houver atraso no diagnóstico e/ou tratamento. A taxa de mortalidade das perfurações esofágicas ronda os 20%, sobretudo quando o intervalo de tempo até ao tratamento ultrapassa as 24 h. A abordagem da perfuração esofágica é um tema controverso e as decisões terapêuticas devem ser individualizadas, dependendo da etiologia da perfuração, do grau de infeção mediastínico/pleural, da patologia esofágica de base e do estado geral do doente. Descrevemos um caso clínico de uma abordagem endoscópica de uma perfuração esofágica por corpo estranho com 5 dias de evolução, com abscesso peri-esofágico associado.

© 2013 Sociedade Portuguesa de Gastrenterologia. Publicado por Elsevier España, S.L. Todos os direitos reservados.

* Corresponding author.

E-mail address: edu.gil.pinto@gmail.com (E. Rodrigues-Pinto).

Introduction

Foreign body ingestion and food bolus impaction occur commonly,^{1,2} however, most ingested foreign bodies that reach the stomach pass safely through the intestinal tract. Foreign body-induced esophageal perforation is responsible for 16.7% of esophageal perforations and it has been regarded as the most serious injury of the digestive tract,³ particularly if not diagnosed and treated promptly, being associated with respiratory failure, sepsis or hemorrhage.⁴ The mortality rate of esophageal perforations hovers close to 20%, especially in cases in which treatment is delayed for more than 24h.⁵ Esophageal perforation management remains controversial and treatment decisions should be individualized depending on the duration of impaction, type of foreign body, size and perforation.⁶ Surgical primary repair is often the preferred approach, however, there may be a role for interventional endoscopy including the use of stents.^{7,8} Treatments performed before the development of mediastinitis are lifesaving in esophageal perforation patients.⁹

We report a case of successful endoscopic management in a delayed diagnosis of an esophageal perforation presenting with an associated peri-esophageal abscess.

Case report

A 57 year-old man was referred to the emergency room due to suspicion of a foreign body impaction. The patient complaints were substernal chest pain, with solid food dysphagia, fever, progressive prostration and pointed out that he had eaten chicken 5 days before. Blood chemistry revealed leukocytosis and increased C-reactive protein (147 mg/L) and there were no reported abnormalities at the chest X-ray. Computed tomography scan of the chest and neck revealed foreign body in the mid-esophagus, 18 cm below epiglottis upper edge, between left pulmonary artery and aortic arch, with suggestive signs of perforation at this level and a small (2 cm) peri-esophageal abscess (Fig. 1). There was no evidence of pneumothorax or soft tissue emphysema. After discussing with the surgeons, upper endoscopy under general anesthesia was performed, with patient consent, in the presence of a surgical team. An across located sharp-edged chicken bone (4 cm long) was identified in the mid-esophagus, with bilateral perforation of submucosa and muscular layers with the surrounding area being ulcerated bilaterally. The chicken bone was gently removed with a mouse tooth forceps (Fig. 2) after identification of the shallower end, with immediately drainage of the abscess onto the esophageal lumen. A 2 cm long midesophageal perforation was visualized. Given the lack of pulmonary symptoms and no evidence of mediastinitis, the team decided on nonsurgical management. To allow further drainage, without blocking with a stent, a nasogastric tube was placed under direct visualization. The patient was started on broad-spectrum antibiotherapy, proton pump inhibitors and total parenteral nutrition. The control esophagogram (Fig. 3) and computed tomography scan, performed in the day after, revealed a small-contained leak, with no evidence of mediastinic extravasation and no regional signs of infection. The patient was kept on total

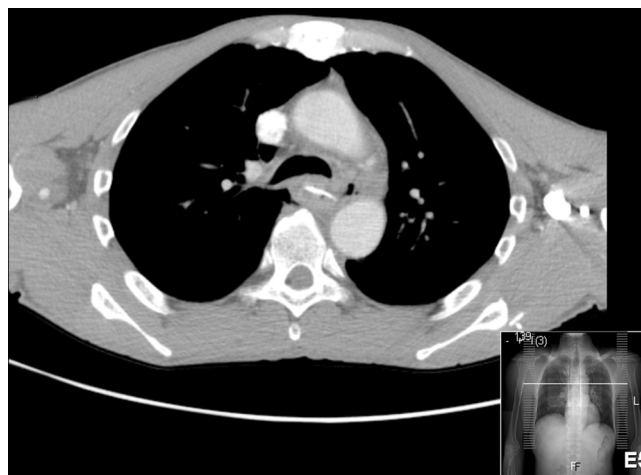


Figure 1 Chest computed tomography images. Horizontal view demonstrated the high-density foreign body lying transversely in the mid-esophagus. The ingested foreign body was about 2 cm in size. There was an abscess with 2 cm long at this level, with no evidence of mediastinitis.

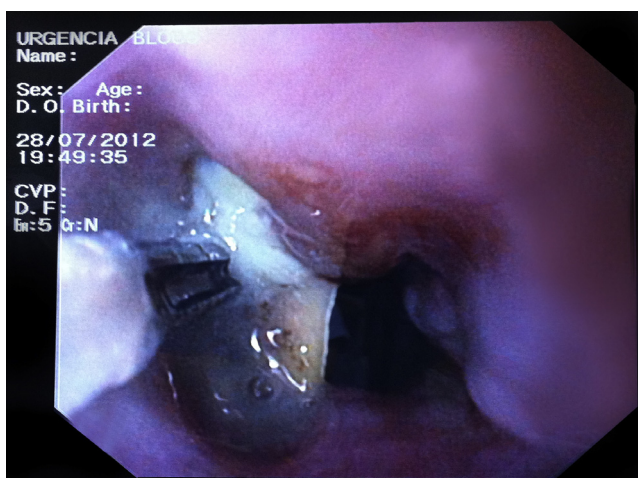


Figure 2 Upper endoscopy revealed a sharp-edge chicken bone lodged in the middle third of the esophagus.

parenteral nutrition for 8 days, started enteral nutrition on the eighth day and progressed to oral feeding on the twelfth day. The two-week control esophagogram revealed no signs of leakage. Patient improved steadily, with normalization of blood chemistry parameters of infection (C-reactive protein 3 mg/L at discharge), with no in-hospital complications and no complaints of difficulty in swallowing. He was discharged on proton pump inhibitors.

Discussion

Although the primary treatment for esophageal perforation is surgical, endoscopic therapies may play a role and be appropriate in individualized cases. Treatment depends on the etiology, site, and size of perforation, the time elapsed between perforation and diagnosis, underlying esophageal disease and the overall health status of the patient. Criteria for non-surgical treatment include perforation that is

Download English Version:

<https://daneshyari.com/en/article/3311055>

Download Persian Version:

<https://daneshyari.com/article/3311055>

[Daneshyari.com](https://daneshyari.com)