Pancreatology xxx (2015) 1–5

Contents lists available at ScienceDirect

Pancreatology

journal homepage: www.elsevier.com/locate/pan

Case report

Synchronous resection of pancreatic serous cystadenocarcinoma and liver metastasis: First reported case and review of literature

Marcel Cerqueira Cesar Machado [a,*], Gilton Marques Fonseca [b], Luciana Rodrigues de Meirelles [c], Luiz Tenorio de Brito Siqueira [d], Betina Katz [c], José Jukemura [b]

[a] Department of Clinical Emergencies, University of São Paulo School of Medicine, São Paulo 01409-001, Brazil
[b] Digestive Surgery Division, Department of Gastroenterology, University of São Paulo School of Medicine, São Paulo 05403-900, Brazil
[c] Department of Pathology, Hospital Sírio-Libanês, São Paulo 01308-050, Brazil
[d] Department of Radiology, Hospital Sírio-Libanês, São Paulo 01308-050, Brazil

ARTICLE INFO

Article history:
Available online xxx

Keywords:
Hepatectomy
Liver metastases
Pancreatectomy
Pancreatic neoplasms
Serous cystadenocarcinoma
Cystic neoplasms

ABSTRACT

Cystic neoplasms account for approximately 10–20% of all pancreatic cysts and 1% of pancreatic cancers. Serous cystadenomas are considered benign tumors with almost no malignant potential, and thus the management is typically only observation with serial imaging. According to the current World Health Organization classification, cases with distant metastases are defined as serous cystadenocarcinomas. To date, only 17 such cases with concomitant synchronous or metachronous liver metastasis have been described in the literature, and eight of these reports described treatment of secondary liver lesions. This report describes the first case of synchronous resection of pancreatic serous cystadenocarcinoma and liver metastasis in a 56-year-old female patient. The patient is currently well after 30 months of follow-up with no tumor recurrence or new metastatic liver nodules based on magnetic resonance imaging.

Introduction

Cystic neoplasms account for approximately 10–20% of all pancreatic cysts and 1% of pancreatic cancers [1]. Of these, mucinous and serous tumors of the exocrine pancreas have different biologic behaviors. Mucin-producing neoplasms, namely mucinous cystic neoplasm and intraductal papillary mucinous neoplasm (IPMN), have a well-known malignant potential, and resection is therefore more commonly indicated [2]. In contrast, serous cystadenomas are considered benign tumors with nearly no potential for malignancy, and therefore, the management is typically only observation with serial imaging [3].

Since the first reported case of histologically confirmed pancreatic serous cystadenocarcinoma by George et al. [4] in 1989, approximately 35 other cases have been reported [5–33]. Of these, only eight patients [7,12,16,17,27,32,33] had liver metastases treated with resection or microwave coagulonecrotic therapy. This article describes the first report of synchronous resection for pancreatic serous cystadenocarcinoma and liver metastasis, and discusses the benefits of liver metastasis treatment.

Case report

A 56-year-old female patient was referred to us two weeks after an episode of acute pancreatitis confirmed by clinical symptoms (abdominal pain) and laboratory tests (high levels of amylase and lipase). Her medical history included obesity and systemic arterial hypertension, with no family history of malignancies. Physical examination and laboratory tests were normal, including triglycerides, cancer antigen 19-9 and carcinoembryonic antigen. Abdominal ultrasound did not show gallbladder stones. Abdominal computed tomography (CT) demonstrated a isodense mass within the pancreatic head with slightly lobulated contours with heterogeneous arterial enhancement (Fig. 1A and B), measuring 3.6 cm, causing dilation of the main pancreatic duct up to 1.0 cm. In addition, there was a suspicious arterial enhancement nodule within the segment VIII of the hepatic dome (Fig. 1C), measuring 0.9 cm.

* Corresponding author. Department of Clinical Emergencies, LIM 51, University of São Paulo School of Medicine, Rua Peixoto Gomide, 515, Conjunto 134, 01409-001, São Paulo, SP, Brazil. Tel./fax: +5511 3289 1188.
E-mail address: mccm37@uol.com.br (M.C.C. Machado).

http://dx.doi.org/10.1016/j.pan.2015.09.009

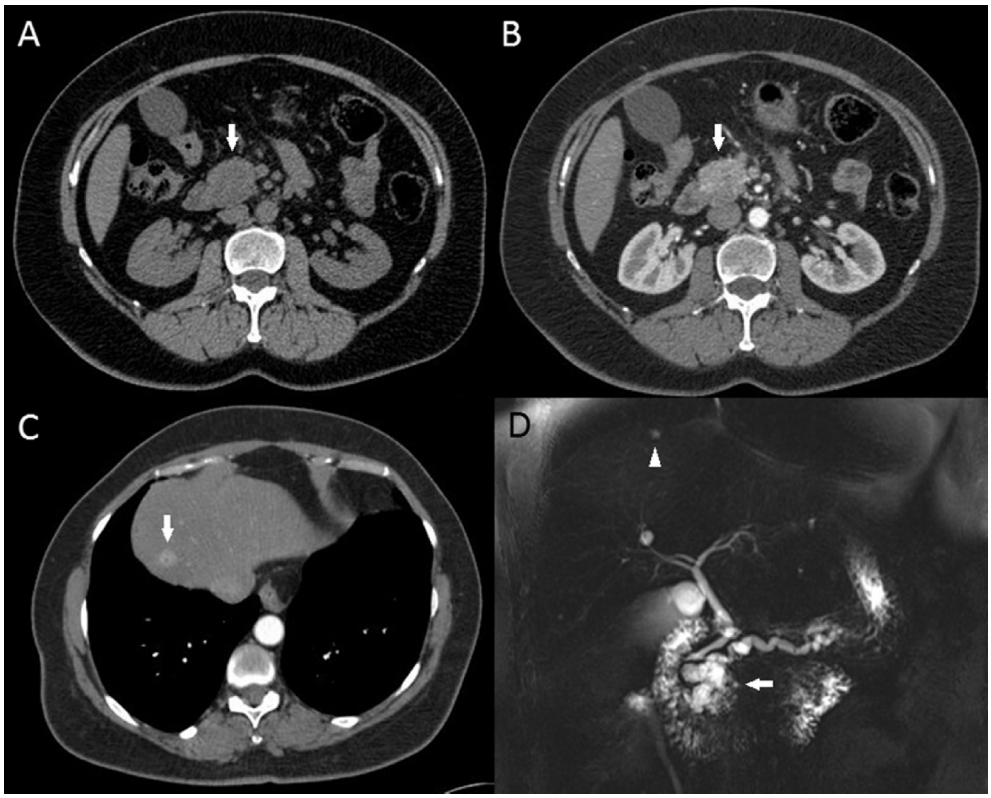

Fig. 1. A) Non-contrast CT demonstrating a lobulated isodense mass in the pancreatic head (white arrow) adjacent to the superior mesenteric vein. B) Arterial phase of the CT pancreas protocol demonstrating the heterogeneous contrast enhancement of the solid component of the pancreatic mass (white arrow). C) Arterial enhancing lesion within the segment VIII of the hepatic dome, surgical proven metastases (white arrow). D) Cholangiography MR protocol T2 weighted demonstrating the cystic component of the pancreatic lesion (white arrow) causing dilation of the main pancreatic duct, up to 1.0 cm. Within the hepatic dome, the slightly high T2 weighted focus can also be appreciated (white arrow head), surgical proven metastases.

Posteriorly, a colangiography magnetic resonance (MR) protocol was performed without gadolinium showing irregular cystic component within pancreatic lesion (Fig. 1D). Based on the imaging appearance and clinical scenario, the hypotheses of pancreatic neuroendocrine tumor with cystic degeneration with single liver metastases or, less likely, malignant intraductal papillary mucinous neoplasia (IPMN) were considered. Surgical treatment was therefore indicated.

Laparotomy revealed a mass in the head of the pancreas with a peripheral liver nodule. An intraoperative ultrasound showed no other suspect nodules in the liver. The patient underwent a pancreatoduodenectomy and resection of the liver lesion in segment 8. The pancreatic margin was free of malignancy as determined by a frozen biopsy. The patient had delayed gastric emptying, and was treated with a nasogastric tube and discharged 13 days after the operation.

On gross pathologic examination, a nodular and well-circumscribed tumor was observed in the head of the pancreas, measuring 3.6 × 3.0 × 2.8 cm (Fig. 2A). The cut surface revealed a honeycomb pattern with thin-walled cysts separated by delicate septa. Compartments, measuring from 0.5 to 2.5 cm in diameter, were filled with numerous microscopic cysts. The boundaries of this lesion were regular, expansive, and there was no macroscopic evidence of invasion of adjacent structures. The surgical margin and 19 regional lymph nodes showed no neoplastic involvement. Histology revealed microcysts separated by fibrotic stroma in the pancreatic mass lined by a single layer of uniform cuboidal cells with clear cytoplasm and centrally located round nuclei without atypical or mitotic activity (Fig. 2B and C). There was no microscopic evidence for perineural, vascular or stromal invasion. Immunohistochemical analyses were positive for keratin 7 and 35BH11, and negative for vimentin and CD10. The adjacent pancreatic parenchyma showed mild acinar atrophy and focal dilatation of small ducts.

The hepatic lesion measured 1.0 × 0.8 × 0.6 cm and histologic evaluation showed the same morphology as the pancreatic tumor (Fig. 2D). There were 19 lymph nodes resected and all of them were negative to metastatic disease. These findings were consistent with serous microcystic adenoma of the pancreas and the malignant nature of the tumor was suspected by the presence of synchronous hepatic lesion. The final diagnosis was serous cystadenocarcinoma with liver metastasis.

The patient had an adenocarcinoma of the uterus 18 months after the pancreatectomy and underwent a pan-hysterectomy. She remains well after 30 months of follow-up, and magnetic resonance imaging showed no tumor recurrence or new metastatic liver nodules.

Discussion

The estimated prevalence of cancer among serous cystic tumors is 3%, though this value may be overstated due to the greater impetus for reporting rare cases than for reporting common benign cystadenomas [17]. However, malignant serous cystic neoplasms are histologically indistinguishable from serous cystadenoma [19], and both lesions appear as multiloculated masses lined by cuboidal

Please cite this article in press as: Machado MCC, et al., Synchronous resection of pancreatic serous cystadenocarcinoma and liver metastasis: First reported case and review of literature, Pancreatology (2015), http://dx.doi.org/10.1016/j.pan.2015.09.009