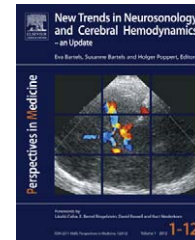




ELSEVIER
URBAN & FISCHER

Bartels E, Bartels S, Poppert H (Editors):
New Trends in Neurosonology and Cerebral Hemodynamics – an Update.
Perspectives in Medicine (2012) 1, 82–85

journal homepage: www.elsevier.com/locate/permed



Threedimensional imaging of carotid arteries: Advantages and pitfalls of ultrasound investigations

Edoardo Vicenzini*, Stefano Pro, Gaia Sirimarco, Patrizia Pulitano,
Oriano Mecarelli, Gian Luigi Lenzi, Vittorio Di Piero

Stroke Unit – Neurosonology, Neurophysiology Unit, Department of Neurology and Psychiatry, Sapienza University of Rome, Italy

KEYWORDS

3D ultrasound;
Carotid arteries
imaging;
Extracranial carotid
arteries tortuosity
and kinking;
Carotid stenosis

Summary

Objectives: To describe normal and pathological findings with three-dimensional (3D) ultrasound of the carotid bifurcation.

Methods: Patients admitted to our ultrasound laboratory for vascular screening were submitted to standard carotid duplex and to 3D ultrasound reconstruction of the carotid bifurcation. Volume 3D scans were performed manually, on the axial plane, and the software presented the volume rendering from the inward blood flow signal detected with the Power Color Mode.

Results: Forty normal subjects, 7 patients with caliber alterations (4 carotid bulb ectasia and 3 internal carotid lumen narrowing), 45 patients with course variations (tortuosities and kinkings) and 35 patients with internal carotid artery stenosis of various degrees have been investigated.

Conclusions: 3D ultrasound is a feasible technique. It can improve carotid axis general imaging through a global image presentation “at a glance”, visualizing caliber variations and vessels course. Imaging of stenosis from inward flow can be provided, but complete stenosis characterization requires the assessment of plaque morphology and vessel wall.

© 2012 Elsevier GmbH. Open access under [CC BY-NC-ND license](https://creativecommons.org/licenses/by-nc-nd/4.0/).

Introduction

Several specialists use three-dimensional (3D) ultrasound (US) as adjuvant imaging technique in their clinical practice, from cardiologists to gynecologists [1–5]. The virtual 3D image presentation may be useful also for surgeons, to better study anatomical boundaries of the structures to be submitted to surgical procedures [6,7]. For carotid arteries, it has been applied to study carotid plaque morphology, surface and volume during atherosclerosis progression [8–13].

Recently we have published the possibility of 3D US bifurcation imaging in other conditions than carotid stenosis [14], easily visualizing bifurcation anatomy changes of the caliber and vessels course modifications.

Materials and methods

Patients admitted to our US laboratory for vascular screening were submitted to standard carotid duplex and to 3D US reconstruction of the carotid bifurcation. Forty normal subjects, 7 patients with caliber alterations (4 carotid bulb ectasia and 3 internal carotid lumen narrowing), 45 patients with course variations (tortuosities and kinkings) and 35 patients with ICA stenosis of various degrees have been investigated.

* Corresponding author at: Department of Neurology and Psychiatry, Sapienza University of Rome, Viale dell’Università 30, 00185 Rome, Italy. Tel.: +39 06 49914705; fax: +39 06 49914194.

E-mail address: edoardo.vicenzini@uniroma1.it (E. Vicenzini).

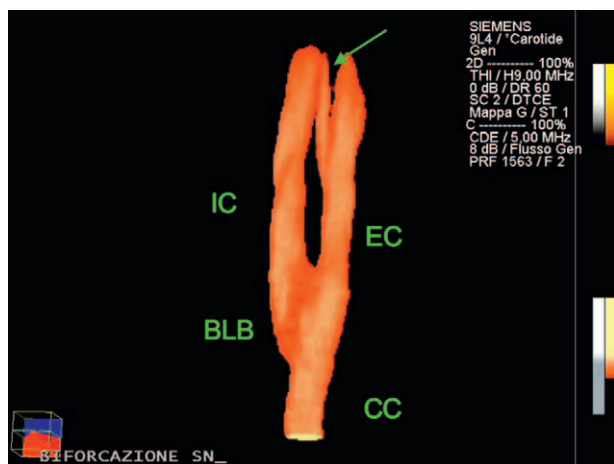


Figure 1 US 3D reconstruction of normal bifurcation. IC: internal carotid artery; EC: external carotid artery; BLB: carotid bulb; CC: common carotid artery. Green arrow indicates the superior thyroidal artery.

3D US data acquisition

The Siemens S2000 US system with high frequency linear probes (9, 14 and 18 MHz) and proprietary 3D/4D reconstruction software (v 1.6) have been used.

3D volume scans were recorded manually. After fixing the proximal tract of the common carotid artery (CC) in the center of the display in the transversal plane, a test axial scanning was performed, from proximal CC to distal internal carotid artery (ICA) – at approximately 1 cm per second speed – to adjust the visualization. The 3D ultrasound software was then switched on to record the volume scan: the Power box was set to the orthogonal 90° angle position; Pulse Repetition Frequency (PRF), color gain and color persistence were adjusted during a second test axial scan, in order to reduce artifacts due to the inward flow color signal overlapping the vessel wall and to minimize color “flashing” due to the blood pulsatility. The features of the software “axial reconstruction” and “medium resolution” – that is set for a length of 10 cm to be scanned in 12 s – were selected. Data acquisition was then started and stopped manually; a bar control displayed on the screen the feedback for maintaining a constant straight direction and scan velocity. At the end of the scan, the 3D ultrasound “volume rendering” reconstruction of the acquired volume set was started on the system. After the global 3D image presentation, B-Mode imaging was excluded and Color Magnification (Color Priority) adjusted to optimize the final visualization of the vessels.

Results

Visualization of the normal bifurcation

Threedimensional US reconstruction in normal subjects allows a good visualization of the carotid bifurcation. In Fig. 1 (Clip 1), an example is reported: all the extracranial carotid arteries are easily identifiable (CC: common carotid artery; IC: internal carotid artery; EC: external carotid

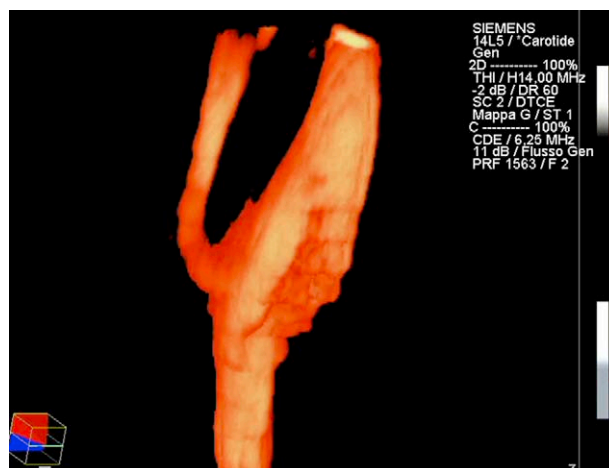


Figure 2 US 3D reconstruction of carotid bulb ectasia.

artery; green arrow: superior thyroidal artery), with the possibility of rotating the image through different planes.

Caliber variations

Carotid bulb ectasia

The vessel dilatation, characterized by a fusiform enlargement (usually 1–1.5 cm of antero-posterior diameter), usually involving the distal tract of the common carotid artery and extending through the bulb to the internal carotid artery origin, can be easily recognized. Moreover, the 3D reconstruction, rotating in the different planes, allows a better global identification of the anatomy (Fig. 2). However, the reconstruction images have always to be considered with caution for final diagnostic decisions, as flow disturbances can cause several artifacts in the post-processing image reconstruction: final 3D pictures cannot be considered alone and without the previous or concomitant mandatory analysis of the bidimensional images.

Course variations – tortuosities and kinkings

Extracranial vessels course abnormalities are frequent and generally asymptomatic in the general population [15]. According to their angle in respect to the vessel, they can be classified in “tortuosities” and “kinkings”, when changes in the vessel course are greater than 90°. Even though these alterations are asymptomatic and without clinical relevance in the normal subject, tortuosities and kinkings have to be identified prior to surgical procedures, since they may hinder – for example – the intravascular positioning of a stent, while the anatomical approach and clamping of the internal carotid artery may be easier during endarterectomy [16]. Bidimensional standard US imaging with Duplex, Color and Power Doppler easily reveal the changes of the blood flow direction according to the vessel direction change. While in the bidimensional images it is usually necessary to repeatedly correct the color box insonation angle or to adjust the probe orientation to obtaining optimal complete vessel recognition, the 3D reconstruction can be of help to gain the whole visualization “at a glance” [to view the figure, please visit the online supplementary file].

Download English Version:

<https://daneshyari.com/en/article/331784>

Download Persian Version:

<https://daneshyari.com/article/331784>

[Daneshyari.com](https://daneshyari.com)