



# The Brazilian Journal of INFECTIOUS DISEASES

[www.elsevier.com/locate/bjid](http://www.elsevier.com/locate/bjid)



## Case report

# *Aspergillus niger* – a possible new etiopathogenic agent in Tinea capitis? Presentation of two cases

Anastasiya Atanasova Chokoeva<sup>a,\*</sup>, Liliya Zisova<sup>a</sup>, Kristina Chorleva<sup>b</sup>,  
Georgi Tchernev<sup>c</sup>

<sup>a</sup> Department of Dermatology and Venereology, Medical University of Plovdiv, Plovdiv, Bulgaria

<sup>b</sup> University Clinic of Dermatology and Venereology, University Hospital “St. George”, Medical University of Plovdiv, Plovdiv, Bulgaria

<sup>c</sup> Polyclinic for Dermatology and Venereology, University Hospital “Lozenetz”, Sofia, Bulgaria

## ARTICLE INFO

### Article history:

Received 28 November 2015

Accepted 25 January 2016

Available online 7 March 2016

### Keywords:

Tinea capitis

Children

Etiology

Molds

## ABSTRACT

Tinea capitis is generally considered as the most frequent fungal infection in childhood, as it accounts for approximately 92% of all mycosis in children. The epidemiology of this disease varies widely ranging from antropophilic, zoophilic, and geophilic dermatophytes, as the main causative agent in different geographic areas, depending on several additional factors. Nowadays, the etiology is considered to vary with age, as well with gender, and general health condition. The former reported extraordinary Tinea capitis case reports have been replaced by original articles and researches dealing with progressively changing patterns in etiology and clinical manifestation of the disease. This fact is indicative that under the umbrella of the well-known disease there are facts still hidden for future revelations. Herein, we present two rare cases of Tinea capitis in children, which totally differ from the recently established pattern, in their clinical presentation, as well as in the etiological aspect, as we discuss this potential new etiological pattern of the disease, focusing on our retrospective and clinical observation. Collected data suggest that pathogenic molds should be considered as a potential source of infection in some geographic regions, which require total rationalization of the former therapeutic conception, regarding the molds' higher antimicrobial resistance compared to dermatophytes. Molds-induced Tinea capitis should be also considered in clinically resistant and atypical cases, with further investigations of the antifungal susceptibility of the newest pathogens in the frame of the old disease. Further investigations are still needed to confirm or reject this proposal.

© 2016 Elsevier Editora Ltda. This is an open access article under the CC BY-NC-ND license. (<http://creativecommons.org/licenses/by-nc-nd/4.0/>)

## Introduction

Tinea capitis (TC) is generally considered as the most frequent fungal infection in childhood, as it accounts for approximately

92% of all mycosis in children.<sup>1</sup> The ringworm of the scalp is much less common seen in adults, as its incidence beyond childhood is considered as sporadic.<sup>1</sup> It is well-known and that TC is caused by dermatophytes, which is a scientific label for a group of three genera of fungi: *Microsporum*,

\* Corresponding author.

E-mail address: [assia.chokoeva@abv.bg](mailto:assia.chokoeva@abv.bg) (A.A. Chokoeva).

<http://dx.doi.org/10.1016/j.bjid.2016.01.002>

1413-8670/© 2016 Elsevier Editora Ltda. This is an open access article under the CC BY-NC-ND license. (<http://creativecommons.org/licenses/by-nc-nd/4.0/>)

*Epidermophyton* and *Trichophyton*.<sup>2</sup> The epidemiology of the disease varies widely ranging from antropophilic, zoophilic, and geophilic dermatophytes; the “leader” in Europe still remains *Microsporum canis*.<sup>3</sup> Nonetheless, the incidence of other antropophilic and zoophilic dermatophytes, *Trichophyton tonsurans* mainly in the UK, *T. tonsurans* and *Microsporum audouinii* in France are progressively increasing.<sup>1</sup> Significant interchange of the etiological agents from anthroponoses to zoonoses is observed in contemporary China, as the authors pointed the economic development and urbanization of cities as the main reason for that.<sup>4</sup> The earlier human-to-human transmission mode has been replaced by the pets-to-human mode as the source of infection, according to same study.<sup>4</sup>

Despite the new trends in etiology, contradictory discoveries are also observed in gender distribution of the disease.<sup>5</sup> The well-known assertion that TC dominantly affects the female gender, is now replaced by the perception that the gender distribution actually varies depending on the isolated pathogen.<sup>1,3</sup> For example, if the TC is caused by *Trichophyton* genus, there is no significant difference in sexual predilection in children; the frequency of isolation of *M. audouinii* is up to five-fold higher in males compared to female young patients.<sup>5</sup> Nevertheless, *M. canis* is significantly more frequently seen in male patients, regardless of age.<sup>1,3</sup> Significantly higher incidence of the infection is reported among patients of African American origin, as a support of the new trends and changing patterns of the disease.<sup>6</sup>

The former reported extraordinary TC case reports have been replaced by original articles and researches dealing with progressively changing patterns in etiology and clinical manifestation of the disease. This fact is indicative that under the umbrella of the well-known disease there are facts still hidden for future revelations.

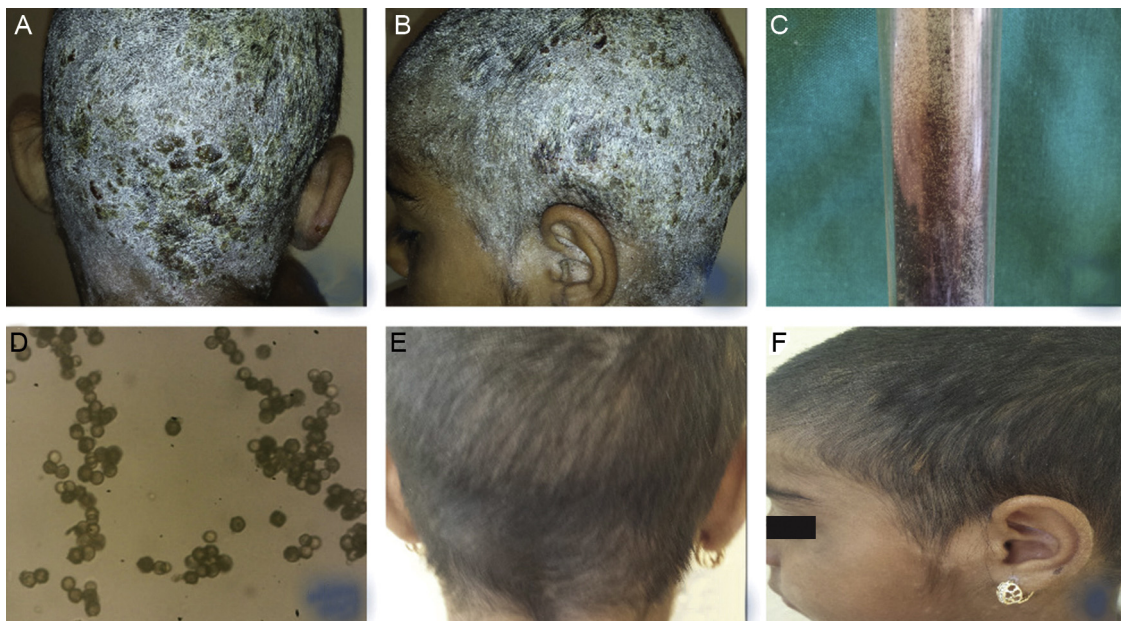
Herein, we present two rare cases of TC in children, which totally differ from the recently established pattern, their clinical presentation, as well as etiological aspects, as we discuss this potential new etiological pattern of the disease focusing on our retrospective and clinical observation.

### Case report 1

A 9-year-old female patient was presented to the dermatology department with a one-year history of complains of diffuse scalp desquamation and severe itching. Initially, complains were manifested by solitary rounded scaly lesion, which was treated topically with different substances that the patient’s mother could not specify. Partial relief had been achieved, but only temporally. Gradually, the desquamation engulfed the entire scalp in the form of a helmet of white scales. The family history was negative for dermatologic disease and neither comorbidities nor co-medication was reported.

Clinically, the whole scalp was covered with white desquamation with multiple yellowish crusts with areas with yellow exudation, single follicular papules and disseminated exudative vesicles. The neck and ear area was also affected with white desquamation. Hair loss was not observed (Fig. 1A, B).

Laboratory blood tests were within normal range, except for increased leukocyte count (19.4) and ESR (40 mm/h). Microbiological examination of crust exudate revealed *Staphylococcus aureus*. Direct mycological examination with KOH was negative. Histopathological evaluation excluded psoriasis and did not reveal any specific changes beyond dermatitis. Mycological examination on Sabouraud agar was still pending. Local and systemic antibiotic therapy was initiated with cefuroxime 250 mg/5 mL in dosage 6 mL, bid. Administration of 1 mg/mL



**Fig. 1 – (A, B) Clinical presentation of TC, caused by *Aspergillus niger* in a 9-year-old female patient – diffuse white desquamation with multiple yellowish crusts with areas with yellow exudation, single follicular papules, and disseminated exudative vesicles, without hair loss. (C, D) Growth of *Aspergillus niger* established on mycological examination on Sabouraud agar and direct microscopic evaluation. (E, F) Clinical presentation within the regimen with Terbinafine, dosage 125 mg per day, after antibiotic and keratolytic therapy.**

Download English Version:

<https://daneshyari.com/en/article/3343700>

Download Persian Version:

<https://daneshyari.com/article/3343700>

[Daneshyari.com](https://daneshyari.com)