




Available online at www.sciencedirect.com

ScienceDirect

journal homepage: www.e-jmii.com



CASE REPORT

A rare nonfatal presentation of disseminated *Chromobacterium violaceum* sepsis



Ashwin Rajendra Saboo, Ramaa Vijaykumar, Sushma Uttam Save, Sandeep Bhalchandra Bavdekar*

Department of Pediatrics, TN Medical College and BYL Nair Hospital, Mumbai Central, Mumbai 400008, India

Received 19 March 2012; received in revised form 20 August 2012; accepted 8 November 2012
Available online 4 February 2013

KEYWORDS

Cardiogenic shock;
Chromobacterium;
G6PD deficiency;
Hepatic abscess;
Immunodeficiency

We present a case of disseminated *Chromobacterium violaceum* sepsis with multiple liver and splenic abscesses presenting with skin lesions and cardiogenic shock, and later diagnosed to have chronic granulomatous disease. The patient was treated with prolonged antimicrobial therapy, after which she recovered and remained asymptomatic on follow-up.

Copyright © 2012, Taiwan Society of Microbiology. Published by Elsevier Taiwan LLC. All rights reserved.

Introduction

Chromobacterium violaceum, a common inhabitant of soil and water, is a facultative anaerobic Gram-negative saprophytic bacillus, found mainly in tropical and subtropical climates.^{1,2} Only five childhood cases of invasive chromobacterial infection have been reported from the Indian subcontinent, with three of them showing complete recovery.^{3,4} Disseminated *C. violaceum* sepsis is associated with a high mortality rate.^{5,6} Inability to recognize this infective organism early because of varied presentation, its

peculiar antibiotic sensitivity pattern, and high probability of relapse due to administration of a routine short course (7–14 days) of antibiotics, have been the bane of management of this infection. Here we report an unusual and aggressive, yet nonfatal presentation of *C. violaceum* sepsis in a child, resulting in a new diagnosis of chronic granulomatous disease (CGD).

Case report

An 11-year-old girl presented with fever for 4 days and excruciating limb and abdominal pain for 1 day. There was no history of any septic focus. The child had suffered an injury to the dorsum of the left foot 7 days earlier and she had waded through stagnant water. On examination, she

* Corresponding author. 9, A2 Worli Sea-Side CHS, Pujari Nagar, KAG Khan Road, Worli, Mumbai, Maharashtra, India.
E-mail address: sandeep.bavdekar@gmail.com (S.B. Bavdekar).

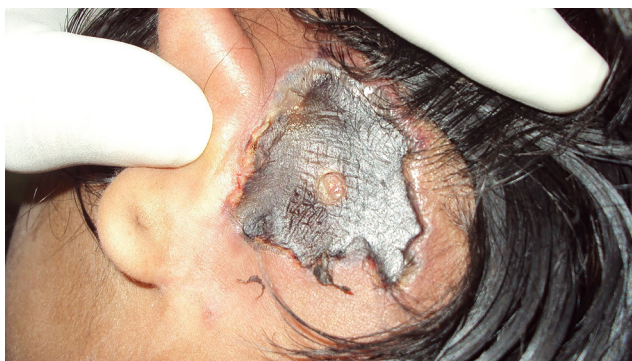

Figure 1. A 4 cm × 5 cm tender violaceous and necrotic lesion over the left postauricular area with formation of an eschar, suggestive of ecthyma gangrenosum.

was conscious, in immense abdominal pain, had gallop rhythm (heart rate 160/min), normal systemic oxygenation (on room air) and a blood pressure of 90/70 mmHg. She had multiple ecchymotic lesions with violaceous hue over the arms, trunk and back; several vesicular lesions over the arms and back, a 3 cm × 3 cm violaceous lesion over the dorsum of the left foot, which appeared after admission, eventually evolving into a necrotic patch, and a 4 cm × 5 cm tender violaceous and necrotic lesion over the left postauricular area with formation of an eschar, suggestive of ecthyma gangrenosum (Fig. 1). She had guarding and tenderness over the abdomen, with a soft, tender liver palpable 6 cm below the right costal margin (span 11 cm). The spleen was just palpable.

Within 2 hours of admission, the child's condition suddenly deteriorated with the advent of hypotensive shock (heart rate 170/min, respiratory rate 40/min, blood pressure 70/40 mmHg) with respiratory failure. Intravenous (i.v.) administration of normal saline, given as a part of fluid resuscitation resulted in an increase in the liver size and central venous pressure and persistent low mixed venous oxygen saturations (<60%). Chest radiograph demonstrated cardiomegaly (cardiothoracic ratio: 0.6) with bilateral pulmonary infiltrates. The arterial blood gas analysis demonstrated hypoxemia (PaO₂—50 mmHg) with normal hemoglobin saturation. Complete hemogram (Table 1) showed leukopenia with neutrophilic predominance, thrombocytopenia and anemia. In view of the features of cardiogenic shock,⁷ along with extensive cutaneous manifestations, in a febrile

child, a possible diagnosis of *Pseudomonas* sepsis was considered. She was mechanically ventilated and treated with cardiotoxic drugs and decongestive measures (i.v. furosemide 2 mg/kg/day). Antimicrobial treatment, consisting of i.v. piperacillin—tazobactam (300 mg/kg/day) and gentamicin (5 mg/kg/day), was administered for 3 weeks. Blood culture and scrapings from the postauricular lesion along with the one over the right foot later grew *C. violaceum* that was sensitive to erythromycin, piperacillin—tazobactam, gentamicin, amikacin, ciprofloxacin, co-trimoxazole, meropenem, and imipenem. As the child had persistent fever spikes, i.v. ciprofloxacin (20 mg/kg/day) was added on Day 3. Computed tomography scan of the abdomen on the 11th day showed multiple nonenhancing hypodense lesions in the liver (largest 2 cm × 2 cm) and spleen (largest 1.6 cm × 1.2 cm), suggestive of abscesses (Fig. 2). Therapy with ciprofloxacin was continued for a total of 10 weeks (i.v. for 5 weeks followed by oral for 5 weeks), until complete resolution of abscesses. Levels of amylase, aspartate, and alanine transaminase in serum were normal, but those of C-reactive protein were elevated (Table 1). The Tzanck smear from the vesicular lesions did not show varicella inclusions.

On Day 2 (36 hours after admission), she developed supraventricular tachycardia not responding to multiple doses of i.v. adenosine (0.1 mg/kg/dose i.v.), but improved, with continued decongestive measures, over the next 12 hours (i.v. furosemide 2 mg/kg/day), further corroborating the diagnosis of cardiogenic shock.⁸ The patient showed gradual improvement in her clinical status, and ventilatory and cardiotoxic support were gradually withdrawn on 10th day after admission. Chest radiograph showed improvement over 15 days. Two-dimensional echocardiography, on Day 13, showed a structurally normal heart with normal ejection fraction. The child became afebrile from the 14th day of admission and the skin lesions healed with scab formation and scarification. The hepatic abscesses gradually responded with weekly ultrasound scans showing progressive reduction in size and numbers. On further work-up, the child was found to be suffering from chronic granulomatous disease, CGD (nitroblue tetrazolium test positive neutrophils 0%, reference value >90%; confirmed by dihydrorhodamine flow cytometry). ELISA for HIV antibodies was negative and G6PD levels were normal. Her elder sister was also diagnosed to have CGD on the basis of similar test results. Neither of the parents had CGD. Both siblings were

Table 1 Blood investigations

	Reference value	Admission	Day 11 after admission	Day 15 (discharge)
Hemoglobin (g/L)	110–180	96	108	110
Total WBC count (×10 ⁹ /L)	4.0–11.0	3.0	6.7	9.7
Platelet count (×10 ⁹ /L)	120–500	89	190	215
AST (U/L)	5–40	98	72	40
ALT (U/L)	5–40	83	66	34
Serum amylase (U/L)	30–100	50		
C-reactive protein (mg/L)	0–5	300	82	
Prothrombin Time (s)	11	12		

ALT = alanine transaminase; AST = aspartate transaminase; WBC = white blood cell.

Download English Version:

<https://daneshyari.com/en/article/3377895>

Download Persian Version:

<https://daneshyari.com/article/3377895>

[Daneshyari.com](https://daneshyari.com)