



Contents lists available at ScienceDirect

Asian Pacific Journal of Tropical Medicine

journal homepage: www.elsevier.com/locate/apjtm



Document heading doi: 10.1016/S1995-7645(14)60049-3

Effect of low intensity pulsed ultrasound on repairing the periodontal bone of Beagle canines

Xiao-Qi Gu¹, Yong-Mei Li¹, Jing Guo¹, Li-Hua Zhang¹, Dong Li¹, Xiao-Dong Gai^{1,2*}

¹Oral Medical School of North China University, Jilin 132011, China

²Medical School of North China University, Jilin 132011, China

ARTICLE INFO

Article history:

Received 10 December 2013

Received in revised form 15 January 2014

Accepted 15 February 2014

Available online 20 April 2014

Keywords:

LIPUS

Periodontal bone defect

Repair

ABSTRACT

Objective: To investigate the repairing effect of low intensity pulsed ultrasound (LIPUS) on the Beagle canines periodontal bone defect. **Methods:** A total of 12 Beagle dogs with periodontal bone defect model were randomly divided into control group, LIPUS group, guided tissue regeneration (GTR) group and LIPUS+GTR group, with three in each. After completion of the models, no other proceeding was performed in control group; LIPUS group adopt direct exposure to radiation line LIPUS processing 1 week after modeling; GTR group adopted treatment with GTR, following the CTR standard operation reference; LIPUS+GTR group was treated with LIPUS joint GTR. Temperature change before treatment and histopathological change of periodontal tissue after repair was observed. **Results:** There was no significant difference in temperature changes of periodontal tissue between groups ($P>0.05$). The amount and maturity of LIPUS+GTR group were superior to other groups; new cementum, dental periodontal bones of GTR group were superior to the control group but less than LIPUS group; new collagen and maturity of the control group is not high relatively. **Conclusions:** LIPUS can accelerate the calcium salt deposition and new bone maturation, thus it can serve as promoting periodontal tissue repair, and shortening the periodontal tissue repair time.

1. Introduction

Periodontal disease is a chronic inflammatory periodontal disease with high incidence, periodontal disease often causes dental periodontal bone defects, support tissue and periodontal attachment are damaged, eventually lead to tooth loss[1–3]. Current clinical treatments of periodontal bone defect mainly include: bone graft, guided tissue regeneration (GTR) and guided bone regeneration, etc[4]. Early stage of periodontal tissue regeneration technique mainly create regenerative environment, increase the cells at defective places, enhance cell proliferation, differentiation and regeneration[5–7]. But when periodontal tissue defect area is large, clinical treatment effect would be poor due to lack of tissue regeneration[8]. LIPUS is a

safe noninvasive treatment, it can accelerate bone and soft tissue repairment. Studies have shown that[9], LIPUS has a promoting effect for dental periodontal bone defect treatment. Based on LIPUS potential biological effect and the theory of periodontal tissue regeneration, the authors establish a Beagle canines periodontal ipads defect model, observation LIPUS joint BGR to defect tissue repair effect, provide reference for clinical LIPUS auxiliary treatment of periodontal disease.

2. Materials and methods

2.1. Experimental animals

A total of 12 Beagle male dogs, aged 1–1.5 years old, were purchased from Animal Experiment Center of Jilin University. They were healthy, weighting 10 to 15 kg. Complete jaw teeth on both sides were chosen for experimental tooth, with normal periodontal and periodontal

*Corresponding author: Xiao-Dong Gai, Ph.D., Professor, Deputy Director, Oral Medical School of North China University, Jilin 132011, China.

Tel: 15947964716

E-mail: guxqitg@163.com

Funding project: It is supported by National Science Foundation (Grant no.81170632).

bones tissue, no hyperemia or swelling gums. Experiments on animals process strictly followed the Regulations on Administration of Experimental Animals.

2.2. Instrument and reagent

Polytetrafluoro ethylene (ePTFE) ultrasonic acoustic membrane, LIPUS therapeutic apparatus were provided by the Ultrasonic Medical Engineering Research Center; DM6801A thermocouple temperature meter was provided by Shenzhen Victory Instrument Plant. S-3000N scanning electron microscope was HITACHI company (Japan). Sleep new II injection and diazepam injection, kang pat medical glue, medical ultrasonic coupling agent were provided by the Southwest Pharmaceutical co., Ltd.

2.3. Modeling

Experimental animals with general anesthesia underwent the buccal teeth gingival sulcus incision along the first premolar. The mucoperiosteal flap was turned over to a third range of tip, 5 mm×5 mm bone defect was ground at 4 mm under glaze surface to cementum surface. Periodontal membrane was scraped. Histological markers was made on the edge of bone defect at the tip; location markers was made on the tip surface at 10 mm distance from defects. Fixing ePTFE film adhesion was implanted on the surface of bone defects, and no ePTFE membrane in blank control group. Mucosal flap suture was reset. Postoperatively penicillin sodium 800 000 U was injected in muscle for days, stitches was taken out after a week when the modeling was set up, High viscosity of sugar pap was given for 2 months.

2.4. Methods

A total of 12 Beagle dogs with periodontal bone defect model were randomly divided into control group, LIPUS group, GTR group and LIPUS+GTR group, with three in each. After completion of the models, control group had no other processing; LIPUS group adopt direct exposure to radiation line LIPUS processing 1 week after modeling, probe position reference was tagged along the line placement, LIPUS parameters: ISATA 60 mw/cm²; Frequency of 1.5 MHz; Pulse width 200 μs; Repetition rate 1.0 KHz; The processing time was 20 min/d; GTR group adopted treatment with GTR, following the CTR standard operation reference; LIPUS+GTR group was treated with LIPUS joint GTR.

2.5. Index observation

Thermal bimetallic temperature meter was used to measure LIPUS surface temperature before processing, average the defect values was measured at 3 positions including the

near, middle and far, then the histopathology change of periodontal tissue after repair was observed.

2.6. Statistical analysis

Data was analyzed using SPSS12.0, and expressed as mean±sd. *t* test was adopted, *P*<0.05 was considered as statistically significant.

3. Results

3.1. Temperature change

After treatment temperature change of control group was (0.07±0.73) °C, LIPUS group was (0.77±1.08) °C, GTR group was (-0.31±1.18) °C, LIPUS+GTR group was (0.43±0.72). There was no significant differences in temperature change between 4 groups after treatment (*P*>0.05).

3.2. Defect tissue change

Mucosal flap adhesion was visible in the control group, defect area had been filled by the organization, with soft connective tissue attaching to the surface; in LIPUS group, GTR group and LIPUS+GTR group, after mucosal flap opened, ePTFE membrane was observed with combination to new tissue with loose connection, and it was easy to remove. Defect parts had been filled by regeneration tissue, which was softer than normal bone tissue (Figure 1).

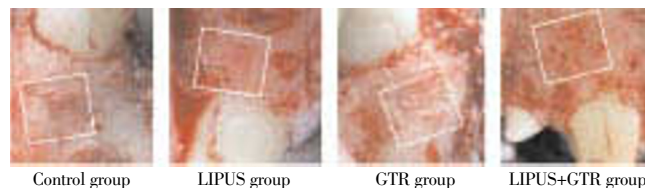


Figure 1. Defect tissue observation of four groups after treatment.

3.2. Histopathology observation of periodontal tissue after treatment

Histopathology of Beagle periodontal tissue was normally structure clear, mature collagen structure, mature lamellar bone, Haversian canal, and plate lamellar bone with Masson dyeing in red and blue were visible in periodontal bones, as shown in Figure 2; Control group was observed with group new bone in bone defects area, with majority of cartilage collagen fiber, red and blue Masson staining, part of the new tooth bone grows inward along the defect rim, as shown in Figure 3; in LIPUS group, new cementum growing along the defects was visible on the surface, periodontal membrane was rich in blood vessels, new osteoblasts along the bone edge and mature collagen structure were visible, Masson

Download English Version:

<https://daneshyari.com/en/article/3455693>

Download Persian Version:

<https://daneshyari.com/article/3455693>

[Daneshyari.com](https://daneshyari.com)