

# Evaluation of the Blood Film



Terry W. Campbell, MS, DVM, PhD

## KEYWORDS

• Blood • Cells • Hematology • Mammal • Bird • Reptile • Amphibian • Fish

## KEY POINTS

- A single drop of blood can provide valuable information in the assessment of the exotic animal patient by the examination of a properly prepared blood film.
- A blood film will reveal important erythrocyte abnormalities, such as changes in cell shape and color, presence of inclusions, and, in the case of lower vertebrates, changes in the position of the cell nucleus.
- A differential leukocyte count and detection of white blood cell abnormalities can be obtained from a stained blood film.
- Thrombocyte numbers and morphology are discerned from properly prepared blood films, in addition to mammalian platelets.
- A blood film can also reveal the presence of blood parasites and other infectious agents.

Evaluation of cell morphology in the stained blood film is an important part of hematology and the evaluation of the exotic animal patient. Often, the stained blood film is the only component of hematology available to the exotic animal veterinarian because of a small sample size. A single drop of blood can provide valuable information in the assessment of the patient.

A properly prepared blood film should not extend to the edges of the slide and will have a thick body that tapers into a feathered edge (**Fig. 1**). The best cell morphology lies just behind the feathered edge in the monolayer area. It is difficult to examine cells in the thick part of the blood film because they superimpose on each other, and the leukocytes appear rounded and not able to expand and flatten out (making them all resemble lymphocytes). Examination of cells in the feathered-edge area will reveal artifacts such as ruptured cells and, in the case of mammalian blood films, lack of erythrocyte central pallor.

A blood film made from a drop of non-anticoagulated blood placed on a slide immediately after collection is preferred over a blood sample exposed to an anticoagulant.

---

This article originally appeared in *Veterinary Clinics of North America: Exotic Animal Practice*, Volume 18, Issue 1, January 2015.

Department of Clinical Sciences, College of Veterinary Medicine and Biomedical Sciences, Colorado State University, 300 West Drake Road, Fort Collins, CO 80523, USA

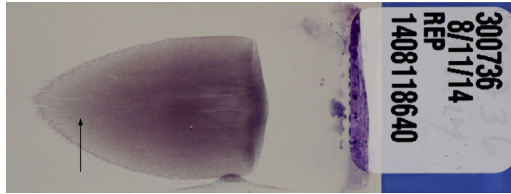
*E-mail address:* [Terry.Campbell@colostate.edu](mailto:Terry.Campbell@colostate.edu)

Clin Lab Med 35 (2015) 703–721

<http://dx.doi.org/10.1016/j.cll.2015.05.016>

[labmed.theclinics.com](http://labmed.theclinics.com)

0272-2712/15\$ – see front matter © 2015 Elsevier Inc. All rights reserved.

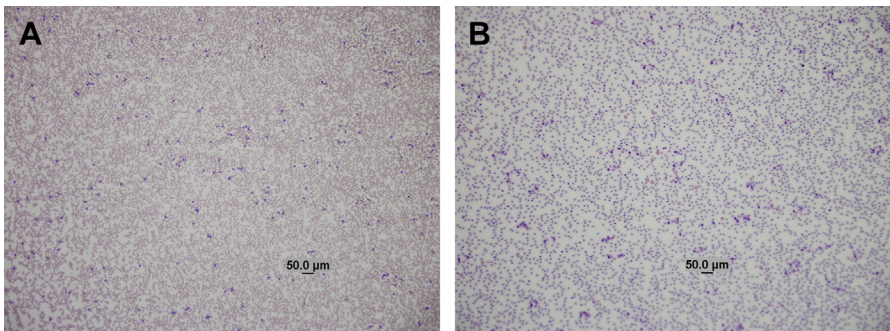


**Fig. 1.** Blood film with a thick body tapering to a feathered edge from a lizard (*Pogona vitticeps*) stained with Wright-Giemsa stain. The best cell morphology lies just behind the feathered edge in the monolayer area (*arrow*).

Anticoagulants, such as heparin and citrate, may affect the staining quality of the blood film. The anticoagulant EDTA (ethylenediaminetetraacetic acid) may cause hemolysis or cause the blood to clot in some species, such as birds in the crow family (corvids) or cartilaginous fish (elasmobranchs), rendering the sample useless. Once the film has been prepared, it should be dried immediately. In most settings, this is accomplished by waving the slide in the air; however, in high humidity the use of a commercially available slide warmer or a hair dryer set on a low (warm) setting held in front of the slide may be needed to properly dry the slide to prevent drying artifacts, such as excessive crenation of the red blood cells. Blood slides should be labeled with the animal identification information and the date. Romanowsky stains, such as Wright or Wright-Giemsa, are commonly used for the evaluation of hemic cytology.

At low magnification (using a 10 $\times$  or 20 $\times$  objective), an experienced cytologist can subjectively estimate the leukocyte concentration on a blood film as being low (leukopenia), normal, or high (leukocytosis) before examination of the cells using the 100 $\times$  (oil-immersion) objective (**Fig. 2**). Several formulas for estimating the total leukocyte and thrombocyte concentrations from a blood film have been proposed; however, none are accurate or precise and should not be used in reporting leukocyte and thrombocyte numbers. The morphology of the 3 major cell types (erythrocytes, leukocytes, and platelets or thrombocytes) is best evaluated at higher magnifications.

A differential leukocyte count is obtained by counting a minimum of 100 consecutively encountered white blood cells in the monolayer area of the blood film. For most species, the cells are classified as neutrophils or heterophils (depending on species), eosinophils, basophils, lymphocytes, and monocytes, to obtain a relative percentage for each leukocyte type. Cells not readily identified can be placed into a sixth category of "other." Abnormalities in leukocyte morphologies are noted.



**Fig. 2.** (A) Leukocytosis in the blood film of a ferret (*Mustela putorius furo*) (Wright-Giemsa stain). (B) Leukocytosis in the blood film of a turtle (*Graptemys versa*) (Wright-Giemsa stain).

Download English Version:

<https://daneshyari.com/en/article/3460239>

Download Persian Version:

<https://daneshyari.com/article/3460239>

[Daneshyari.com](https://daneshyari.com)