



Case Report

Ultrasound-guided facet joint injection to treat a spinal cyst

Tung-Liang Lin ^{a,c}, Chin-Teng Chung ^a, Howard Haw-Chang Lan ^b, Huey-Min Sheen ^{a,*}

^a Department of Physical Medicine and Rehabilitation, Taichung Veterans General Hospital, Taichung, Taiwan, ROC

^b Department of Radiology, Taichung Veterans General Hospital, Taichung, Taiwan, ROC

^c Department of Statistics, Feng Chia University, Taichung, Taiwan, ROC

Received April 18, 2012; accepted June 4, 2012

Abstract

Lumbar spinal cysts often present with backache and may be accompanied by lower extremity weakness as well as radiation pain if root compression occurs. The treatment regimens include anti-inflammatory drugs, physical therapy, procedures guided by fluoroscopy or computed tomography, and surgery. We report the case of a patient with a symptomatic lumbar spinal cyst at the L4–L5 facet joint. The symptoms immediately remitted after ultrasound-guided steroid–lidocaine injection into the L4–L5 facet joint. Magnetic resonance imaging follow up 4 months after injection showed complete resolution of the cyst.

Copyright © 2014 Elsevier Taiwan LLC and the Chinese Medical Association. All rights reserved.

Keywords: facet joint injections; spinal cysts; synovial cysts; ultrasonography

1. Introduction

Intraspinal cysts arising from the zygapophyseal joint capsule of the spine may cause backache and root compression. These cysts are composed of serous or gelatinous material that may communicate with the joint cavity.^{1–3} Most spinal cysts arise at the L4–L5 level and there is a higher prevalence in the 7th decade of life.¹ Treatment includes surgical removal and percutaneous aspiration or rupture with steroid injection under fluoroscopy-guided or computed tomography (CT)-guided procedures. To the best of our knowledge, the use of an ultrasound-guided injection to treat this condition has not been reported previously. We report here a patient who had complete resolution of a symptomatic lumbar spinal cyst following ultrasound-guided steroid–lidocaine injection into the facet joint. Magnetic resonance images at disease onset, 6 months

after onset, as well as 1 day and 4 months post-intervention are presented.

2. Case report

A 52-year-old man developed insidious lower back pain with radiation down to his right leg lasting for 10 months. There was no known history of traumatic events or surgery. He visited a community hospital where lumbar magnetic resonance imaging (MRI) showed a 0.3 × 0.5 cm oval-shaped cyst arising from the right facet joint of L4–L5 leading to right L5 root compression. Degenerative changes of the right facet joint were also noted (Fig. 1A). The patient received conservative treatment, including physical therapy and non-steroidal anti-inflammatory drugs (NSAIDs) by mouth, which resulted in partial improvement.

Six months after his first visit to the hospital, the patient reported breakthrough pain with rapid progression for 10 days. The same conservative treatment regimen was prescribed, but did not relieve the symptoms. The patient was then referred to our medical center for further management. On this visit, he reported a severe sharp and tingling ache with an intensity of 10/10 on the visual analog scale (VAS) for lumbago and 7/10 for radiating pain. The pain was provoked by sitting, standing,

Conflicts of interest: The authors declare that there are no conflicts of interest related to the subject matter or materials discussed in this article.

* Corresponding author. Dr. Huey-Min Sheen, Department of Physical Medicine and Rehabilitation, Taichung Veterans General Hospital, 160, Section 3, Chung-Kang Road, Taichung 407, Taiwan, ROC.

E-mail address: hmsheen@vghtc.gov.tw (H.-M. Sheen).

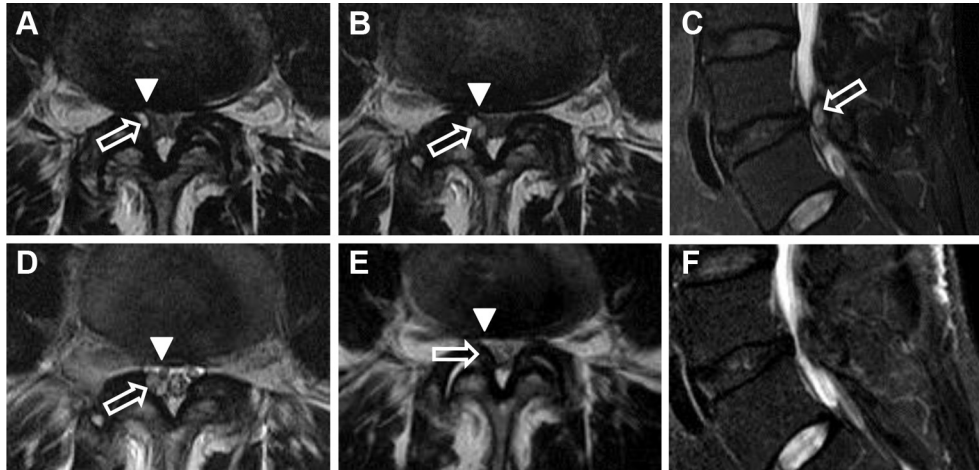


Fig. 1. Serial magnetic resonance imaging (MRI) of spinal cyst (T₂ weighted). (A) Initial MRI scan. The cyst (open arrow) appears as a well-defined high signal intensity fluid collection arising from the right L4–L5 facet joint and protruding into the spinal canal, resulting in root (arrowhead) compression. (B,C) Six months after conservative treatment, the cyst was enlarged [(A) 0.3 × 0.5 cm; (B) 0.4 × 0.7 cm]. (D) One day after ultrasound-guided facet joint injection, the lesion was the same size, but the symptom, radiating pain, was partially relieved. (E,F) Four months after facet joint injection, the cyst had disappeared and the symptoms were completely relieved. (A,B,D,E) Axial scans through the L4–5 level. (C,F) Sagittal scans through the right facet joint of L4–5.

walking, and flexing the trunk. The patient could only alleviate the pain by lying motionless on his side. No bowel nor bladder symptoms were reported. A manual muscle test showed 4/5 strength in the right big toe extensor and full strength in the remaining lower extremity myotomes. Hyperalgesia with a burning sensation was noted in the right L5 dermatome. Reflexes were symmetrical at the patellar and Achilles tendons. A straight leg raise test provoked an intolerable aching sensation in the lower back and down the dorsal aspect of the patient's right foot.

Non-contrast enhanced MRI was performed again and showed that the cyst had increased in size, with compression to the right L5 nerve root (Fig. 1B and C). Ultrasound-guided right facet joint injection was performed following the method described by Galiano et al⁴ (Fig. 2). The patient was placed in the prone position and a 12 MHz linear array transducer (GE Logiq 9 Series scanner; GE Healthcare, Milwaukee, WI, USA) was used. The sacrum was identified first and the lumbar spinal process was counted from the caudal to the cephalad vertebrae. The spinal process was identified and a longitudinal paravertebral image was obtained by a lateral shift of the transducer. Once the L5 level was reached, the transducer was rotated transversely to obtain the short-axis view. In the short-axis view, we could identify the transverse process of L5 and the corresponding superior articular process. The inferior articular process of L4 was found medially. Between the two processes, the facet joint was identified on the ultrasound image (Fig. 2A) and the site of needle insertion is illustrated on the corresponding MRI image (Fig. 2B). After identification of the adjacent anatomical landmarks, penetration into the rubbery needle-feel joint capsule with a 23 gauge (70 mm) needle was performed. Injection with 0.5 mL (20 mg) of triamcinolone and 0.5 mL of 2% lidocaine was then attained under real-time ultrasound guidance. The patient experienced immediate and significant relief of lumbago (VAS 10/10 to 0/10) and radiating pain (VAS 7/10 to 3/10) after the procedure.

Lumbar spine MRI performed 1 day after the injection showed the same cyst size in spite of the marked alleviation of the symptoms (Fig. 1D). MRI performed 4 months after the procedure showed complete resolution of the cystic lesion. The symptoms were relieved completely at 18 months' follow up (Fig. 1E and F).

3. Discussion

Intraspinous cysts, including spinal synovial cysts and ganglion cysts, were first described by Vosschulte and Berger⁵ in the 1950s with the symptoms and signs of spinal root compression, and were later renamed by Kao et al⁶ as juxta-facet cysts. Among the imaging modalities, MRI has good soft tissue contrast and high resolution⁷ and is therefore regarded as the method of choice for this diagnosis.¹ In pathogenesis, degenerative processes of the lumbar spine and soft tissue are considered to play an important part in causing protrusion of the synovial membrane through defects in the joint capsule, which in turn leads to the formation of a para-articular cavity filled with synovial fluid.^{8,9} The enclosed fluid is a clear, yellowish mucinous liquid which may communicate directly with the adjacent joint cavity. This probably explains why the injection of steroids into the facet joint is capable of causing cyst regression.^{3,9}

There have been several reports that steroid injection with or without lidocaine into the facet joint could resolve the symptoms of lumbar cysts.^{10,11} Parlier-Cuau et al¹⁰ reported that 67% of patients with symptomatic lumbar cysts experienced pain relief 1 month after injection guided by radiography and one-third of these patients had a long-lasting benefit. Therefore these workers suggested that facet joint steroid injection should be indicated prior to surgery. In our patient, good symptomatic improvement was obtained after steroid–lidocaine injection as a result of the analgesic and anti-inflammatory effects of the injected drugs. This is why the

Download English Version:

<https://daneshyari.com/en/article/3475863>

Download Persian Version:

<https://daneshyari.com/article/3475863>

[Daneshyari.com](https://daneshyari.com)