

Case Report

Atrial myxoma presenting as total occlusion of the abdominal aorta and its major four branches

Chun-Yang Huang^a, Yu-Yao Chang^a, Ming-Yu Hsieh^a, Chiao-Po Hsu^{a,b,*}

^a Division of Cardiovascular Surgery, Department of Surgery, Taipei Veterans General Hospital, Taipei, Taiwan, ROC

^b National Yang-Ming University School of Medicine, Taipei, Taiwan, ROC

Received November 18, 2010; accepted June 16, 2011

Abstract

The presentations of cardiac myxoma are diverse, from asymptomatic to a variety of symptoms due to embolization. Occlusion of abdominal aortic bifurcation by straddled myxoma is not common; however, obstructive level above renal artery is very rare. We present a patient with cardiac myxoma who presented with acute onset of paraplegia. The aorta was occluded from the level of the liver dome to the renal arteries, and catastrophic outcome (ischemia/reperfusion) following its removal.

Copyright © 2012 Elsevier Taiwan LLC and the Chinese Medical Association. All rights reserved.

Keywords: abdominal aorta; atrial myxoma; embolization

1. Introduction

Myxoma is the most common primary cardiac tumor, and 75% of myxomas occur in the left atrium.^{1,2} Myxoma may be asymptomatic and discovered incidentally or it may present with a variety of symptoms due to embolization.³ When embolization occurs, most emboli occur in the cerebral arteries, followed by the renal artery and iliac femoropopliteal artery; occasionally, the infrarenal aorta to bifurcation may be blocked if the myxoma is large.^{1,4–6} However, total occlusion of aorta above the renal artery was never reported.

2. Case report

A 56-year-old previously healthy man had sudden onset of paraplegia with hypoesthesia at 9:30 PM when he vomited after drinking. He was sent to local hospital, where aortic lesion was

suspected. The patient was transferred to our hospital for further evaluation because no experienced cardiovascular surgeon was available at the local hospital.

On arrival at our emergency department at 12:30 AM, the patient was lucid but slightly irritable. He had persistent paraplegia with hypesthesia below the umbilicus. Tachypnea [respiratory rate 30 breaths per minute (bpm)], tachycardia (heart rate 110 bpm), high blood pressure of upper arms (154/74 mm Hg), and body temperature (BT) 34.2 °C were noted. Physical examination showed cold, dark red mottled skin below the umbilicus, wheezing, and rales bilaterally, normal heart sounds without murmur, and a soft abdomen with flank tenderness. Muscle strength was 0/5 in the lower limbs, and pulses were nearly absent in the femoral, popliteal, and dorsalis pedis arteries.

Laboratory tests revealed metabolic acidosis (pH 7.187, pCO₂ 37.9 mm Hg, HCO₃ 14.1 mM), blood urea nitrogen 19 mg/dL, serum creatinine (Cr) 1.99 mg/dL, amylase 99 U/L, lactic acid 78.7 mg/dL, and creatine kinase 122 U/L.

Electrocardiography revealed sinus tachycardia with premature ventricular contractions. Chest radiography revealed bilateral pulmonary edema. Multidetector computed tomography (MDCT) revealed thrombosis of the aorta

* Corresponding author. Dr. Chiao-Po Hsu, Division of Cardiovascular Surgery, Department of Surgery, Taipei Veterans General Hospital, 201, Section 2, Shih-Pai Road, Taipei 112, Taiwan, ROC.

E-mail address: chiaopo@ms39.hinet.net (C.-P. Hsu).

(T12–L2), proximal celiac trunk, superior mesenteric artery (SMA), and bilateral renal arteries (Fig. 1). A cardiovascular surgeon was consulted and emergency surgery was scheduled.

After general anesthesia, the patient was positioned with the upper torso inclined at 45° toward the right side and the pelvis almost flat for the possibility of approaching to suprarenal aorta by a thoracoabdominal incision. First, an incision was made over the left inguinal area. Thromboembolectomy was attempted with a Fogarty catheter (6 French) via a femoral arteriotomy, but no thrombus could be retrieved. Therefore, a thoracoabdominal incision through the tenth intercostal space was taken to expose the aorta retroperitoneally for the purpose of thromboembolectomy of the individual branch. The suprarenal aorta was exposed, and the kidney was left *in situ*. The celiac trunk, SMA, and left renal artery and vein were identified. The proximal aorta was crossclamped, and transverse aortotomy was performed below the renal vein. A jelly-like mass was found and removed smoothly with forceps (Fig. 2). Aortotomy was repaired with 3-0 polypropylene. Reperfusion of the distal abdominal aorta and its four branches was confirmed only by intraoperative Doppler examination and the plethoric appearance of left renal cortex. Reperfusion of the abdominal branches and lower limbs was established 7 hours after the onset of symptoms.

Intraoperative transesophageal echocardiography showed a stalk in the left atrium (Fig. 3). Microscopic examination, including immunohistochemistry for DC34, confirmed that the mass was a cardiac myxoma several days later (Fig. 4). The surgical field was assessed meticulously for hemostasis and the splenic hilum was examined via a small incision of peritoneum for any laceration injury from traction, then the wound was closed in layers without tension. One Jackson-Pratt drain was placed in the splenic bed via the peritoneal incision and another chest tube in the pleural cavity. Fasciotomy was not

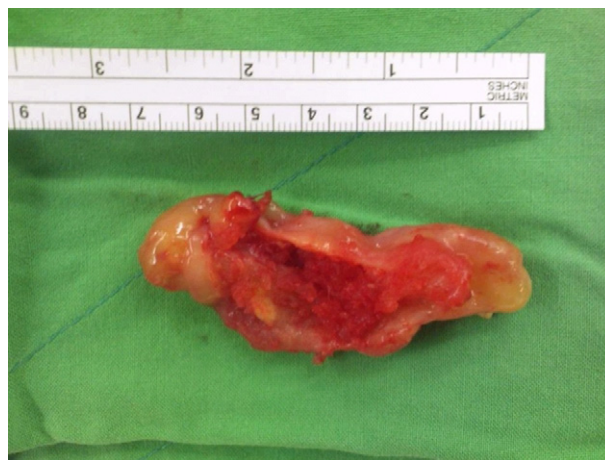

Fig. 2. A brown to red-brown gelatinous mass, 7.5 × 3 × 1.5 cm, retrieved from the abdominal aorta.

considered because there were no any signs of compartment syndrome in lower extremity.

On arrival in the postoperative room, sinus tachycardia, low blood pressure (60/40 mm Hg), and body temperature (32 °C) were noted despite a high dose of inotropic agents (dopamine 10.3 µg/kg/minute, epinephrine 0.38 µg/kg/minute).

Laboratory values showed intractable metabolic acidosis (pH 6.79, pCO₂ 83 mm Hg, HCO₃ 19 mM) and hyperkalemia (6.6 mM). Other remarkable values were white blood cell count, 19,400/mm³; platelets, 70,000/mm³, blood urea nitrogen, 20 mg/dL; and Cr, 2.16 mg/dL.

Drainage of bloody fluid from the Jackson-Pratt drain increased progressively after arrival in the postoperative room. Coagulants (desmopressin, ε-aminocaproic acid, and tranexamic acid) were given to correct the coagulopathy in addition to blood products and warm colloids. At 11:00 AM, coagulation profiles showed D-dimer 77.31 µg/mL, FDP 68.14 µg/mL, fibrinogen 281 mg/dL, and PT 22.1, APTT 123.7 seconds,

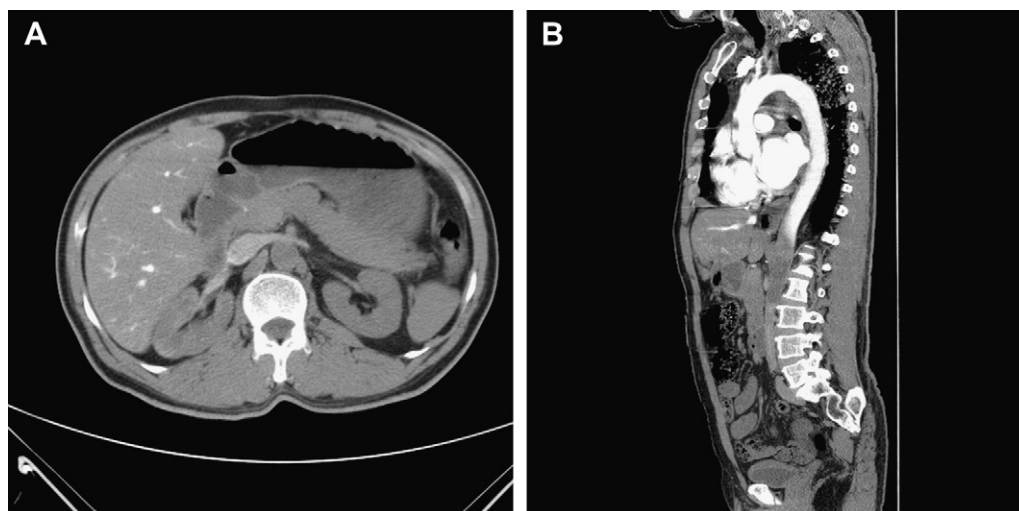


Fig. 1. Occlusion of proximal abdominal aorta viewed by multidetector computed tomography (CT). (A) Axial CT image showed no enhancement of abdominal aorta at the level of liver; (B) sagittal reformatted image showed complete occlusion of the aorta at the level of T12.

Download English Version:

<https://daneshyari.com/en/article/3476734>

Download Persian Version:

<https://daneshyari.com/article/3476734>

[Daneshyari.com](https://daneshyari.com)