



Clinical report

Outbreak of lead poisoning associated with ayurvedic medicine[☆]

Sara Fernández^a, Gerónimo-Antonio Pollio^a, Verónica Domínguez^a,
Santiago Nogué^{b,*}, Mercè Torra^c, Francesc Cardellach^a

^a Servicio de Medicina Interna, Hospital Clínic, Barcelona, Spain

^b Sección de Toxicología Clínica, Hospital Clínic, Barcelona, Spain

^c Sección de Toxicología Analítica, Hospital Clínic, Barcelona, Spain

ARTICLE INFO

Article history:

Received 6 September 2013

Accepted 12 September 2013

Available online 23 October 2015

Keywords:

Saturnism

Lead poisoning

Ayurvedic medicine

ABSTRACT

Background and objective: Lead poisoning is normally caused by repeated occupational inhalation of lead. However, lead may also be absorbed through the digestive route. Some alternative medical treatments, such as ayurvedic medicine, can also contain lead and may result in poisoning.

Patients and methods: We collected cases of lead poisoning related to Ayurvedic treatments attended at the Hospital Clínic of Barcelona.

Results: Two female patients, aged 45 and 57 years, respectively, who initiated ayurvedic treatments which involved the ingestion of various medicaments, were included. The first patient presented with anaemia and abdominal pain. The lead level was 74 µg/dl and free erythrocyte protoporphyrin was 163 µg/dl. She was treated with intravenous calcium disodium ethylenediaminetetraacetic acid (CaNa₂EDTA) and later with oral dimercaptosuccinic acid (DMSA) with a good evolution. The second patient presented with abdominal pain and a Burton's line. The lead level was 52 µg/dl and free erythrocyte protoporphyrin was 262 µg/dl. She was treated with oral DMSA and evolved favourably. Lead concentrations in some of the tablets supplied to the patients reached 2003 and 19,650 µg/g of tablet.

Conclusions: Lead poisoning may result from treatments based on ayurvedic medicine and may reach epidemic proportions. Health control of alternative medicines is necessary.

© 2013 Elsevier España, S.L.U. All rights reserved.

Brote de saturnismo asociado a un tratamiento basado en la medicina ayurvédica

RESUMEN

Fundamento y objetivo: El saturnismo es una enfermedad de causa tóxica que es producida, habitualmente, por la inhalación repetida de plomo en un ámbito laboral. Pero este metal puede también ser absorbido por vía digestiva. En medicinas alternativas, como la ayurvédica, el plomo puede formar parte de algunos tratamientos y ser causa de intoxicación.

Pacientes y método: Se recogen los casos de saturnismo atendidos y tratados en el Hospital Clínic de Barcelona en relación con un tratamiento ayurvédico.

Resultados: Se han incluido 2 mujeres de 45 y 57 años que iniciaron un tratamiento ayurvédico que comprendía la ingesta de diversos medicamentos. El primer caso desarrolló anaemia y dolor abdominal. La plumbemia fue de 74 µg/dl y la protoporfirina eritrocitaria de 163 µg/dl. Fue tratada con etilendiaminotetraacetato de calcio y sodio (CaNa₂EDTA) intravenoso y posteriormente con ácido dimercaptosuccínico (DMSA) oral, con buena evolución. El segundo caso presentó dolor abdominal y un ribete de Burton. La plumbemia fue de 52 µg/dl y la protoporfirina eritrocitaria de 262 µg/dl. Fue tratada con DMSA oral,

Palabras clave:

Saturnismo

Intoxicación por plomo

Medicina ayurvédica

[☆] Please cite this article as: Fernández S, Pollio G-A, Domínguez V, Nogué S, Torra M, Cardellach F. Brote de saturnismo asociado a un tratamiento basado en la medicina ayurvédica. Med Clin (Barc). 2015;144:166–169.

* Corresponding author.

E-mail address: SNOGUE@clinic.ub.es (S. Nogué).

evolucionando favorablemente. Las concentraciones de plomo en algunas de las pastillas suministradas a los pacientes fueron de 2.003 y 19.650 $\mu\text{g/g}$ de pastilla.

Conclusiones: La intoxicación por plomo puede ser el resultado de un tratamiento basado en la medicina ayurvédica y puede llegar a adquirir características epidémicas. Es necesario un control sanitario de los medicamentos alternativos.

© 2013 Elsevier España, S.L.U. Todos los derechos reservados.

Introduction

Plumbism or lead poisoning is usually an occupational disease derived from the inhalation of this metal in several types of industry, mainly those in which this toxic metal is smelted. However, there are other potential sources of plumbism, either by dust inhalation or ingestion of contaminated foods or drinks that may cause epidemic outbreaks.¹

Ayurvedic medicine, together with traditional Chinese medicine, is one of the world's oldest health care systems still in force. Of Indian origin, ayurvedic medicine includes herbal medications and diet while focusing on the use of the body, the mind and the spirit in the prevention and treatment of diseases. In Western countries, ayurveda is considered an alternative medical system; in Spain, as in other European and American countries, it is possible to find health care centres involved in this practice. However, although the pharmacological active substances on which this medicine is based come from plants, it is common (in up to 20% of this kind of medications) for these substances to be mixed with heavy metals such as lead, mercury, zinc, iron or arsenic because of their alleged therapeutic properties.² As a result, for the last 40 years, there have been case reports of iatrogenic poisoning with consequences mainly in the red blood cells,^{3–5} although toxic effects have also been described for other organs.^{6–8}

The objective of this study is to describe, for the first time in Spain, an outbreak of plumbism associated with treatment with ayurvedic medications containing high lead content.

Clinical observation

Case 1

The patient is a 45-year-old female carrier of thalassaemia minor who had no history of secondary anaemia and was under treatment with folic acid and vitamin B₁₂. She was allergic to penicillin. The patient reported symptoms of asthenia and colic-type abdominal pain during the previous 2 months, and there were no noteworthy findings in the physical examination. In the laboratory blood tests, microcytic and hypochromic anaemia (haemoglobin 6.6 g/dl, haematocrit 20.6%) were verified with basophilic stippling (Fig. 1); no haemolysis, iron or vitamin deficiencies were observed. Several supplementary examinations were performed (chest X-ray, occult blood in stool, upper and lower digestive endoscopy, bone marrow aspiration, ultrasound scan and abdominal computed tomography), which did not show significant abnormalities. Although the patient did not report any source of lead exposure, a toxicological analysis was requested, which showed a blood concentration of this metal of 74 $\mu\text{g/dl}$ (normal value <20 $\mu\text{g/dl}$). Elevated concentrations of erythrocyte protoporphyrin (163 $\mu\text{g/dl}$), mainly zinc protoporphyrin (85% of the erythrocyte protoporphyrin), as well as of delta-aminolevulinic acid in the urine were verified, thus establishing a diagnosis of plumbism.

The patient did not perform any work, household activities or hobbies related with lead exposure. There was no previous history of contact with petrol, paint, ceramics or other common sources of exposure. The water at her house was analysed, and potable

lead levels were verified (<3 $\mu\text{g/l}$). Re-questioning revealed that, 2 months before, she had started an ayurvedic treatment for shoulder bursitis and was taking 9 tablets a day of 3 medications, with no packaging or patient information leaflet, that were given to her at an "aesthetic and therapy centre" in a community located near Barcelona. An X-ray of one of the medications (Mahavatvidhwansa Rasa [MVV]) showed elevated radiodensity (Fig. 1), and the toxicological analysis of the pill showed a lead concentration of 2003 $\mu\text{g/g}$ per pill. Some of the other medications also contained lead, but in smaller quantities ranging from 4 to 86 $\mu\text{g/g}$ of pill, so the overall estimated daily consumption was 916 μg of lead, totalling 60 g of lead over the 2 months of treatment. The possible concomitant presence of mercury and arsenic was studied, but the results were negative.

Chelating treatment was initiated via intravenous line with calcium and disodium ethylenediaminetetraacetic acid (CaNa₂EDTA, 2 g/day), 5 days a week, for 2 weeks. The evolution of lead levels in blood and urine is shown in Table 1. After discharge from the hospital, she received oral ambulatory treatment with dimercaptosuccinic acid (DMSA, 10 mg/kg/8 h, 5 days a week, 2 weeks) until a blood lead level of 13 $\mu\text{g/dl}$ was achieved with normalisation of porphyrins and disappearance of clinical manifestations. Both treatments were well tolerated.

Case 2

The patient is a 57-year-old female with history of fibromyalgia who had been treated at the same ayurvedic centre as the previous case due to her baseline disease. She was prescribed a treatment that was given to her in unlabelled plastic bags with 4 types of pills. She had to take 3 tablets of each per day. Some 3 months later, she abandoned the treatment because of abdominal pain. Warned by

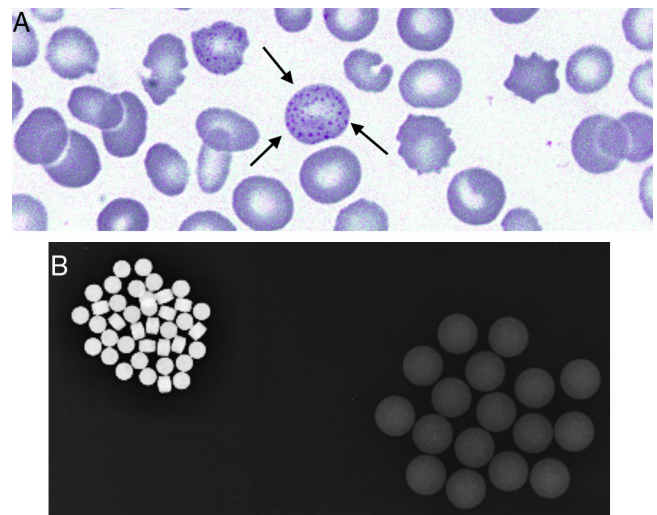


Fig. 1. (A) Blood smear from case 1. May-Grünwald-Giemsa stain. A basophilic stippling (arrows) is observed on some of the red blood cells (image courtesy of Josep Lluís Aguilar, MD); (B) X-ray of some of the ayurvedic medications ingested by the patient. The group on the left, labelled as Mahavatvidhwansa Rasa (MVV), is very radiodense and the lead concentration in one of them was 2003 $\mu\text{g/g}$ per pill.

Download English Version:

<https://daneshyari.com/en/article/3803381>

Download Persian Version:

<https://daneshyari.com/article/3803381>

[Daneshyari.com](https://daneshyari.com)