

# Anatomy of the pituitary, thyroid, parathyroid and adrenal glands

Judith E Ritchie

Saba P Balasubramanian

## Abstract

A detailed understanding of anatomy is essential for several reasons: to enable accurate diagnosis and plan appropriate management; to perform surgery in a safe and effective manner avoiding damage to adjacent structures and; to anticipate and recognize variations in normal anatomy. This chapter will cover the anatomy of four major endocrine glands (thyroid, parathyroid, pituitary and adrenal). Other endocrine glands (such as the hypothalamus, pineal gland, thymus, endocrine pancreas and the gonads) are beyond the scope of this chapter. In addition to gross anatomy, clinically relevant embryological and histological details of these four glands are also discussed.

**Keywords** Adrenal; anatomy; endocrine; parathyroid; pituitary; thyroid

## Thyroid gland

### Embryology of the thyroid

The thyroid gland is derived from endodermal epithelium from the median surface of the developing pharyngeal floor. It arises between the primitive tongue bud and the copula, a ridge formed by fusion of the ventral ends of the first and second pharyngeal pouches. At this site a structure called the foramen caecum is identified at around the 24th day of gestation. This differentiates into precursory thyroid tissue, as a midline thickening of epithelium called the thyroid primordium, which subsequently hollows into a diverticulum. It remains attached to the tongue by the thyroglossal duct as it begins to descend down the neck to its final position just inferior to the thyroid cartilage. This takes a path anterior to the pharyngeal gut, hyoid bone and laryngeal cartilages. Between 7 and 10 weeks' gestation the tubular diverticulum solidifies and the thyroglossal duct obliterates, leaving only a blind pit between the anterior two-thirds and posterior third of the tongue. The thyroid develops its anatomical shape during descent, with two lateral lobes connected across the trachea by an isthmus. Remnants of the track along the line of descent may persist and present in both childhood and adult life as a thyroglossal cyst or fistula, or as a pyramidal lobe (Figure 1).

*Judith E Ritchie BMedSci(Hons) MBChB MRCS(Ed) is a Surgical Trainee and is Currently Doing a PhD at the University of Leeds, UK. Conflicts of interest: none declared.*

*Saba P Balasubramanian MS FRCS(Gen Surg) PhD is a Senior Lecturer and Honorary Consultant Surgeon at the University of Sheffield and Sheffield Teaching Hospitals NHS Foundation Trust, Sheffield, UK. Conflicts of interest: none declared.*

The neuroendocrine parafollicular (C) cells from neural crest tissue develop separately in the ultimobranchial body, which develops from the fourth pharyngeal pouch. These cells migrate into the thyroid tissue following fusion of the ultimobranchial body with the thyroid gland.

Glandular development is controlled by thyroid-stimulating hormone (TSH) and the thyroid becomes functional during the third month of gestation.

### Gross anatomy

The thyroid gland lies anterior to the cricoid cartilage and trachea, and slightly inferior to the thyroid cartilages. It comprises two lateral lobes joined together by an isthmus. The lateral lobes can be traced from the lateral aspect of the thyroid cartilage down to the level of the sixth tracheal ring. The isthmus overlies the second and third tracheal rings. The entire gland is enclosed within the pretracheal fascia, a layer of deep fascia that anchors the gland posteriorly with the trachea and the laryngopharynx, causing it to move during swallowing. The gland has a fibrous outer capsule, from which septae run into the gland to separate it into lobes and lobules. It is overlapped by strap muscles anteriorly. The carotid sheaths with their contents lie postero-lateral to the lobes. Two nerves related to the gland and at risk of damage during thyroidectomy are the recurrent laryngeal and external laryngeal nerves. These supply the larynx and are closely associated with the inferior and superior thyroid arteries respectively. Other related structures include the superior and inferior parathyroid glands, which lie in close proximity to the middle and lower poles of the thyroid lobes respectively.

The thyroid is a very vascular organ with extensive capsular and intra-thyroidal anastomoses between the named vessels from either side (Figure 2). The superior thyroid artery (branch of external carotid artery) enters the upper pole and the inferior thyroid artery (branch of the thyrocervical trunk) enters the posterior aspect of the middle/lower part of the gland. Additional branches may arise from pharyngeal and tracheal arteries, as well as the thyroidea ima artery. This latter vessel is variable in both its presence and origin. It may arise from either the aortic arch or the brachiocephalic artery. Arterial branches reach the gland beneath the pretracheal fascia and pierce the gland's capsule to penetrate and supply the underlying tissue. Venous drainage is from the anterior surface of the gland into three veins: superior and middle thyroid veins draining the superior and middle aspects of the gland into the internal jugular vein, and the inferior thyroid vein draining the inferior pole into the brachiocephalic vein. Lymphatic vessels run alongside arterial branches within the connective tissue separating the gland's lobules. They drain into the pretracheal, paratracheal and prelaryngeal nodes and nodes belonging to the deep cervical chain.

The gland's nerve supply is autonomic and predominantly vasomotor, arising from the superior, middle and inferior cervical sympathetic ganglia and running into the gland with the arterial branches.

### Histology

The thyroid gland consists of large spherical colloid-filled follicles that contain thyroglobulin. The follicles are lined by a simple cuboidal epithelium. This epithelium takes up and breaks down thyroglobulin from the colloid following stimulation by thyroid-

**Descent of the thyroid during development, showing possible sites of ectopic thyroid tissue, thyroglossal cysts and the pyramidal lobe**

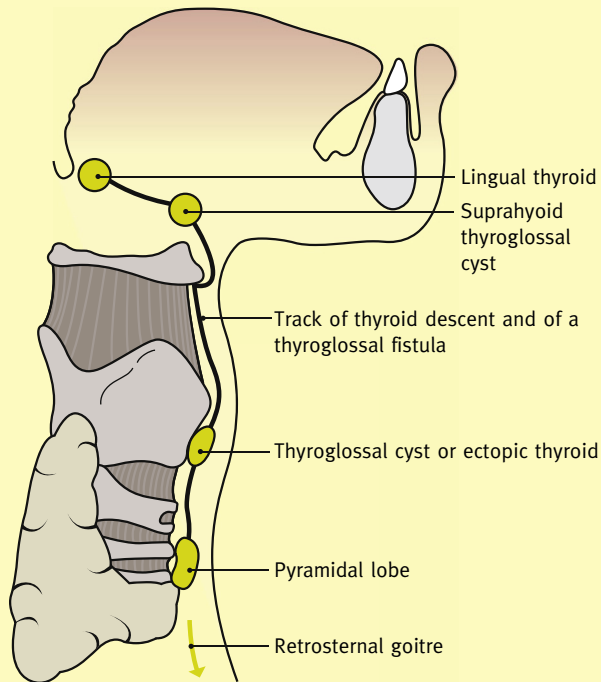


Figure 1

stimulating hormone (TSH) to release thyroid hormones into the bloodstream. Parafollicular cells are located between the follicles. They synthesize and secrete calcitonin. The gland is contained within a fibrous capsule.

**Parathyroid glands**

**Embryology**

There are generally four parathyroid glands (two superior and two inferior) located in relation to upper and lower aspects of the posterior thyroid gland on both sides. The superior and inferior parathyroids develop from the fourth and third pharyngeal pouches respectively between the fifth and sixth gestational week (Figure 3). The superior glands take a short descent to their final position relative to the inferior glands, which share a longer caudo-medial descent with the thymus gland. Pharyngeal connections are lost at the seventh week of gestation.

**Gross anatomy**

The normal gland is an ovoid or lentiform structure with a yellowish-brown colour. It is adherent to the posterior aspect of the thyroid capsule and may sometimes be located within the capsule. The four parathyroid glands sit in pairs on either side of the midline. The superior parathyroids usually lie midway along the posterior surface of the thyroid gland above the level at which the inferior thyroid artery crosses the recurrent laryngeal nerve. The inferior parathyroids are generally found at the inferior pole of the thyroid, below the inferior thyroid artery. In relation to the recurrent laryngeal nerve, the superior and inferior glands lie anterior and posterior to the nerve respectively (Figure 4). There may be significant variation in both the number

**The thyroid gland with its blood supply and relations**

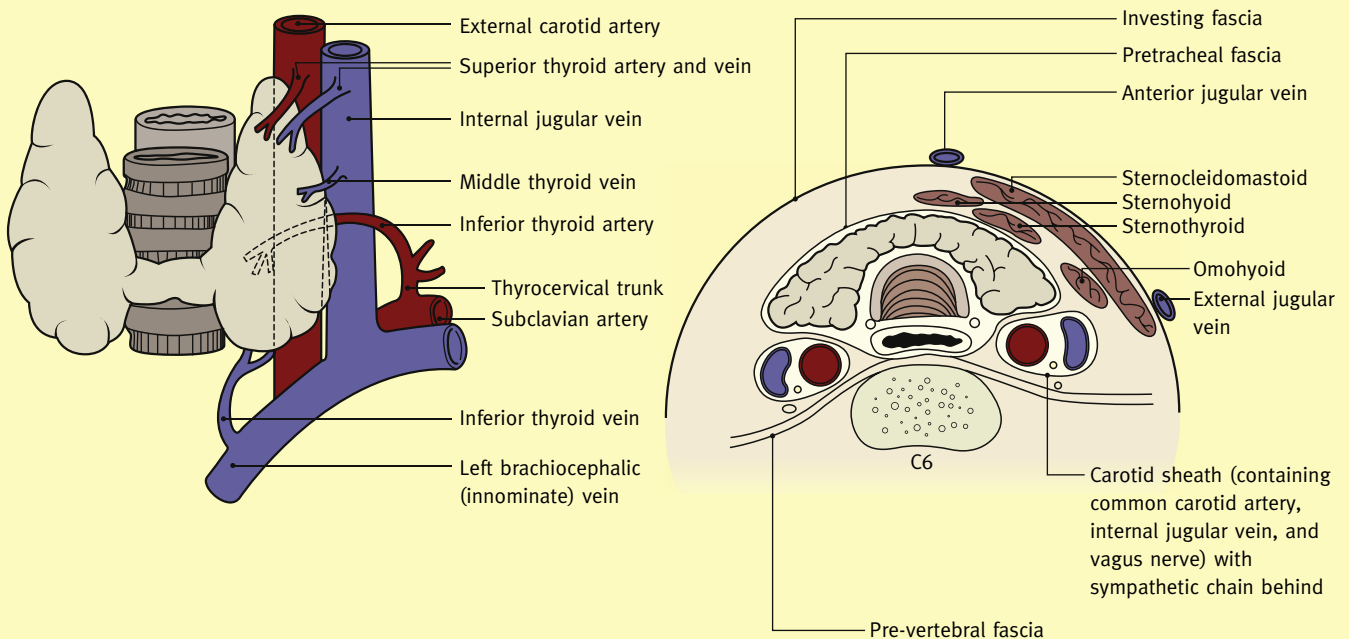


Figure 2

Download English Version:

<https://daneshyari.com/en/article/3838411>

Download Persian Version:

<https://daneshyari.com/article/3838411>

[Daneshyari.com](https://daneshyari.com)