




# Kidney Research and Clinical Practice

journal homepage: <http://www.krccp-ksn.com>  
Contents lists available at ScienceDirect



## Case Report

### Toxic epidermal necrolysis associated with deflazacort therapy with nephrotic syndrome



Eun Chae Lee, Geun A Kim, Ja Wook Koo\*

Department of Pediatrics, Sanggye Paik Hospital, Inje University, College of Medicine, Seoul, Korea

#### ABSTRACT

##### Article history:

Received 8 June 2014

Received in revised form

22 July 2014

Accepted 5 August 2014

Available online 18 November 2014

##### Keywords:

Deflazacort

Intravenous immunoglobulin-G

Nephrotic syndrome

Toxic epidermal necrolysis

Toxic epidermal necrolysis (TEN) is a drug-related fatal disease. Extensive necrosis of the epidermis can lead to serious complications. This report describes two cases of TEN, associated with deflazacort (DFZ), in two boys, aged 4 years and 14 years, with nephrotic syndrome (NS). The 14-year-old male teenager received DFZ following NS relapse. After 17 days, pruritic papules appeared on the lower extremities. Another case involved a 4-year-old boy receiving DFZ and enalapril. After a 41-day DFZ treatment period, erythematous papules appeared on the palms and soles. Within 3 days, both boys developed widespread skin lesions (> 50%) and were admitted to the intensive care unit for resuscitative and supportive treatment. The patients showed improvement after intravenous immunoglobulin-G therapy. Owing to the rapid, fatal course of TEN, clinicians need to be aware of the adverse effects of this drug when treating cases of NS.

© 2014. The Korean Society of Nephrology. Published by Elsevier. This is an open access article under the CC BY-NC-ND license (<http://creativecommons.org/licenses/by-nc-nd/4.0/>).

## Introduction

Toxic epidermal necrolysis (TEN) is typically a drug-related fatal disease characterized by necrosis and destruction of the entire epidermal skin layer [1]. Nephrotic syndrome (NS) is treated with steroids such as prednisolone (PD). However, because of the adverse effects, such as osteoporosis, growth retardation, and weight gain, associated with PD treatment, other drugs with fewer side effects, such as deflazacort (DFZ; an oxazoline derivative), have been recommended [2]. Among the 94 patients with NS who received steroid therapy in Sanggye Paik Hospital, Seoul, Korea between 2001 and 2012, three patients who received DFZ developed TEN. We have reported one of these cases previously [3]; herein, we describe the two other cases of TEN related to DFZ in two boys aged 4 years and 14 years.

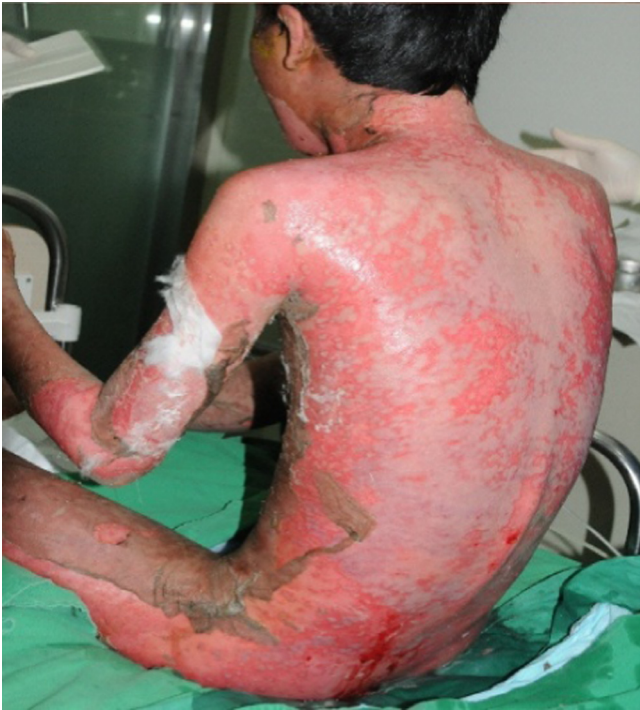## Case report

### Case 1

A 14-year-old boy, who was diagnosed with NS at 8 years of age, received PD as the initial treatment. After 4 months of PD treatment, remission was achieved. However, because of NS relapse, the treatment was switched to DFZ for 14 days; DFZ treatment was then tapered. He was also receiving risperidone (0.5 mg, BID) and atomoxetine (25 mg QD) since 8 years of age for the treatment of mental retardation. After 6 years, he again received DFZ (24 mg TID) daily owing to proteinuria. After a 17-day treatment period, pruritic papules and patches appeared on the lower extremities. He was admitted 19 days after medication was initiated, after the skin lesions indicated an extensive spread within 3 days. Laboratory tests revealed a white blood cell count of 7,040 cells/mm<sup>3</sup>, C-reactive protein level of 0.3 mg/dL, and negative results for human immunodeficiency virus and *Mycoplasma pneumoniae* antigen. On hospital Day 2, the skin could be easily peeled off, similar to that noted in burn injuries (Fig. 1). Hence, he was transferred to the intensive care unit for infection prevention and conservative care. All medications were

\* Corresponding author. Department of Pediatrics, Sanggye Paik Hospital, Inje University, College of Medicine, Dongil-ro 1342, Nowon-gu, Seoul, Korea.

E-mail address: [koojw9@paik.ac.kr](mailto:koojw9@paik.ac.kr) (JW Koo).



**Figure 1.** Typical pattern of toxic epidermal necrolysis: erythema, blistering, and full-thickness epidermal loss is seen over the entire body.

discontinued immediately. Intravenous immunoglobulin-G (IV-IG; total, 4.51 g/kg) was administered according to the severity of the skin lesions. After 18 days of treatment, the skin lesions improved. The patient needed conservative management, and was discharged on hospital Day 25. After discharge, the NS has been controlled by switching the treatment to PD, and the patient has consistently taken risperidone. Thus far, he has not experienced any skin complications.

### Case 2

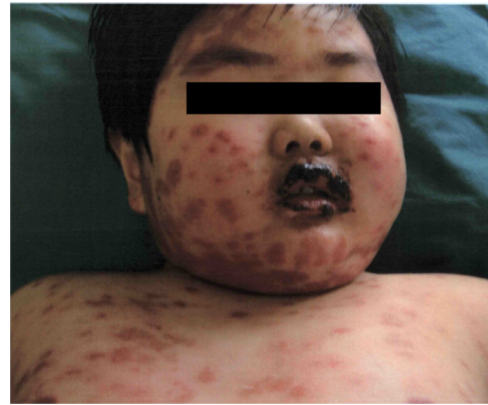A 4-year-old boy who was diagnosed with NS was receiving DFZ (24 mg TID) and enalapril (5 mg QD). After 41 days, he presented with papules and blisters around the mouth and on the palms and soles (Fig. 2). He was suspected to have TEN and was hospitalized.

His vital signs were stable, although he had a fever. The initial white blood cell count was 14,720 cells/mm<sup>3</sup> and the C-reactive protein level was 1.4 mg/dL. The other laboratory findings were normal.

Erythematous papules and blisters rapidly spread on his body ( $\geq 50\%$ ) within 3 days. The administration of oral steroids was discontinued. Ceftriaxone was injected, and IV-IG (total, 4 g/kg) was administered for 13 days according to the extent of skin complications. From Day 20 after hospital admission, the patient showed improvement in the symptoms, and was subsequently discharged. Thereafter, the medication was switched to PD, and he has not experienced a relapse thus far.

### Discussion

TEN is a rare but life-threatening disease that involves the skin and mucosa, and is usually caused by certain drugs [1].



**Figure 2.** Erosions and crusts on the lips and multiple bullae on the face and chest.

The extent of epidermal involvement in TEN is more than 30% [1,4].

A few recently published cases indicate that TEN might be induced by steroid use [3,5,6]. In particular, at our center, 40 patients treated with PD did not develop TEN, but three of 54 patients treated with DFZ developed TEN. In Case 1, despite the initial treatment with PD and DFZ, no skin complications developed at that time. However, after readministration of high-dose DFZ for more than 2 weeks, TEN developed. After remission was achieved, rashes did not reappear even after switching the treatment to oral PD. PD has also been reported to potentially cause Stevens–Johnson syndrome (SJS) [7]. TEN is considered a delayed-type hypersensitivity reaction [1]. The reaction severity decreases following the discontinuation of drug administration and develops more rapidly on drug readministration.

In Case 1, risperidone and atomoxetine were administered simultaneously. It is unclear whether drug interactions were involved in the development of TEN. However, these drugs were administered 6 years previously and the patient did not present side effects at that time. Consistent with the findings in Case 2, Kim et al [3] reported that TEN developed in a patient with NS treated with DFZ and enalapril. After approximately 4 weeks of treatment, the condition progressed from erythematous papules to TEN. Captopril was reported to possibly cause TEN [8], whereas enalapril may be a causative agent for TEN when combined with DFZ [3]. Enalapril and captopril have been suggested to be powerful acantholytic drugs *in vitro*, and the active amide group of both drugs could induce acantholysis [9]. However, Papay et al [10], in their extensive review of SJS/TEN, have classified both drugs as “drugs commonly used but probably not associated with SJS/TEN.” Kim [5] and Kim et al [6] also reported cases of SJS and TEN caused by the use of DFZ (Table 1). Their patients did not receive any other medication, except for DFZ, over 8 weeks. TEN is considered to be associated with exposure to an agent during an 8-week period prior to disease onset [1]. To confirm the relationship between TEN and DFZ, a rechallenge would be helpful. Kim [5] has suggested that DFZ may be a possible cause of SJS, based on the results of skin tests and provocation tests using DFZ. In the present cases, a rechallenge with DFZ could not be performed due to ethical reasons. The relationship between corticosteroids, especially DFZ, and TEN remains controversial, and its exact mechanism is not known [11]. Roujeau et al [11] suggested that the risks were particularly

Download English Version:

<https://daneshyari.com/en/article/3890936>

Download Persian Version:

<https://daneshyari.com/article/3890936>

[Daneshyari.com](https://daneshyari.com)