



Case Report

A case of scrub typhus requiring maintenance hemodialysis

Dae-Yeon Kim¹, Hee-Soon Park¹, Dong-Jae Han¹, Hyo-Chul Kang¹, Ji-Hye Lee²,
Won-Jong Jang³, Hyo-Wook Gil¹, Jong-Oh Yang¹, Eun-Young Lee^{1,*}, Sae-Yong Hong¹¹ Department of Internal Medicine, Soonchunhyang University Cheonan Hospital, Cheonan, Korea² Department of Pathology, Soonchunhyang University Cheonan Hospital, Cheonan, Korea³ Institute of Global Disease Control and Department of Microbiology, College of Medicine, Konkuk University, Seoul, Korea

A B S T R A C T

Renal failure caused by scrub typhus is known to be reversible. In most cases, renal function is almost fully restored after appropriate antibiotic treatment. A 71-year-old man was diagnosed with scrub typhus complicated by renal failure. A renal biopsy revealed histopathologic findings consistent with acute tubulointerstitial nephritis. Renal function did not improve 18 months after discharge and the patient required continuous hemodialysis. Although severe renal failure requiring dialysis is a rare complication of scrub typhus, we describe a case of scrub typhus requiring maintenance hemodialysis. To the best of our knowledge, this is the first such report.

© 2013. The Korean Society of Nephrology. Published by Elsevier. This is an open access article under the CC BY-NC-ND license (<http://creativecommons.org/licenses/by-nc-nd/4.0/>).

Article history:

Received 9 June 2013

Received in revised form

28 July 2013

Accepted 15 August 2013

Available online 5 November 2013

Keywords:

End-stage renal disease

Hemodialysis

Scrub typhus

Tubulointerstitial nephritis

Introduction

Scrub typhus is an acute febrile illness characterized by fever, chills, myalgia, skin rash, lymphadenopathy, and an eschar at the site of the inoculating chigger bite. Scrub typhus, rickettsial infection (*Orientia tsutsugamushi*), is transmitted by trombiculid chigger mites (*Leptotrombidium* species). It is endemic in Southern and Eastern Asia including Northern Australia, and the Western Pacific Islands [1,2]. The spectrum of the clinical severity of scrub typhus ranges from mild to severe with fatal complications such as meningoencephalitis, pneumonitis, acute respiratory distress syndrome, acute kidney injury (AKI), myocarditis, disseminated intravascular coagulation (DIC), and septic shock [2–5].

The reported incidence of renal failure caused by scrub typhus varies from 10.5% to 42.6% according to the criteria of renal failure [6,7]. In most case reports, the serum creatinine level was restored after the administration of appropriate

antibiotics such as doxycycline and azithromycin although varying degrees of renal deterioration and recovery time have been reported. To the best of our knowledge, no case of progression to end-stage renal disease has been reported for this condition. This is the first reported case of scrub typhus requiring maintenance hemodialysis.

Case report

A 71-year-old man was transferred to our university hospital from a private clinic because of significantly elevated serum creatinine. His serum creatinine level had been 1.2 mg/dL in the health screening examination performed 6 months prior to admission. Routine urine analysis was not performed at that time. His past medical history included diabetes mellitus for 10 years treated with oral hypoglycemic agents. The patient reported climbing mountains in the Jeolla province of Korea, 2 weeks prior to admission to our hospital. Four days later, he developed fever, chills, myalgia, and cough. The serum creatinine level was 11.0 mg/dL as measured at a private clinic, and the patient was transferred immediately to Soonchunhyang University Cheonan Hospital.

At the time of admission, vital signs were as follows: blood pressure, 170/90 mmHg; pulse rate, 87 beats/min; body

* Corresponding author. Division of Nephrology, Soonchunhyang University College of Medicine, 23-20 Bongmyung-dong, Cheonan 330-721, Korea.

E-mail address: eylee@sch.ac.kr (EY Lee).

temperature, 36.4°C; and respiratory rate, 20 breaths/min. The patient's mental status was alert. On physical examination, an eschar, which is characteristic of scrub typhus, was observed on the right arm near the axillary area. Complete blood cell counts were as follows: white blood cell count, $8.96 \times 10^9/L$; hemoglobin, 10.9 g/dL; hematocrit, 31.5%; and platelet count, $217 \times 10^{12}/L$. The results of arterial blood analysis were: pH, 7.31; arterial CO₂ tension, 25 mmHg; arterial O₂ tension, 90 mmHg; bicarbonate, 12.6 mM; and O₂ saturation, 96%. The biochemistry results were as follows: C-reactive protein (CRP), 78.54 mg/L; blood urea nitrogen, 91.6 mg/dL; creatinine, 14.1 mg/dL; sodium, 133 mEq/L; potassium, 5.8 mEq/L; and chloride, 103 mEq/L. Other significant laboratory findings were as follows: total protein, 5.7 g/dL; albumin, 3.1 g/dL; aspartate transaminase, 50 IU/L; alanine aminotransferase, 79 IU/L; uric acid, 11.0 mg/dL; creatinine phosphokinase, 128 IU/L; and lactate dehydrogenase, 652 IU/L. Microscopic urinalysis showed red blood cells > 100/high-power field (HPF), white blood cells 50–99/HPF, and cast < 1/HPF. The results of 24-hour urine analysis showed proteinuria at 934.5 mg/day. Serologic tests were all negative for rheumatoid factor, anti-nuclear antibody, hepatitis B and C virus, human immunodeficiency virus antibody, and syphilis (rapid plasma reagin test). Antistreptolysin O and complement levels were normal.

The patient had a history of outdoor activities and showed typical clinical manifestations of scrub typhus, especially an eschar in the right axillary area. The results of an immunochromatographic antibody assay test for *O. tsutsugamushi* was positive, and the immunofluorescent antibody assay test profile showed an immunoglobulin (Ig)M titer > 1:2048 and IgG titer > 1:2048. On the basis of these findings, he was diagnosed with scrub typhus. Doxycycline was administered 200 mg on the first day, followed by a maintenance dose of 100 mg once daily for 20 days.

For correction of hyperkalaemia, metabolic acidosis, and marked elevation of serum creatinine levels with uremic symptoms, the patient was started on hemodialysis on the first day of admission. After emergency management, he was placed on hemodialysis three times/week with conservative treatment. Clinically, the patient's symptoms improved dramatically while he was receiving doxycycline, showing a gradual decrease in inflammatory markers such as CRP. However, serum creatinine levels assessed prehemodialysis did not decrease continuously (Fig. 1).

We performed an ultrasonography-guided renal biopsy to rule out other underlying diseases, including diabetic nephropathy and primary glomerulonephritis, on Day 7 after admission. Microscopically, we detected diffuse lymphoplasmacytic infiltrations with scattered neutrophils in the edematous interstitium. Tubulitis and acute tubular necrosis were also observed. Detached tubular epithelial cells and neutrophils were detected in the tubular lumen. Mild tubular atrophy was also observed. The glomeruli were normal (Fig. 2), and no signs of mesangial expansion or glomerulosclerosis, which are common in diabetic nephropathy, were observed. However, vascular changes such as intimal fibrous thickening and medial sclerosis were severe.

The patient remained on hemodialysis three times/week, and he was discharged on Day 25 after admission. We expected the patient to recover his renal function gradually, but he remained on hemodialysis in an artificial kidney room of a private clinic for 18 months after discharge, and an arteriovenous fistula was formed. The patient's renal function did not improve, and his serum creatinine level remained at 8–10 mg/dL.

Discussion

In the present study, we describe a patient with renal failure caused by scrub typhus that did not show improvement of renal function despite a decrease in the levels of inflammatory markers such as CRP. The results of a renal biopsy showed microscopic findings suggestive of tubulointerstitial nephritis. Although case reports of patients with renal failure caused by scrub who underwent renal biopsy are rare, the presence of *O. tsutsugamushi* coccobacilli in the renal tubule has been reported previously [8]. In our patient, the presence of microorganisms was not verified.

Although the pathophysiology of renal failure as a complication of scrub typhus has not been fully elucidated, there are several possible hypotheses. First, because the basic pathologic characteristic of scrub typhus is multiorgan vasculitis of the small blood vessels, renal failure can be assumed to be associated with vasculitis [9,10]. A second possible explanation is DIC. Thrombosis and coagulation may induce microangiopathy and multiple organ damage, including AKI. A third explanation is prerenal azotemia caused by renal hypoperfusion

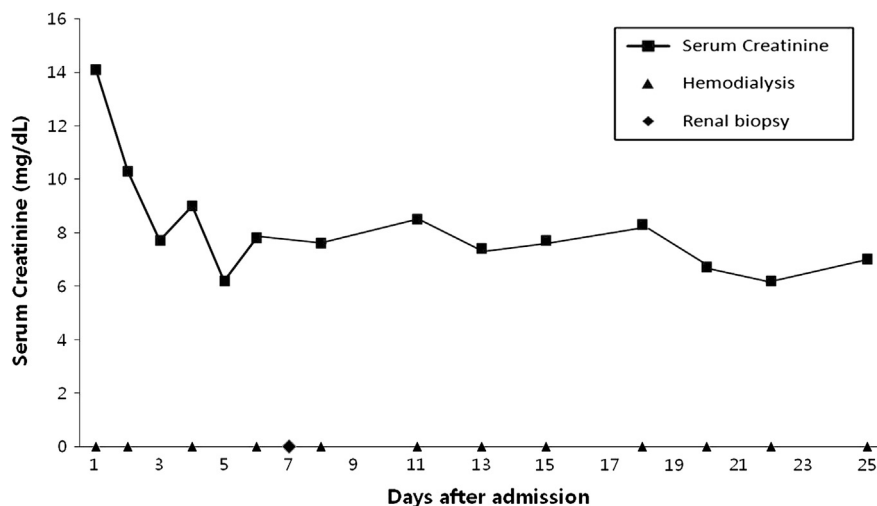


Figure 1. Time course of the changes in serum creatinine levels. Hemodialysis is indicated by arrowheads, and renal biopsy was performed at 7 days after admission.

Download English Version:

<https://daneshyari.com/en/article/3891905>

Download Persian Version:

<https://daneshyari.com/article/3891905>

[Daneshyari.com](https://daneshyari.com)