

Male and female sterilization

Rebecca McKay

Catherine Schunmann

Abstract

Male and female sterilization are important forms of contraception worldwide despite declining popularity in developed countries. Vasectomy is the only highly reliable form of male contraception. Appropriate counselling about permanent methods of contraception in both sexes is vital and should include information about irreversibility, failure rates and complications. The alternatives to sterilization, particularly Long Acting Reversible Contraception (LARC) should be discussed in detail as they are at least as effective or more effective and have the advantage of reversibility. Hysteroscopic rather than laparoscopic techniques for female sterilization are more cost effective but are limited in their availability. In males the no-scalpel technique vasectomy requires minimal operating time and results in less post-operative discomfort than the incisional method. Regret after sterilization and requests for reversal are more common in patients under 30 years and in men with no children.

Keywords hysteroscopic; Long Acting Reversible Contraception (LARC); regret; risks; sterilization; vasectomy

Introduction

Worldwide, sterilization is still the most common method of pregnancy prevention with 180 million women relying on female sterilization and 42 million men relying on vasectomy for contraception. Female sterilization is more popular than vasectomy despite the higher rate of operative complications and failure. In developed countries the increasing uptake of Long Acting Reversible Contraception (LARC) has resulted in fewer women choosing permanent methods. In the UK in 2013 almost a third of women visiting community contraceptive clinics requested, or were using, a LARC method.

In the UK female sterilization has declined by 75% over the last decade and male sterilization has fallen by 50%. In fact vasectomy has now overtaken female sterilization in popularity with 16% of males between ages of 16 and 45 being sterilized compared with 8% of females (2009 figures).

Sterilization can be undertaken at caesarean section, at termination of pregnancy or as an elective procedure. Female sterilization using culdoscopy via the vaginal route is no longer a recommended technique due to an increased risk of infection. The aim of this review is to use case histories of requests for elective sterilization to illustrate the different methods available, their failure and complication rates along with an in-depth

review of the most reliable alternatives. We also review the ways in which clinicians should be alert for women who may be at higher risk of post sterilization regret and related negative psychological sequelae of sterilization. Finally, we touch on the cost implications for the NHS.

Case 1: long term relationship with three children

A 38 year old woman attends the gynaecology clinic requesting sterilization. She has been married for 14 years and has three children, the youngest of whom is aged 5 years. These were all normal deliveries. She has tried an IUS for one year but had persistent irregular bleeding. She and her partner (age 43) are both fit and well and certain that they have completed their family. Her BMI is normal.

Once a full discussion of the alternatives to sterilization has been completed, the couple should decide who should be sterilized. This will take into account any medical problems and preferences for either procedure. In this scenario both partners are healthy. The couple should be counselled that both forms of sterilization are intended to be permanent, reversal is unlikely to be funded by the NHS and may be unsuccessful. Face to face counselling by staff adequately trained in contraceptive care should be provided using language that is easy to understand and free of jargon. Opportunities for questions should also be given and comprehensive patient information leaflets provided.

Female sterilization may be performed via the hysteroscopic or laparoscopic routes. Laparoscopic sterilization is a low risk procedure that is usually performed as a day case under general anaesthetic in the UK. The mechanism of action is to irreversibly occlude the fallopian tubes to prevent fertilization occurring. Hysteroscopic sterilization is only available in some NHS hospitals and is discussed in the next scenario.

Prior to sterilization it is important to exclude pregnancy. A pregnancy test will only be reliably negative 3 weeks after any episode of unprotected sex so encouraging a reliable form of contraception before the procedure is essential. Sterilization in the follicular phase of a normal menstrual cycle reduces the risk of an undetected implanted pregnancy occurring prior to or just after the procedure. Contraception should be continued until after the woman's next period.

Although the risks of the operation are small, women need to be fully informed to obtain valid consent. Women should be advised that there is an increased complication rate in women who are obese (a BMI of >30), who have had previous surgery or a history of pelvic inflammatory disease (PID). Minor complications include infection and/or bruising to the small skin wounds, shoulder tip pain, laceration to the cervix and uterine perforation (from the uterine manipulator). More major complications occur in around 2 in 1000 women. These are bowel or bladder damage (0.4/1000) of which up to 15% may not be recognised at the time of operation and blood vessel injury (0.2/1000). Anaesthetic risk should be mentioned and the overall risk of death from laparoscopic sterilization is 3–8 per 100,000. At the time of consent they should be informed that the lifetime failure rate of sterilization is 1 in 200, which is lower than some reversible alternatives.

Patients should also decide at the time of consenting whether they would be prepared to undergo a mini-laparotomy should the

Rebecca McKay MRCOG MFSRH is a Consultant Obstetrician and Gynaecologist at Peterborough City Hospital, Peterborough, UK. Conflicts of interest: none declared.

Catherine Schunmann MRCOG MFSRH is a Consultant in Sexual and Reproductive Healthcare at Norwich Contraception and Sexual Health Clinic, Norwich, UK. Conflicts of interest: none declared.

laparoscopic route fail. This method is often used as first line in low resource settings.

After being anaesthetised, the patient's legs are elevated and a uterine manipulator may be inserted to antevert the uterus and elevate the fallopian tubes. The bladder is emptied and a pneumoperitoneum is created with CO₂ using either an umbilical closed entry with a Verres needle or an open Hassan technique. The open technique is recommended in women who are obese or very thin. After introducing the laparoscope through the umbilical port and checking for injuries, a second port is inserted suprapubically under direct vision. Filshie clips (a single one on each tube) (Figure 1) or Falope rings are the most commonly used methods and are placed on the middle third of the tubes at their smallest diameter to ensure complete occlusion. Diathermy to the tubes is discouraged due to the increased risks of bowel injury (either direct or indirect thermal injury) and ectopic pregnancy. Images of clip or ring placement may be recorded at this stage.

After occlusion, topical local anaesthetic should be applied to the fallopian tubes via the laparoscope to reduce post-operative pain secondary to necrosis of the tube. The ports should then be withdrawn under direct vision, checking for haemostasis and re-checking for injuries. Wounds are then stitched with dissolvable sutures.

If sterilization is performed via mini-laparotomy or at the time of caesarean section, surgical occlusive methods are usually preferred. The Pomeroy technique involves tying the base of a loop of tube and then excising the loop – the ends of the tubes then pull apart as the sutures absorb. This technique can be modified by separating a small section of the tube and ligating the ends.

Recovery from an uncomplicated laparoscopic sterilization is quick and patients should only require normal 'over the counter' analgesia. Women should be advised to have someone with them for the following 24 hours and then can usually return to work after 3–7 days. Written post-operative instructions should be provided. As mentioned above, contraceptive cover should be continued until the next period as ovulation may already have occurred and pregnancy still be a risk.

Female sterilization can fail and the lifetime failure rate of laparoscopic sterilization with Filshie clips is quoted at 1 in 200

(0.5%). The risk of any subsequent pregnancy being ectopic is quoted between 30 and 80% and for this reason, women should be advised to seek medical review for early ultrasound scan if they conceive following sterilization.

Sterilization can fail because of surgical error. Filshie clips can be mistakenly applied to the round ligament rather than the Fallopian tube. Documented evidence of the sterilization with pictures at laparoscopy can prevent legal action if pregnancy should occur following the procedure. Additionally the clips may fall off the tubes, the tubal lumen can re-anastomose or there can be development of an uteroperitoneal fistula that allows fertilization of an egg.

Long term complications following laparoscopic sterilization are rare. Post tubal ligation syndrome (PTLS) – a combination of pain, dysmenorrhoea, menstrual dysfunction, dyspareunia and premenstrual syndrome occurring after sterilization is thought to be related to the cessation of the beneficial effects of other forms of contraception, rather than as a direct result of the procedure. Women under 30 who are sterilized are more likely to have a hysterectomy in the future. However, this probably reflects surgeon and patient preference for definitive surgical treatment should there be menstrual dysfunction, as they are already sterilized.

On a positive note there is some evidence that sterilization may reduce the risk of ovarian cancer 15–20 years in the future. The possible reasons for this include a reduction in exposure of the ovaries to talcum powder, foams and gels which may have carcinogenic properties. Alternatively the incidental inspection of the ovaries at laparoscopy provides an opportunity for intervention at an earlier stage if abnormalities are noted. Recent evidence suggests that the origin of epithelial ovarian cancer may be the distal fallopian tube so removal of the tubes at sterilization may be preferable.

The couple should be provided with comparable information about male sterilization.

Male sterilization has two main advantages over female sterilization. It is usually performed under local anaesthetic in an outpatient setting and the failure rate (1 in 2000) is 10 times lower than female sterilization. As with female sterilization, vasectomy reversal is not usually funded by the NHS.

The two most common surgical techniques for vasectomy are the incisional method and the 'no-scalpel technique'. Local anaesthetic is infiltrated into the scrotum at the start of both procedures. With the no-scalpel technique the vas deferens are identified by palpation midway between the top of the testicle and the base of the penis on the median raphe. They are then encircled using special fixing clamps. The skin is punctured with sharp dissecting forceps, the vas identified and cut or diathermied. Both vas can usually be identified and cut through the same incision. This no-scalpel technique has shorter operating time, fewer complications (see below) and less post-operative discomfort. Conventional vasectomy involves two incisions 1 cm long on each side of the scrotum. A small section of the vas deferens is removed and the ends are closed with ligation or diathermy.

Fascial interposition is sometimes undertaken as part of the procedure where one end of the vas is covered by the sheath tissue of the vas itself and this has been shown to reduce failure rate. Although this creates slightly more surgical difficulty,

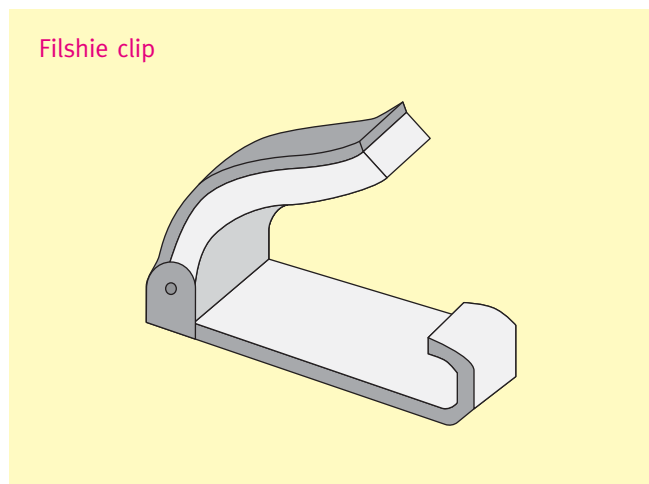


Figure 1

Download English Version:

<https://daneshyari.com/en/article/3966656>

Download Persian Version:

<https://daneshyari.com/article/3966656>

[Daneshyari.com](https://daneshyari.com)