

Assessment of pelvic organ prolapse: a practical guide to the pelvic organ prolapse quantification

Fiona Reid

Abstract

Pelvic organ prolapse (POP) is a common presenting complaint in gynaecology. In the UK, prolapse accounts for 20% of women on the waiting list for major gynaecological surgery. It is therefore important that clinicians understand how to accurately assess women with prolapse. The aim of this article is to provide a comprehensive description of the assessment required. Anatomical assessment should be made using the standardised Pelvic Organ Prolapse quantification system (POP-Q). The use of POP-Q in women with POP allows effective communication between clinicians, reproducible evaluation of surgical outcomes, meaningful comparison of published series and comparison of different populations. The main focus of the article is a detailed and practical explanation of the POP-Q.

Keywords POP-Q; Prolapse evaluation

Introduction

Pelvic organ prolapse (POP) is common, about 10% of women will undergo surgery for prolapse or incontinence at some time in their lives. Appropriate treatment of any condition relies first on accurate diagnosis. Frequently, prolapse has been somewhat crudely diagnosed and treatments were often limited to simple vaginal repairs. Possibly inadequate attention was addressed to vault or uterine descent. The last decade has seen several significant developments within the field of pelvic organ prolapse (POP). Greater understanding of the anatomy of the female pelvic floor has come from magnetic resonance imaging (MRI) and three dimensional ultrasound scanning. Specialist societies, International Urogynaecology Association (IUGA) and the International Continence Society (ICS), have worked together to publish standardised the terminology to assess prolapse. The use of validated questionnaires to assess symptoms and the impact of symptoms has become more common in both research and clinical practice.

Anatomy

The pelvic floor is a highly complex three dimensional structure, the nature of which would challenge the most adept structural engineer. The relative role of connective tissue, muscles and neurovascular tissue in maintaining normal pelvic floor morphology remains controversial.

Fiona Reid MD MRCOG is a Consultant Obstetrician & Gynaecologist at St Mary's Hospital, Central Manchester Foundation Trust, Manchester, UK. Conflicts of interest: none declared.

Some of the anatomy of the pelvic floor is also still controversial; however it is now commonly agreed that the main muscular component of the pelvic floor is made up of levator ani and that levator ani has two component parts (Figure 1). These are the pubovisceral muscle and the iliococcygeal muscle. The pubovisceral muscle is composed of pubococcygeus and puborectalis. Pubococcygeus is made up of several component parts puboanal, puboperineal & pubovaginal muscle. The iliococcygeal muscle arises from a fibrous band on the pelvic sidewall the arcus tendineus levator ani, which runs from the symphysis pubis to the ischial spine over the obturator foramen.

DeLancey describes three levels of support for the pelvic organs. Level 1 support, the upper vagina and uterus, is suspensory and is provided by the uterosacral and cardinal ligaments. Level 2, the mid portion of the vagina is attached to the pelvic sidewall long the "white line" which is the arcus tendineus fascia pelvis. This attachment stretches the vagina between the bladder and rectum. Level 3, the distal vagina is directly attached to surrounding structures, the urethra anteriorly, the perineal body posteriorly and the levator muscles laterally. The three dimensional complexity and the three levels of support are demonstrated in Figure 2.

In 1918 Paramore described the support of the pelvic organs using the simple analogy of a ship in a dock. The ship represents the pelvic organs, the water is the levator muscle and the mooring ropes are the ligaments/fascia. If the water level falls enough the ropes will break.

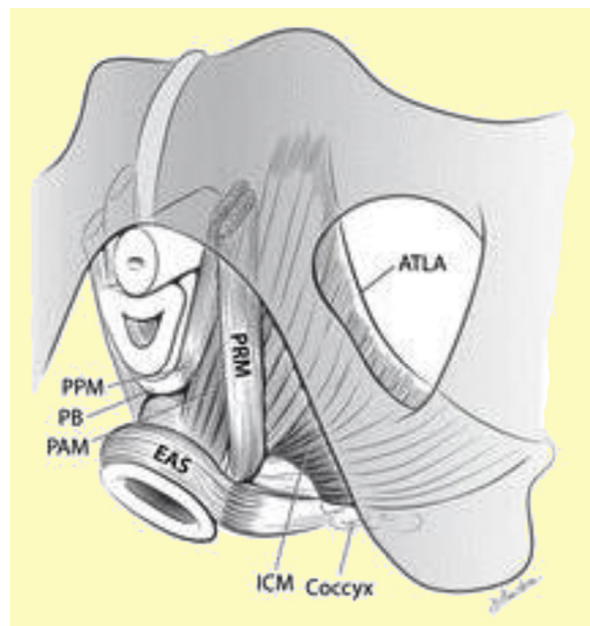


Figure 1 The levator ani muscles from below after the vulvar structures and perineal membrane have been removed showing the arcus tendineus levator ani (ATLA), external anal sphincter (EAS), puboanal muscle (PAM), perineal body (PB) uniting the two ends of the puboperineal muscle (PPM), iliococcygeal muscle (ICM) and puborectalis muscle (PRM). The urethra and vagina have been transected just above the hymenal ring. (Reproduced with permission from: Kearney R, Sawhney R, DeLancey JO. Levator ani muscle anatomy evaluated by origin-insertion pairs. *Obstet Gynecol* 2004; **104**: 168–73).

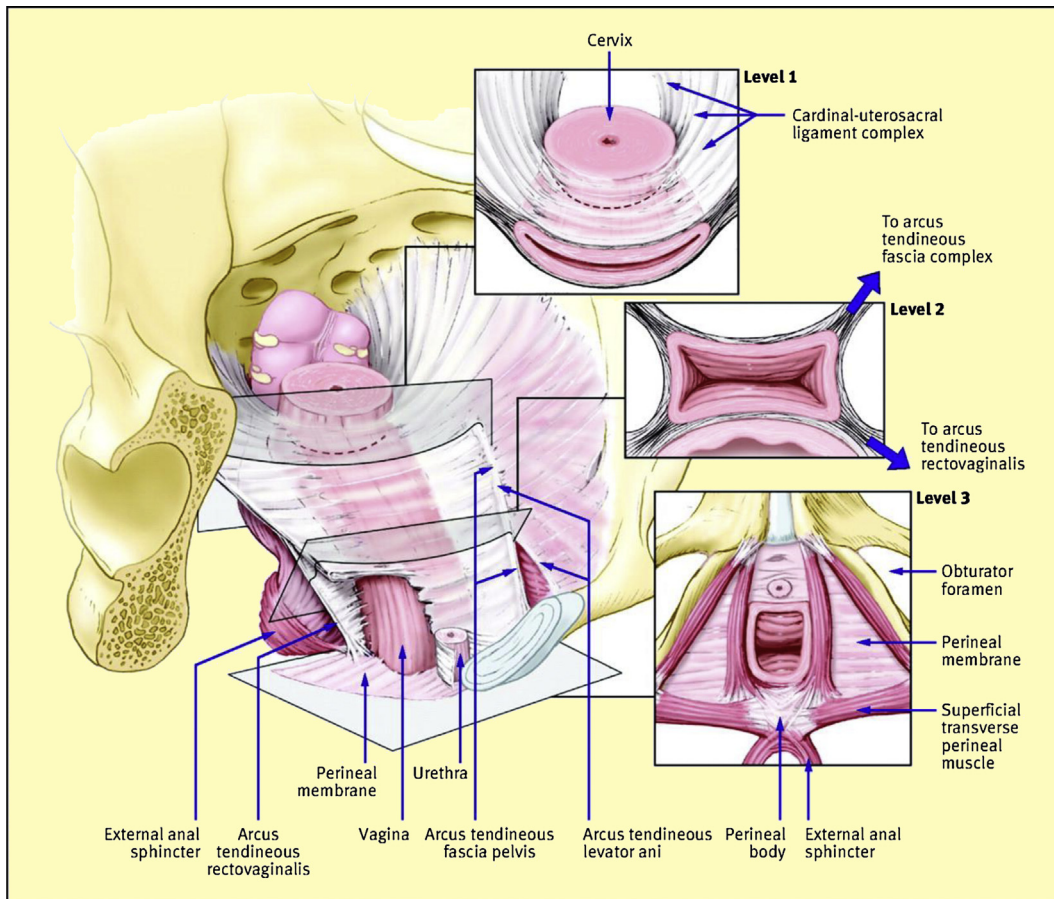


Figure 2 Complex 3D support of pelvic organs. (Reproduced with permission from Barber MD. Contemporary views on female pelvic anatomy. *Cleveland Clin J Med* 2005; **72**(suppl 4): S3–11.).

The use of MRI has allowed the structure of the pelvic floor to be studied in greater detail. However, there are many areas of aetiology of prolapse which are still poorly understood.

Definition of prolapse

Currently there is no adequate definition of prolapse. IUGA & ICS published a joint report on terminology for female pelvic floor dysfunction in 2009. It described prolapse as a departure from

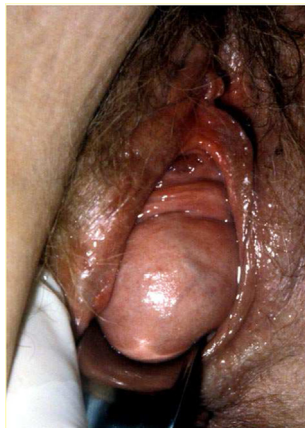

Figure 3 Is this a small cystocele, moderate cystocele, first degree cystocele, second degree cystocele, third degree cystocele or a stage III anterior wall prolapse?

the normal sensation, structure or function, experienced by the woman in reference to the position of her pelvic organs.

The National Institute of Health (NIH) define uterine prolapse as the falling or sliding of the uterus from its normal position in the pelvic cavity into the vaginal canal. Despite very poor evidence about normality the NIH defined prolapse as greater than or equal to Stage 2 on the POP-Q examination. Using this NIH definition studies have shown 40–50% of women have prolapse. This is probably too broad.

Prolapse is a condition which effects women's quality of life, it is not associated with mortality. It is therefore important to consider symptoms in any definition of prolapse. The only symptom which consistently shows good correlation to the presence of anatomical prolapse is that of vaginal bulge.

Consider [Figure 3](#), how would you describe this prolapse to colleague by telephone? Or interpret a colleague's written notes about this prolapse.

Some clinicians use terms such as small, moderate or large cystocele however it is difficult for another clinician to interpret such statements. (One man's small is another man's large!) Some clinicians would describe it as grade II cystocele. Others would state it was a first degree cystocele and some may comment that it is a stage 2 anterior wall prolapse. All of these statements are correct depending on the classification system used ([Figure 4](#)). However prior to the POP-Q, there was no agreed "gold standard" to assess prolapse.

Download English Version:

<https://daneshyari.com/en/article/3966850>

Download Persian Version:

<https://daneshyari.com/article/3966850>

[Daneshyari.com](https://daneshyari.com)