



Contents lists available at ScienceDirect

Taiwanese Journal of Obstetrics & Gynecology

journal homepage: www.tjog-online.com

Case Report

Giant fetal lymphangioma at chest wall and prognosis: Case report and literature review

Donghao Lu ^{a, b}, Yuhe Wang ^a, Weiyue Zeng ^a, Bing Peng ^{a, *}^a Department of Obstetrics and Gynecology, West China Second University Hospital, Sichuan University, Chengdu, China^b Department of Medical Epidemiology & Biostatistics, Karolinska Institutet, Stockholm, Sweden

ARTICLE INFO

Article history:

Accepted 26 December 2013

Keywords:

congenital malformations
genetic counseling
lymphangioma
prenatal diagnosis

ABSTRACT

Objective: To report a rare liveborn case with a giant, septated, chest wall lymphangioma that underwent prenatal expectation treatment.

Case report: A case of giant fetal chest wall cystic lymphangioma was diagnosed prenatally at 19 weeks gestation. Expectation treatment was performed, carefully after prenatal counseling, ruling out other structural abnormalities. At 38 weeks gestation, ultrasound showed a multilocular, subcutaneous cystic mass of 12.3 cm × 9.2 cm × 11.0 cm located on the left chest wall and left upper arm. The tumor was surgically removed 4 days after birth, and no recurrence was observed in the following 18 months.

Conclusion: Our experience suggests that a large, septated fetal lymphangioma may still merit prenatal expectation treatment if there is no evidence for chromosomal and structural abnormality.

Copyright © 2014, Taiwan Association of Obstetrics & Gynecology. Published by Elsevier Taiwan LLC. All rights reserved.

Introduction

Fetal lymphangioma, an uncommon congenital malformation of the lymphatic system, is characterized by a thin-walled cystic dilation most commonly in the posterior neck [1]. It typically develops between late in the first trimester to early in the second trimester. It usually occurs in the neck and axillary region [2]. Moreover, it is highly associated with chromosomal abnormalities and poor outcomes. Nine percent of cases occur in healthy children, while 2% occur in liveborns but with chromosome abnormalities or various malformations [3].

Prenatal diagnosis by sonography and chromosome test provides parents the opportunity to terminate the abnormal fetus. However, for those infertile families who would like to take the risk, it is still worth undergoing expectation treatment if there is no evident risk factor, for example, abnormal karyotype and structural abnormality. Tumor size and septa should not be considered reliable prognostic indicators. We report a rare liveborn case with giant, septated, chest wall lymphangioma that underwent prenatal expectation treatment. The lymphangioma was surgically removed

4 days after birth, and no recurrence was observed in the following 18 months.

Case report

A 31-year-old Chinese prima gravida woman was referred to our department at 19 weeks gestation because a fetal chest wall cyst was detected by a routine scan at the local hospital. Ultrasound examination, performed in our hospital at 19 weeks gestation showed a multilocular, subcutaneous cystic mass measuring 2.9 cm × 3.2 cm × 3.1 cm, located on the left chest wall and left upper arm of the fetus (Fig. 1A). Prenatal screening for Down's syndrome showed it to be low risk in trisomy 21, 18, and 13. After prenatal counseling, the parents refused the amniocentesis, and opted to continue the pregnancy.

The patient underwent left ovarian cyst removal in 2008. After being infertile for 3 years, she opted for *in vitro* fertilization, and received embryo transfer for this pregnancy. The pregnant woman and her husband denied any family history of genetic disorders, tumors, or unusual lymphatic or skin lesions. Prenatal care began at 13 weeks gestation; however, the nuchal translucency measurement was not performed at the local hospital.

Serial sonographic studies every 10–14 days showed appropriate fetal growth, while the volume of cyst gradually increased. The cyst was lucent without internal echoes, but substantial

* Corresponding author. Department of Obstetrics and Gynecology, West China Second University Hospital, Sichuan University, Chengdu 610041, China.

E-mail address: pengbin-a111@163.com (B. Peng).

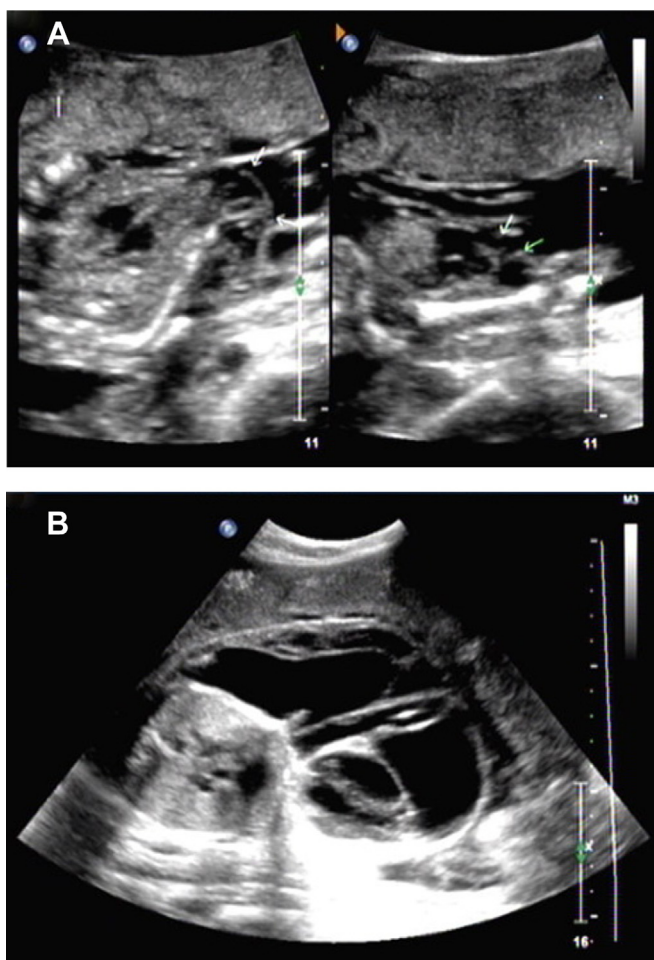


Fig. 1. Ultrasound images. (A) Ultrasound image of the fetus at 19 weeks' gestation. A complex mass measuring 2.9 cm × 3.2 cm × 3.1 cm is seen on the left chest wall and left upper arm. (B) Ultrasound image at 38 weeks' gestation show a giant cystic mass of 12.3 cm × 9.2 cm × 11.0 cm.

intervening solid septations were evident. Color velocity imaging demonstrated no blood flow through the mass. At 38 weeks gestation ultrasound showed the cystic mass had reached 12.3 cm × 9.2 cm × 11.0 cm (Fig. 1B).

With the diagnosis of a giant fetal chest wall lymphangioma, elective cesarean section was performed at 38 weeks gestation, due to concerns about dystocia and fetal trauma. A 2.7-kg male infant was delivered with Apgar scores of 6 and 9 at 1 minute and 5 minutes, respectively. On delivery, the baby had a 14 cm × 9 cm × 9 cm, soft cystic mass in the left anterior chest wall area, which extended to the left upper arm (4 cm × 3 cm × 3 cm; Fig. 2). No other structural anomalies were identified visually. Umbilical cord blood taken at delivery revealed a normal karyotype (46, XY). Chest computed tomography, performed on postnatal Day 1, showed a 14 cm × 8.2 cm × 8.1 cm, well-marginated cystic mass with multiple septation; this was found at the left lateral chest wall and extended to the left upper arm, but not the upper neck (Fig. 3A and B).

The mother's postoperative course was uncomplicated and she was discharged 5 days after the cesarean delivery. At 4 days of age, the infant underwent surgical removal of the giant cystic mass. Pediatric surgeons found the cystic mass (14 cm × 9 cm × 9 cm) covered the left anterior and lateral chest; the cystic mass extended to the left axilla, which enclosed the left branchial plexus and connected with another mass on the left upper arm

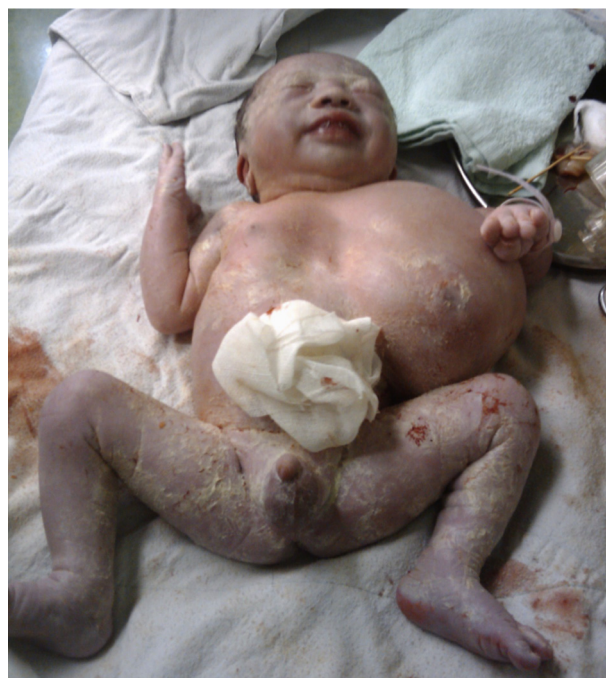

Fig. 2. Images of infant at birth. Image of infant at birth, showing a 14 cm × 9 cm × 9 cm soft cystic mass in the left anterior chest wall area, and extended to left upper arm.

(7 cm × 5 cm × 4 cm). The mediastinum was not involved. Histological studies confirmed the cystic lymphangioma (Fig. 4A and B). Eighteen months of follow-up showed no further abnormalities, and an acceptable appearance.

Discussion

Here, we report a rare case of giant septated fetal lymphangioma on the chest wall. There have been few reported cases of fetal lymphangioma at the chest wall [4]. It is also the largest known mass (14 cm × 9 cm × 9 cm) at the chest wall at live birth.

Fetal lymphangioma, also called cystic hygroma clinically, is characterized by a thin-walled cystic dilation usually around the neck. The defect results from failure of the embryonic lymphatic sacs to connect with the venous system during the development of the lymphatic system [5]. Epidemiological studies have reported the prevalence of fetal lymphangioma to be 1.1–5.3 per 10,000 births, and dependent on maternal age, race, residence, and sex [6,7]. However, if stillbirth and elective terminations are included, the prevalence reaches 30 per 10,000 births, according to a hospital-based study [8]. The growing incidence observed over recent decades is ascribed to the routine use of prenatal ultrasound screening [8].

Prenatal diagnosis is always made by ultrasound during the nuchal translucency test. About 70–80% of cystic hygromas occur in the neck [2], while the remaining 20–30% of the tumors occurs in the axillary region and other rare locations [9]. It is believed that a septated cyst results from complete obstruction of the lymphatic sacs, preventing communication with the jugular venous system and causing large multilocular cysts; while a nonseptated cyst results from temporary accumulation due to incomplete obstruction of lymphatic drainage [10].

Sixty-two percent of cystic hygromas were associated with chromosomal abnormalities [3]. The most common type is Turner syndrome, but other abnormalities include: trisomies 21, 18, and 13

Download English Version:

<https://daneshyari.com/en/article/3974918>

Download Persian Version:

<https://daneshyari.com/article/3974918>

[Daneshyari.com](https://daneshyari.com)