




Contents lists available at ScienceDirect

Taiwanese Journal of Obstetrics & Gynecology

journal homepage: www.tjog-online.com

Original Article

Proposal of a new parameter for diagnosing a low-lying placenta in the third trimester: The distance between the external os and placental edge



Takeshi Nojiri ^{a,1}, Toshiyuki Yoshizato ^{b,*}, Ayako Sanui ^a, Ryota Araki ^a,
Hirotsugu Obama ^b, Kyoko Shirota ^a, Shingo Miyamoto ^a

^a Department of Obstetrics and Gynecology, Faculty of Medicine, Fukuoka University, Fukuoka, Japan

^b Center for Maternal, Fetal and Neonatal Medicine, Fukuoka University Hospital, Fukuoka, Japan

ARTICLE INFO

Article history:

Accepted 28 November 2013

Keywords:

external os
internal os
low-lying placenta
placental edge
ultrasonography

ABSTRACT

Objective: To validate a new parameter of the distance between the external os (EO) and placental edge (PE) to diagnose a low-lying placenta in the third trimester.

Materials and methods: The study participants included 94 uncomplicated singleton pregnant women with cephalic presentation. These women were cared for in our hospital in 1998–2011, with a posterior low-lying placenta, which was diagnosed as the distance between the internal os (IO) and a PE of 0–3.0 cm at 34–36 weeks' gestation. Measurements of cervical length (CL) and the distances of IO–PE and EO–PE were performed using transvaginal ultrasonography at least twice at 28–30 weeks, 31–33 weeks, and 34–36 weeks. Changes in CL, and the IO–PE and EO–PE distances were analyzed.

Results: CL and the IO–PE and EO–PE distances did not change prior to 31–33 weeks. CL was shortened and the IO–PE distance was increased after 31–33 weeks ($p = 0.0001$), but the EO–PE distance was unchanged.

Conclusion: The EO–PE distance is a promising parameter for diagnosis of low-lying placenta in the third trimester up to 36 weeks' gestation.

Copyright © 2015, Taiwan Association of Obstetrics & Gynecology. Published by Elsevier Taiwan LLC. All rights reserved.

Introduction

Low-lying placenta is sonographically diagnosed as the placental edge (PE) and is located within 2–3 cm from the internal os (IO) in the third trimester [1–10]. In such cases, the likelihood of antepartum and/or intrapartum hemorrhage is high, and this requires cesarean delivery. The cases currently diagnosed as low-lying placenta are relatively heterogeneous. In general, the shorter the distance between the IO and PE is, the higher the likelihood of ante- and/or intrapartum hemorrhage. However, the rate of cesarean delivery among cases with a distance between 1 mm and 20 mm has a wide range of 40–90%

[2,5–10]. To improve the prediction of ante- and/or intrapartum hemorrhage, some investigators have proposed new parameters, such as placental migration rate in the third trimester [4,11,12] and the shape of the PE [5] in combination with the distance between the IO and the PE.

The IO, which can be viewed via ultrasonography, is just the distal end of the cervical canal. The cervical length (CL) is affected by various factors, including a distended bladder, dynamic changes in the lower uterine segment produced by localized contractions, and physiological and pathological cervical maturation [1,13]. When the CL is short because of premature labor, the IO moves toward the external os (EO). However, the location of the EO cannot be affected by changes in CL. The location of the PE should logically be determined, not by the distance from the IO, but from the EO instead. However, to date, there is no such definition for the diagnosis of low-lying placenta.

In this study, we describe the age-related changes in the distances between the EO, IO, and PE with advancing gestation in

* Corresponding author. Center for Maternal, Fetal and Neonatal Medicine, Fukuoka University Hospital, 7-45-1 Nanakuma, Jonan-ku, Fukuoka 814-0180, Japan.

E-mail address: ty-obgyn@cis.fukuoka-u.ac.jp (T. Yoshizato).

¹ These two authors contributed equally to this work.

cases of low-lying placenta located on the posterior lower uterine segment in the third trimester of pregnancy. We aimed to validate a new parameter of the distance between the EO and PE for diagnosis of a low-lying placenta.

Patients and methods

The study participants consisted of 94 normal singleton women with low-lying placenta located on the posterior lower uterine segment with cephalic presentation, who were cared for in our hospital between January 1998 and December 2011. All patients underwent cesarean section at 36 weeks' gestation onward. A low-lying placenta was defined as that in which the distance between the IO and the PE was 0–3 cm on an ultrasound measurement at 34–36 weeks' gestation. The patients' characteristics are shown in Table 1. The protocol of this study was approved by the Institutional Review Board of Fukuoka University Hospital, Fukuoka, Japan, and all patients gave informed consent to this study.

Observations of the uterine cervix, lower uterine segment, and placenta were made using ultrasound equipment (model SSD-3500 and Prosound 6; Aloka, Tokyo, Japan) with a curvilinear transvaginal transducer of 7.5 MHz. Scans were performed with women placed in the prone position with an empty bladder. Once the cervical canal was clearly visualized, the EO, IO, and placenta were identified. The PE was determined as the outer edge of the marginal sinus when visualized. CL and the distance between the IO to PE (IO–PE distance) were measured along the curvature of the cervical canal and the lower uterine segment (Figure 1). The mean of three measurements was used to calculate each distance in millimeters. The distance between the EO and PE (EO–PE distance) was calculated by the addition of CL and the IO–PE distance. In each case, ultrasound measurements were performed starting at 28–30 weeks or later until 36 weeks at every 3-week interval. In 52 cases, measurements were made at 28–30 weeks, 31–33 weeks, and 34–36 weeks. In an additional 42 cases, measurements were made at 31–33 weeks and 34–36 weeks. Therefore, there was a total of 94 cases in which measurements were made at 31–33 weeks and 34–36 weeks. Changes in CL, and the IO–PE and EO–PE distances from 28–30 weeks to 31–33 weeks and from 31–33 weeks to 34–36 weeks, were analyzed. The rate of change in CL, and the IO–PE and EO–PE distances between two consecutive age groups were calculated by dividing the distance between two measurements by the number of weeks of the corresponding two scans. Statistical analysis was performed using the Wilcoxon *U* test. Statistical significance was set at $p < 0.05$.

Results

The CLs at 28–30 weeks, 31–33 weeks, and 34–36 weeks were 41.8 ± 8.7 mm, 40.8 ± 8.0 mm, and 37.1 ± 8.3 mm, respectively. There was no change in CL between 28–30 weeks and 31–33

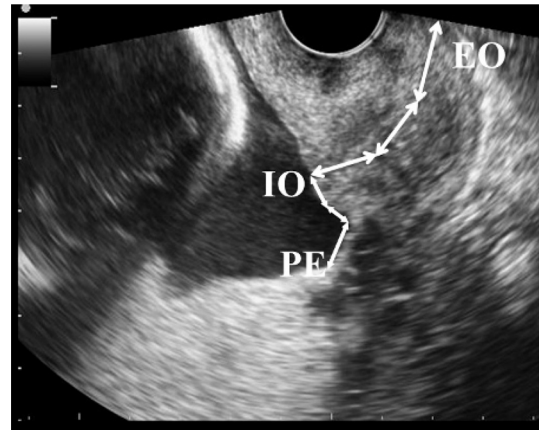


Figure 1. Measurements of cervical length and the distances between the internal os (IO) and placental edge (PE). EO = external os.

weeks, but it became shorter between 31–33 weeks and 34–36 weeks ($p = 0.0001$), with a rate of -1.2 ± 2.2 mm/wk (Figures 2 and 3). The IO–PE distance at 28–30 weeks, 31–33 weeks, and 34–36 weeks was 13.1 ± 8.1 mm, 13.3 ± 7.6 mm, and 17.3 ± 6.8 mm, respectively. The IO–PE distance did not change between 28–30 weeks and 31–33 weeks, but it became longer between 31–33 weeks and 34–36 weeks ($p = 0.0001$), with a rate of $+1.2 \pm 1.9$ mm/wk. The EO–PE distance at 28–30 weeks, 31–33 weeks, and 34–36 weeks was 54.9 ± 11.7 mm, 54.1 ± 10.0 mm, and 54.4 ± 10.0 mm, respectively. The EO–PE distance did not change between 28–30 weeks and 31–33 weeks or between 31–33 weeks and 34–36 weeks.

Discussion

The current study found that CL did not change prior to 31–33 weeks but shortened thereafter in the third trimester. This represents the physiological process of cervical maturation, which occurs in the mid third trimester [14]. By contrast, the IO–PE distance did not change prior to 31–33 weeks but lengthened thereafter. This phenomenon is generally recognized as placental migration, which is accelerated in the late third trimester. The mean placental migration rate at 31–33 weeks and 34–36 weeks was $+1.2$ mm/wk in our study, which is consistent with other reports [2,7,8]. Placental migration observed mostly in the second trimester is hypothesized to be caused by “dynamic placentation” and/or “placental wandering.” The former process is the result of apoptosis of the lower PE, and the latter is attributable to differences in the blood supply from the uterine vasculature to the PE [15,16]. The EO–PE distance did not change throughout the observation period in the third trimester, indicating that placental migration observed in our study was mainly a result of “migration” of the IO toward the EO caused by the physiological shortening of CL.

There are various possible factors related to the IO–PE distance and CL. To standardize such factors as much as possible, first, the data were limited to ≤ 36 weeks' gestation. This is because the fetal presenting part has already descended in most cases at term, which may compress the posterior lower uterine segment, possibly leading to extension of the IO–PE distance. Second, we excluded cases with noncephalic presentation because compression of the fetal presenting part to the posterior lower uterine segment should be standardized as much as possible. Third, measurements were performed while the

Table 1

Patient characteristics of 94 women with a low-lying placenta.

Maternal age (y)	32 (19–42)
Parity	0 (0–4)
Previous cesarean section	5 (5.3)
Antepartum hemorrhage	15 (15.9)
Gestational age at delivery (wk)	37 (36–38)
Emergency cesarean section	7 (7.4)
Blood loss at cesarean section (g)	950 (290–3385)
Neonatal birth weight (g)	2753 (2077–3495)

Data are presented as *n* (%) or median (range).

Download English Version:

<https://daneshyari.com/en/article/3975054>

Download Persian Version:

<https://daneshyari.com/article/3975054>

[Daneshyari.com](https://daneshyari.com)