

Contents lists available at [ScienceDirect](http://www.sciencedirect.com)

# Taiwanese Journal of Obstetrics & Gynecology

journal homepage: [www.tjog-online.com](http://www.tjog-online.com)

## Short Communication

### Recurrent fetal syndromic spina bifida associated with 3q26.1-qter duplication and 5p13.33-pter deletion due to familial balanced rearrangement



Egle Preiksaitiene\*, Eglė Benušienė, Zivile Ciuladaite, Vytautas Šliužas, Violeta Mikštienė, Vaidutis Kučinskas

Department of Human and Medical Genetics, Faculty of Medicine, Vilnius University, Vilnius, Lithuania

#### ARTICLE INFO

##### Article history:

Accepted 14 October 2014

##### Keywords:

neural tube defects  
3q26.1-qter duplication  
5p13.33-pter deletion

#### ABSTRACT

**Objective:** Neural tube defects belong to the second most common group of congenital anomalies, after heart defects, which can be diagnosed by prenatal ultrasonography. Rarely, neural tube defects can be associated with chromosomal abnormalities, including full and partial aneuploidies. We report a familial fetal case with syndromic spina bifida and discuss its association with partial 3q duplication and partial 5p deletion.

**Materials and methods:** Clinical findings of three affected family members in two generations and two carriers of the balanced translocation are described. Conventional cytogenetic and fluorescence *in situ* hybridization (FISH) analysis of the carrier, as well as subtelomeric multiplex ligation-dependent probe amplification (MLPA) and array comparative genomic hybridization (CGH) analysis on the DNA extracted from affected family members was performed.

**Results:** Subtelomeric FISH analysis of the proposita revealed balanced reciprocal translocation between the long arm of chromosome 3 and short arm of chromosome 5. Subtelomeric MLPA screening of the first child revealed the deletion in 5p15.33 and duplication in 3q29 chromosomal loci, the finding consisting of the unbalanced rearrangement involving the short arm of chromosome 5 and long arm of chromosome 3. Array CGH analysis of the DNA of the second affected child revealed a 31.1Mb duplication of 3q26.1-qter and a 33.6Mb deletion of 5p13.33-pter.

**Conclusion:** Our report serves to emphasize the consistency in the prenatal sonographic feature of spina bifida in consecutive pregnancies with fetuses associated with partial trisomy 3q (3q26.1-qter) and partial monosomy 5p (5p13.33-pter). The use of molecular cytogenetic technologies such as array CGH and FISH is important for clarifying any type of unbalanced chromosome rearrangement.

Copyright © 2016, Taiwan Association of Obstetrics & Gynecology. Published by Elsevier Taiwan LLC. This is an open access article under the CC BY-NC-ND license (<http://creativecommons.org/licenses/by-nc-nd/4.0/>).

## Introduction

Neural tube defects affect 0.5–2 per 1000 established pregnancies worldwide [1] and are the second most common group of congenital anomalies, after heart defects, that can be diagnosed by prenatal ultrasonography. One of the most common types of neural tube defects is spina bifida, which is caused by the failure of the spinal part of the neural tube to close. In a majority of cases, this defect is isolated and is not associated with other congenital malformations. Syndromic cases of neural tube defects also exist, representing ~10% of all defects [2]. Sporadic cases of neural tube defects are usually observed,

and familial cases are rare [3]. The inheritance is consistent with a multifactorial polygenic or oligogenic pattern. Rarely, neural tube defects can be associated with chromosomal abnormalities, including full and partial aneuploidies [4,5].

Here, we report a familial fetal case with syndromic spina bifida and unbalanced translocation between the long arm of chromosome 3 and short arm of chromosome 5, resulting in 3q26.1-qter duplication and 5p13.33-pter deletion.

## Materials and methods

### Clinical report

Clinical findings of three affected family members (II:2, III:1, III:2) in two generations and two carriers of the balanced

\* Corresponding author. Department of Human and Medical Genetics, Faculty of Medicine, Vilnius University, Santariškių st. 2, LT-08661 Vilnius, Lithuania.

E-mail address: [egle.preiksaitiene@mf.vu.lt](mailto:egle.preiksaitiene@mf.vu.lt) (E. Preiksaitiene).

translocation (II:4, II:6) are described below. A partial genealogy of the family is shown in Figure 1.

**Proposita (II:4).** A 27-year-old woman was referred for genetic counselling after having a newborn (III:1) with severe congenital abnormalities and a stillborn (III:2) with similar clinical features, as well as a family history of an inherited condition. According to her personal history, her psychomotor development was normal. In infancy she had experienced myocarditis. Myopia appeared at the age of 25 years. On examination at 27 years of age, her height was 160 cm, her weight was 90 kg, and no facial dysmorphic features were observed.

**The first child (III:1).** During the proposita's pregnancy with the first child, no exposure to teratogenic agents (i.e., gestational diabetes, ethanol abuse, smoking, illicit drugs, or medication) was recorded. Serologic tests for cytomegalovirus, toxoplasmosis, and rubella were negative. The proposita denied experiencing any fever or cold symptoms. Polyhydramnios and hypotrophy of the fetus was diagnosed at 18 weeks of gestation. Due to the condition of the fetus and maternal hypertension, a Caesarean section was performed at 34 weeks of gestation, and a boy was delivered weighing 1790 g (10–25 centiles), with a length of 36 cm (<3 centile), head circumference of 29 cm (3–10 centiles), and Apgar scores of 7 and 8. Signs of prematurity and hypotonia were observed from birth. His phenotype (Figure 2A and B) was characterized by brachycephaly, epicanthus, upward slant of palpebral fissures, hypertelorism, long philtrum, anteverted nares, down-turned mouth, high palate, micrognathia, long thumbs, dysplastic feet, three to four toe syndactyly, micropenis, and a hairy patch in the lumbosacral region. Other clinical findings were revealed by clinical investigation: a screening test of hearing was negative; neurosonography showed ventriculomegaly; an echocardiogram identified a large ventricular septal defect, secondary atrial septal defect, patent foramen ovale, and patent ductus arteriosus; and epileptic activity in the right frontal lobe with generalization was recorded in an electroencephalogram. Ophthalmological investigation showed

dysplasia of the optic nerve. The newborn died at the age of 1 month due to cardiopulmonary insufficiency.

**The second child (III:2).** The second pregnancy of the proposita was uneventful until 25 weeks, when polyhydramnios and dysplastic features of the fetus were detected. A fetal ultrasound examination showed a male fetus with brachycephaly, micrognathia, suspicion of tetralogy of Fallot, clubfoot, spina bifida, and polyhydramnios. Comprehensive ultrasound scans were performed repeatedly and additionally revealed short femur length, encephalocele, mild microcephaly, a specific shape of the head, banana sign of cerebellum (hypoplastic), myelomeningocele in the lumbosacral region, micropenis, and dysmorphic facial features, including micrognathia and a wide forehead (Figure 2C and D). Fetal death in the uterus occurred at 31 weeks of gestation. On foetopathological examination, pulmonary atresia, transposition of the great vessels, horseshoe kidney, hypoplasia of the cerebellum, hydrocephalus, spina bifida aperta in the lumbosacral region, clubfoot, micropenis, and prematurity were noted (Figure 2E and F). Dysmorphic features were a wide forehead, hypertelorism, a nasal groove, a broad nose, low set and dysplastic ears, and long thumbs.

**Proposita's sibling (II:2).** The fetus of the proposita's mother died in the uterus at 26 weeks of gestation. The stillborn was a female and had open spina bifida.

**Proposita's brother (II:6).** The infant was delivered normally after an uncomplicated full-term pregnancy. Severe arthrogryposis was noted from birth. Congenital dysplasia coxae was treated in infancy. Deformities of the feet were surgically corrected in childhood. His intelligence is normal.

#### Conventional and molecular cytogenetic analysis

##### Conventional cytogenetic analysis

Chromosomal analysis of the proposita was performed from cultivated peripheral blood lymphocytes using the conventional G-banding technique. Cytogenetic analysis was performed from GTG-banded metaphases at 400–550 band resolution.

##### Fluorescence in situ hybridization

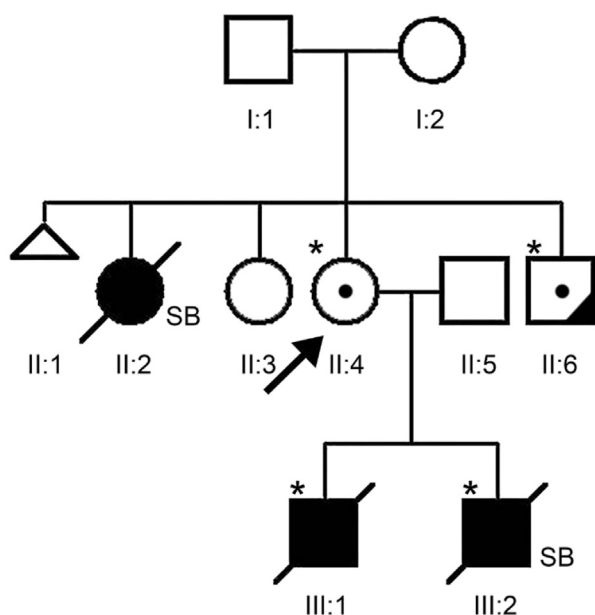
Fluorescence in situ hybridization (FISH) analysis was performed on metaphases prepared from peripheral blood lymphocytes obtained by standard protocols. FISH analysis was carried out using subtelomeric probes (Abbott Laboratories, Abbott Park, IL, USA). All FISH procedures were performed according to the manufacturer's recommendations. Fluorescent signals were analyzed using a Nikon 80i fluorescent microscope with CytoVision version 3.6 (Applied Imaging, New Milton, UK).

##### Multiplex ligation-dependent probe amplification

Subtelomeric multiplex ligation-dependent probe amplification (MLPA) screening was performed on the first child's DNA extracted from dried blood spot (Guthrie card) with an InstaGene Matrix kit (Bio-Rad Laboratories, Hercules, CA, USA) according to the manufacturer's directions and diluted in Tris-EDTA buffer to a concentration of 20 ng/μl. MLPA testing was carried out using SALSA MLPA P036 Subtelomeres Mix1 vE2 kit (MRC-Holland, Amsterdam, The Netherlands) according to the manufacturer's recommendations. Capillary electrophoresis was performed with a 3130xL Genetic Analyzer (Applied Biosystems, Warrington, UK). Fluorescent signals were analyzed with GeneMapper version 3.7 software (Applied Biosystems, Warrington, UK).

##### Array comparative genomic hybridization

Array comparative genomic hybridization (CGH) analysis was performed to specify the position and the size of the chromosomal



**Figure 1.** Genealogy of the family. The affected family members (with open spina bifida or suspected spina bifida occulta) are shown in black symbols. The proposita is indicated by the arrow. Her brother, (II:6) has congenital severe arthrogryposis. Carriers of the translocation are indicated with a dot. Asterisks indicate individuals that could be tested. SB = stillborn.

Download English Version:

<https://daneshyari.com/en/article/3975170>

Download Persian Version:

<https://daneshyari.com/article/3975170>

[Daneshyari.com](https://daneshyari.com)