

Teaching Case

Grade 3 radiation dermatitis in a patient with presumed latent actinic lichen planus

Scott R. Silva MD PhD, Bahman Emami MD*

Department of Radiation Oncology, Loyola University, Maywood, Illinois

Received 21 March 2016; received in revised form 11 June 2016; accepted 15 June 2016

Introduction

Radiation-induced skin injury ranges from acute dermatitis to chronic skin changes.^{1,2} Acute skin injury occurs during the course of radiation treatment and may take 1 to 3 months after the completion of radiation therapy to completely heal. Patients with mild acute dermatitis present with mild erythema, dry desquamation, pruritus, hyperpigmentation, and hair loss. Severe acute dermatitis is characterized by confluent moist desquamation, ulcers, hemorrhage, and necrosis.^{1,3} Chronic radiation-induced skin injury includes chronic fibrosis with associated skin breakdown and infection.^{1,4}

The severity of radiation-induced skin toxicity depends on radiation factors (dose, fractionation, volume, and surface area) and patient-specific factors. Excessive skinfolds increase radiation-induced skin toxicity. Also, patients with poor nutrition status or a preexisting vascular condition or connective tissue disease have impaired wound healing and are at increased risk of skin toxicity.⁵ Actinic lichen planus is an autoimmune skin disease characterized by a violaceous papule rash.⁶ Here, we report the case of a patient with presumed latent actinic lichen planus treated with definitive radiation therapy who subsequently developed overt lichen planus and severe radiation dermatitis in the treatment fields.

Case report

A 55-year-old African American woman presented with intermittent hoarseness over several years, eventually limiting her voice to a whisper. She denied dysphagia, odynophagia, otalgia, dyspnea, or stridor. Suspension microlaryngoscopy revealed a bulky left vocal cord lesion. Bilateral vocal fold biopsies were obtained, and pathology revealed a superficially invasive, well-differentiated squamous cell carcinoma of the left true vocal cord without invasion of the right true vocal cord. She was staged as cT1bN0M0.

The patient was treated with definitive radiation therapy to the larynx and received a total dose of 62 Gy in 31 fractions of 2 Gy each delivered once daily using 6-MV photons, per our departmental policy. The total treatment duration was 50 days, including breaks and weekends. After she received 14 Gy, she had a treatment break of 10 days because she was hospitalized at an outside facility for a gastrointestinal bleed. She then completed treatment as planned. Right and left posterior oblique fields were used, with gantry angles of 260° and 100°, respectively. Thirty-degree wedges were used to reduce anterior hotspots. The field sizes were 5.7 cm superior to inferior and 4.6 cm anterior to posterior. No bolus was used throughout the course of radiation therapy. The dosimetry is shown in Fig 1.

During treatment she experienced grade 3 radiation dermatitis, grade 1 hoarseness, and grade 2 pharyngeal mucositis. Table 1 lists the toxicity grades for radiation dermatitis. Her skin toxicity became most severe after receiving 52 Gy. The radiation plan was reviewed, and optically stimulated luminescent dosimeters were used to

Conflicts of interest: None.

* Corresponding author. Department of Radiation Oncology, Stritch School of Medicine Loyola University, 2160 South 1st Ave., Maguire Center, Maywood, IL 60153

E-mail address: bemami@lumc.edu (B. Emami)

<http://dx.doi.org/10.1016/j.adro.2016.06.001>

2452-1094/Copyright © 2016 the Authors. Published by Elsevier Inc. on behalf of the American Society for Radiation Oncology. This is an open access article under the CC BY-NC-ND license (<http://creativecommons.org/licenses/by-nc-nd/4.0/>).

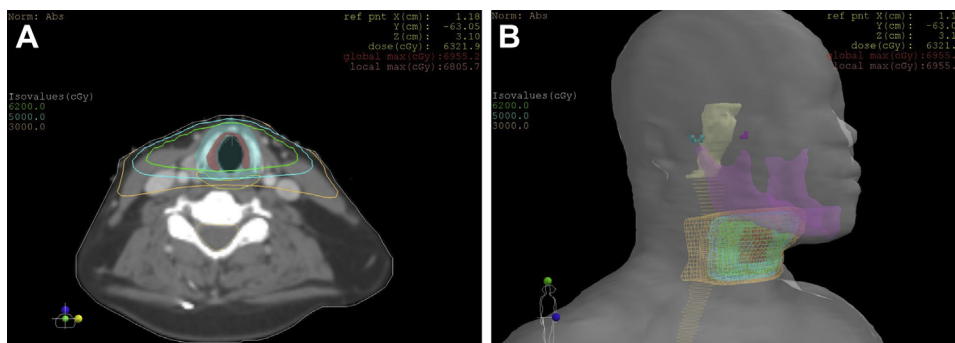


Figure 1 Dosimetry. (A) Representative axial sections showing isodose lines. Green = 62 Gy, cyan = 50 Gy, orange = 30 Gy. (B) Three-dimensional rendering of isodose lines. Mandible is purple, spinal cord is light orange, and brain stem is yellow.

verify that the skin dose did not exceed 2.0 Gy per fraction. She was prescribed silver sulfadiazine 1% for management of her dermatitis and hydrocodone with acetaminophen 7.5 to 500 mg/15 mL oral solution for pain control; however, the radiation dermatitis persisted through the end of treatment. On her final day of treatment, she had developed skin hyperpigmentation in the anterior neck, including the superior border of nodal station 2 through the inferior border of nodal station 3. She developed moist desquamation in the areas where the oblique fields entered through the skin, correlating with the 50-Gy isodose line. Our patient's dermatitis healed after 2 months, as depicted in Fig 2.

One month after our patient completed radiation therapy, she presented to dermatology and was noted to have gray to violaceous patches in the buccal mucosa and tongue. She also had many scattered flat-topped hyperpigmented to violaceous patches in the extremities and

buttocks. She reported an intermittent pruritic rash of the arms, legs, and trunk for the previous 10 years. She was using triamcinolone cream and hydroxyzine with minimal improvement in this rash. A shave biopsy was obtained from a representative lesion in the right volar forearm. Pathology showed patchy interface dermatitis with pigment incontinence, compact orthokeratosis with hypergranulosis, focal basal layer squamatization, and occasional apoptotic keratinocytes limited to the lower portion of the epidermis. Based on the clinical and histological findings, she was diagnosed with actinic lichen planus.

Discussion

Actinic lichen planus is an inflammatory skin reaction thought to be caused by an autoimmune reaction that typically develops on sun-exposed areas in dark-skinned individuals. Only 7 cases of radiation-induced cutaneous lichen planus have been reported, shown in Table 2.⁷⁻¹³ However, no report to our knowledge discusses radiation-induced skin toxicity in a patient with lichen planus. The case presented here is the first case of severe radiation dermatitis in the treatment field of a patient with presumed occult actinic lichen planus.

At our institution, T1 glottis squamous cell carcinomas are treated with doses of 60 to 66 Gy in fractions of 2 Gy, with a local control exceeding 90% (unpublished data). The generally accepted radiation treatment for T1 glottic cancers is a hypofractionated course of 63 Gy in 2.25 Gy per fraction based on the study by Yamazaki et al that showed improved local control in the hypofractionation arm versus the conventional fractionation arm (60-66 Gy in 2 Gy per fraction).¹⁴ However, in the aforementioned study, local control in the conventional fractionation arm was only 77% at 5 years.¹⁴ Previous studies have shown the 5-year local control of T1 squamous cell carcinomas of the glottis treated with conventional fractionation to be 88%¹⁵; therefore, we have adopted a conventional fractionation treatment regimen in the management of T1 squamous cell carcinomas of the glottis.

Table 1 Toxicity grades for radiation dermatitis, defined as a finding of cutaneous inflammatory reaction occurring as a result of exposure to biologically effective levels of ionizing radiation

Radiation dermatitis grade	
1	Faint erythema or dry desquamation
2	Moderate to brisk erythema; patchy moist desquamation, mostly confined to skin folds and creases; moderate edema
3	Moist desquamation in areas other than skin folds and creases; bleeding induced by minor trauma or abrasion
4	Life-threatening consequences; skin necrosis or ulceration of full thickness dermis; spontaneous bleeding from involved site; skin graft indicated
5	Death

Adapted from Common Terminology Criteria for Adverse Events (CTCAE) version 4.03, June 14, 2010, U.S. Department of Health and Human Services.

Download English Version:

<https://daneshyari.com/en/article/3976383>

Download Persian Version:

<https://daneshyari.com/article/3976383>

[Daneshyari.com](https://daneshyari.com)