



Case report

Ipsilateral supraorbital nerve transfer in a case of recalcitrant neurotrophic keratopathy with an intact ipsilateral frontal nerve: A novel surgical technique



Frances Jacinto ^a, Edgar Espana ^{a,b}, Maximilian Padilla ^a, Amier Ahmad ^c, Ilya Leyngold ^{d,*}

^a Department of Ophthalmology, University of South Florida Eye Institute, 13127 Magnolia Drive, Tampa, FL 33612, United States

^b Department of Molecular Pharmacology & Physiology, University of South Florida Morsani College of Medicine, 12901 Bruce B Downs Blvd, MDC 8, Tampa, FL 33612, United States

^c Morsani College of Medicine, University of South Florida, 12901 Bruce B Downs Blvd, Tampa, FL 33612, United States

^d Duke University, Department of Ophthalmology, 3475 Erwin Road, Durham, NC 27705, United States

ARTICLE INFO

Article history:

Received 28 March 2016

Received in revised form

27 June 2016

Accepted 14 July 2016

Available online 18 July 2016

Keywords:

Neurotrophic keratopathy

Cornea

Corneal neurotization

Long ciliary nerves

Corneal anesthesia

ABSTRACT

Purpose: To report a case of regained corneal sensation and function in a patient with neurotrophic keratopathy due to direct damage to the long ciliary nerves by performing a corneal neurotization procedure using ipsilateral supraorbital nerve. Surgical technique is described in detail as well as a review of the literature on corneal neurotization.

Observations: A patient with devastating corneal anesthesia and poor visual acuity refractory to other treatments underwent a new surgical technique involving an ipsilateral supraorbital nerve transfer to the surrounding limbus to restore corneal sensation. At 8 months follow up, there was resolution of corneal stromal opacification documented with photographs and greatly improved corneal sensation by testing with a wisp of cotton in all 4 quadrants. Her visual acuity had improved, and at two years she was stable with even more improvement in visual acuity and ocular surface health.

Conclusions and importance: We present the first successful case of corneal neurotization with ipsilateral supraorbital nerve in a patient with corneal anesthesia from a local injury to the long ciliary nerves. Our case demonstrates that the described method of corneal neurotization is a viable option for patients with recalcitrant neurotrophic keratopathy and an intact ipsilateral frontal nerve.

© 2016 Published by Elsevier Inc. This is an open access article under the CC BY-NC-ND license (<http://creativecommons.org/licenses/by-nc-nd/4.0/>).

1. Introduction

Normal sensation of the cornea is provided by innervation from the ophthalmic division of the trigeminal nerve, and is required for initiating the blink reflex, preserving epithelial integrity, and maintaining limbal stem cell function [1,2]. Failure to provide adequate sensation is termed corneal anesthesia, which can be subdivided into acquired or congenital causes. Congenital corneal anesthesia is extremely rare, with acquired forms most commonly resulting from infection, inflammatory processes, trauma, neoplasia, or iatrogenic disease [3].

The insensate cornea results in a clinical condition known as neurotrophic keratopathy (NK), also referred to as neurotrophic keratitis. NK is a degenerative disease of the cornea caused by an impairment of corneal sensory innervation, characterized by decreased or absent corneal sensitivity resulting in epithelial keratopathy, ulceration, and perforation [1,3]. Treatment options are limited, with many treatment modalities failing to preserve vision and leading to recalcitrant progression.

Neurotization is the process of transferring a healthy donor nerve segment to a tissue to re-establish either motor or sensory innervation [4]. There are few reports on corneal neurotization in literature performed on patients with anesthetic corneas secondary to intracranial pathology [4–7]. Previous reports described contralateral supraorbital or supratrochlear nerve transfers to the cornea or re-innervation using sural nerve grafts anastomosed to

* Corresponding author.

E-mail address: ileyngo1@gmail.com (I. Leyngold).

supratrochlear nerve in patients with concurrent trigeminal and facial nerve palsies or congenital corneal anesthesia [4–7].

2. Case report

A 61-year-old healthy female was referred to our Oculoplastic Surgery service for evaluation of burning and irritation in her left eye that was unresponsive to conservative management. Her ocular symptoms began following retinal detachment surgery in the left eye involving an encircling scleral buckle, dense peripheral retina endolaser, and pars plana vitrectomy 6 months prior to presentation to our service. She also underwent an uncomplicated phacoemulsification with insertion of posterior chamber intraocular lens surgery 3 months prior to her evaluation by our service. Her cataract surgery was followed by a tapering course of non-steroidal anti-inflammatory and antibiotic drops over a month. Patient reported worsening of her symptoms following cataract extraction. The patient provided written consent for publication of personal information including medical record details and photographs.

On presentation, her best-corrected visual acuity (BCVA) in the left eye was 20/200. She had absent corneal sensation and blink in all four quadrants by testing with a wisp of cotton. On examination, she had anterior stromal opacification, inferior neovascularization, and an epithelial defect (Fig. 1). Her dilated fundus examination was notable for a flat macula with dense peripheral laser scars outside of the vascular arcades. Her external exam was notable for a medial canthal tendon dystopia due to a childhood injury and intact sensation to light touch over her scalp.

To maintain corneal integrity, the patient underwent lateral tarsorrhaphy and placement of a gold weight in her upper eyelid. She improved postoperatively, with complete healing of the corneal epithelial defect, but with persistent stromal scarring. Her visual acuity continued to worsen to count fingers at one foot. After exhausting most known treatment options, it was decided to proceed with the corneal neurotization procedure.

The surgical technique is a variant of previously reported corneal neurotization procedures and will be described in detail in the following paragraphs.

The procedure began by making a hemicoronal incision just behind the hairline from mid-line to the auricular helix. Sharp and blunt dissection was carried out in the subgaleal plane and laterally over the deep temporal fascia. Dissection was carried inferiorly to release the temporal line of fusion, and then continued until 2 cm above the superior orbital rim. At this level the periosteum was incised, and subperiosteal dissection carried to the superior orbital rim. The dissection of the deep branch of the supraorbital nerve

was then carried cephalad from the supraorbital notch. Three branches of the nerve were isolated and severed 6 cm from the supraorbital notch (Fig. 2a).

An upper eyelid incision was made and the nerve fibers were tunneled into the palpebral incision (Fig. 2b). A blepharotomy medial to the medial horn of the levator aponeurosis was then performed. The nerves were further tunneled through the blepharotomy incision into the superior conjunctival fornix.

A conjunctival incision was made at the 12 o'clock 7 mm above the corneal scleral limbus, and a blunt abdominal needle was used to access the space under Tenon's capsule. The branches of the nerves were placed in the sub-Tenon's space 360° around the limbus. The conjunctiva was then closed to completely cover the nerves. An amniotic membrane graft was then sutured to the surface of the eye with interrupted 8-0 polyglactin suture. No complications were noted during the procedure or during her post-operative recovery period.

At eight months follow up, patient's BCVA improved to 20/100 with resolution of corneal stromal opacification and greatly improved corneal sensation by testing with a wisp of cotton in all 4 quadrants (Fig. 3). Her scalp sensation was completely restored. She had no evidence of synkinesis. No complications were noted during her post-operative recovery. Given the significant improvement in her ocular surface her tarsorrhaphy was severed and gold weight was removed. At a two-year follow-up, the patient reported continued ocular comfort and improved vision. Her BCVA improved to 20/30, and slit lamp examination showed a clear and well-lubricated cornea. No epithelial staining was noted with lissamine green or fluorescein. There was persistence of an intact corneal sensation. A very noticeable finding was the presence of an induced blink with corneal contact by a wisp of cotton (Fig. 4).

3. Discussion

The insensate cornea represents a difficult diagnosis to treat, with various treatments giving patients only temporary relief and eventually leading to poor outcomes. Additionally, the current surgical techniques for NK focus on protecting the cornea, and have minimal to no effect on improving corneal sensation [3].

Corneal neurotization is a novel approach to obtain a definitive treatment for the condition. The first report of corneal neurotization in literature was described in 2009 by Terzis et al. [6], where six patients with unilateral facial and trigeminal palsies underwent direct neurotization of the cornea using the contralateral supraorbital and supratrochlear branches of the ophthalmic division of the trigeminal nerve, with the average time to reestablish corneal

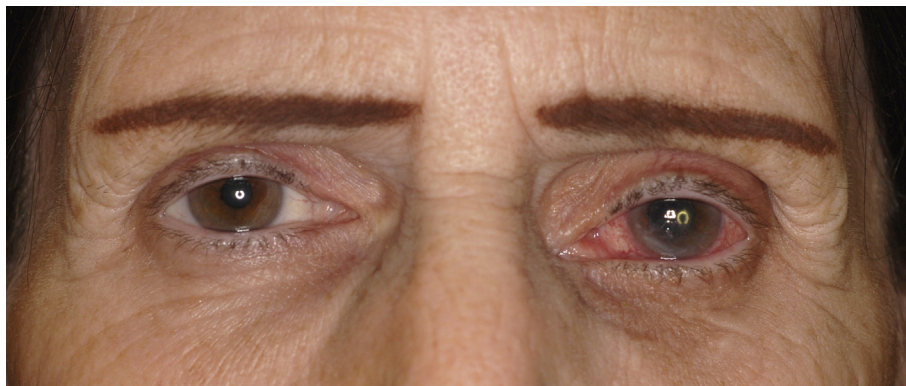


Fig. 1. Pre-operative photograph at initial presentation showing conjunctival injection, corneal opacification, and peripheral neovascularization in the left eye with best-corrected visual acuity (BCVA) of 20/200 at this visit.

Download English Version:

<https://daneshyari.com/en/article/4006532>

Download Persian Version:

<https://daneshyari.com/article/4006532>

[Daneshyari.com](https://daneshyari.com)